




Immunohistochemistry of *KRAS* Protein in Colorectal Cancer

Dody Novrial¹^a, Kamal Agung Wijayana²^b and Hanif Kun Cahyani²^c

¹Department of Anatomical Pathology, Faculty of Medicine, Universitas Jenderal Soedirman, Purwokerto, Indonesia

²Department of Surgery, Faculty of Medicine, Universitas Jenderal Soedirman Purwokerto, Indonesia

³Faculty of Medicine, Universitas Jenderal Soedirman Purwokerto, Indonesia

Keywords: Ras gene aberration, *KRAS* mutation, Colorectal cancer.

Abstract: PCR assays are used for the detection of *KRAS* mutations in colorectal cancer (CRC). However, there are some disadvantages in the clinical application such as the high-cost value and specific codon properties of this method. Our study aimed to evaluate the effectivity of immunohistochemistry (IHC) in assessing ras gene aberration in CRC before PCR testing. Paraffin-embedded tissue samples from 45 CRC patients were stained immunohistochemically using anti-*KRAS* protein polyclonal antibody. *KRAS* protein expression was assessed and correlated with clinicopathological features. A chi-square test was performed to evaluate the results statistically. *KRAS* protein positivity was observed in 31.1% of cases. The positivity was correlated with female predominance ($p=0.03$). No significant correlation between *KRAS* protein expression with age, tumor topography, lymph node metastases, TNM staging, and tumor differentiation. In conclusion, IHC was regarded as cost-effective, non-specific for codons, and may complement PCR in the detection of *KRAS* gene mutation.

1 INTRODUCTION


Colorectal cancer (CRC) is one of the most common cancer worldwide and is the second leading cause of cancer deaths (Jemal et al., 2011). Sporadic CRC frequently arises through the activation of oncogenes such as *KRAS* and *BRAF* as well as inactivation of tumor suppressor and mismatch repair genes (Raskov, Pommergaard, Burcharth, & Rosenberg, 2014). *KRAS* mutation is one of the first alterations that occur in colorectal tumorigenesis (Rajagopalan et al., 2002). Mutation of *KRAS* occurs approximately in 14%-50% of CRC and frequently detected in codon 12 and codon 13 (Sammoud et al., 2012).


Anti-epidermal growth factor receptor (EGFR) antibody such as cetuximab and panitumumab has been approved for CRC treatment. It engaged with the extracellular domain of EGFR, blocks ligand binding, and leads to inhibition of downstream *RAS-RAF-MEK-ERK* signaling pathway (Porru, Pompili, Caruso, Biroccio, & Leonetti, 2018). However, this therapy is not recommended for use in patients with


KRAS mutation because of anti-EGFR antibody resistance (De Roock et al., 2010). Therefore, *KRAS* status becomes an important biomarker for patient selection.

PCR is an established assay for *KRAS* mutation detection since this analysis has favorable sensitivity even in samples with low tumor cells (Cree, 2016). However, there are some weaknesses of PCR assays in the clinical setting such as high-cost value and specific codon properties of this method. Immunohistochemistry (IHC) has been suggested as the prior screening method before genetic testing (Wan Juhari et al., 2015). It has been a part of routine service in most of the pathology laboratories which not as expensive as molecular detection screening.

In the detection of MMR defects, IHC showed high sensitivity and specificity compared to molecular MSI-testing (Shia, 2008). However, in the screening of ras gene aberration, several previous studies revealed conflicting results (Elsabah & Adel, 2013; Piton, Borrini, Bolognese, Lamy, & Sabourin, 2015). In this study, we evaluated the

^a <https://orcid.org/0000-0002-3807-852X>

^b <https://orcid.org/0000-0002-2870-5358>

^c <https://orcid.org/0000-0002-4333-8701>

immunoexpression of *KRAS* proteins in CRC. We discuss the result of *KRAS* immunohistochemistry and its relationship with some of the clinicopathological features.

2 MATERIALS AND METHODS

This study was approved by the Research Ethics Committee of Faculty of Medicine Universitas Jenderal Soedirman. A total of 45 Formalin-fixed paraffin-embedded (FPPE) tissue blocks of CRC patients underwent colectomy were collected from Margono Soekarjo Hospital and private pathology laboratory from January to December 2019.

FPPE tissue blocks were subjected to staining by immunohistochemical assays. Sections of FPPE tissue blocks (4 µm) were transferred to positively charged slides. Then, they were subjected to deparaffinized, rehydration, and blocking with hydrogen peroxide and antigen retrieval (Dako target retrieval solution, citrate buffer pH 6.0) at 100 °C for 10 minutes. After a short rinsed in phosphate-buffered saline (PBS), slides then incubated overnight at room temperature with primary antibody against *KRAS* oncoprotein (*orb53139 KRAS* polyclonal antibody: dilution 1:100, UK). Slides were washed with PBS, then incubated for 30 minutes with labeled secondary antibody. Product visualization (Dako) was performed with diaminobenzidine substrate as the chromogen. The slides were counterstained with Mayer's hematoxylin and washed once each with distilled water and PBS. Finally, slides dehydrated with ethanol, cleared in xylene, and mounted under a coverslip.

Slides were evaluated under a light microscope by pathologists subjectively. Sample with no primary antibody added was used as a negative control. The cytoplasmic expression of *KRAS* protein was assessed using the previously established criteria of Allred *et al* (Allred, Harvey, Berardo, & Clark, 1998). We considered positive expression if the score of more than 2 in tumor cells.

The corresponding clinical and pathological data including sex, age, tumor topography, lymph node metastases, TNM staging, and tumor differentiation were obtained from a review of patient records. Association between clinicopathological parameters and *KRAS* protein immunostaining was statistically examined by the Chi-square test, and p-value < 0.05 was considered significant.

3 RESULTS

Table 1 shows the clinicopathological features of CRC cases. More than half of the patients were male. The mean age of the patients was 52.2±12.5 years, and most of them were >40 years old age. The majority of the CRC were located on the distal colon, and most of them were in stage 3 with well/moderate differentiation.

Table 1: Association between *KRAS* protein expression and clinicopathological features of CRC.

Features	<i>KRAS</i> protein expression		p
	Positive n (%)	Negative n (%)	
Sex			0.03
Male	5(35.7)	22(71)	
Female	9(64.3)	9(29)	
Age			0.63
≤40	3(21.4)	7(22.6)	
>40	11(78.6)	24(77.4)	
Topography			0.62
Proximal colon	5(35.7)	11(35.5)	
Distal colon	9(64.3)	20(64.5)	
Lymph Node Status			0.15
Positive	7(50)	9(29)	
Negative	7(50)	22(71)	
Staging			0.15
Stage 2	7(50)	9(29)	
Stage 3	7(50)	22(71)	
Differentiation			0.69
Well and moderate	14(100)	30(96.8)	
Poor	0(0)	1(3.2)	

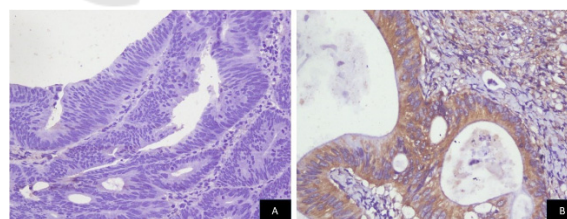


Figure 1: Representative photomicrographs of *KRAS* immunostaining in CRC tissues (A. Negative expression; B. Positive expression; 400x magnification).

Positive *KRAS* protein expression was found in 14(31.1%) of cases (Figure 1). We found a significant association between positive *KRAS* protein expression and female predominance. Nevertheless, our study did not reveal any statistical association between *KRAS* protein expression with age,

topography, lymph node status, tumor staging, and tumor differentiation.

4 DISCUSSION

Mutation of RAS proto-oncogenes is frequently found in human cancer. In colorectal carcinogenesis, mutation of *KRAS* leads to uncontrolled proliferation and malignant transformation. Nowadays, the determination of the *KRAS* mutation is mandatory for treatment with anti-EGFR therapy in patients with CRC. *KRAS* and *BRAF* mutations play a pivotal role in colorectal carcinogenesis and are related to the main resistance to anti-EGFR therapy (Larki et al., 2017). Unfortunately, mutation of *KRAS* has only been detected commonly in codon 12,13, and 61 (Lee et al., 2017). Therefore, expanding RAS testing in CRC to analyze more mutations may better predict benefit from anti-EGFR therapy.

However, increase testing volume will increase testing costs which may have economic implications. Previous studies revealed that single standard *KRAS* exon 2 testing was more than threefold costly than single antibody IHC assay (Kircher, Mohindra, & Nimeiri, 2015; Muirhead, Aoun, Powell, Juncker, & Mollerup, 2010). Thus, the morphological study followed by protein detection using IHC appears to be an alternative to molecular screening. IHC of *KRAS* might be useful as a prognostic and predictive marker in CRC. *KRAS* positive protein expression was associated with the disease aggressiveness of CRC. There was a significantly reduced relapse-free survival (RFS) in rectal cancer patients with *KRAS* positive protein expression (Kanik, Gajjar, & Ghosh, 2018).

In the present study, we detected *KRAS* protein expression in 31.1% of CRC cases. This result was close to study in Europe (33%) (Piton et al., 2015) but lower than study in Egypt (42.3%) (Elsabah & Adel, 2013). This *KRAS* IHC positivity was also close to a study that revealed *KRAS* mutation in 32.8% of CRC cases previously (Liu, Jakubowski, & Hunt, 2011). However, other studies found mutation positivity range between 14% to 50% (Sammoud et al., 2012). These differences were reported because of several weaknesses of mutation analysis such as codon specific mutation sites, ethnic variations (Zhang et al., 2015), diet, and lifestyle factors (Hughes, Simons, van den Brandt, van Engeland, & Weijenberg, 2017).

Our data demonstrated the predominance of *KRAS* protein expression in female CRC patients. This finding was in line with several previous studies that reported a correlation between mutated *KRAS*

and the female gender in CRC (Li et al., 2015; Tong et al., 2014). However, other reports using IHC assays did not demonstrate such a relationship (Kanik et al., 2018; Sammoud et al., 2012). A possible explanation for our result is likely complex and multifactorial including lifestyle factors and the composition of gut microbiota which varies among gender (Kostic et al., 2011). Female sex hormones are related to colorectal carcinogenesis by their effects on the production of bile acid, bowel transit time, and bacterial fermentation (Sammoud et al., 2012).

In this recent study, we did not find an association between *KRAS* protein expression and the age of patients. This is in keeping with some previous reports both using IHC or molecular testing (Elsabah & Adel, 2013; Rosty et al., 2013). However, another study reported that *ras p21* IHC overexpression was relatively related to the advanced age of patients (Sammoud et al., 2012). This difference result might be caused by different classification of the patient's age.

Besides, we did not discover any significant relationship between *KRAS* protein expression and other clinicopathological parameters such as topography, lymph node status, stage, and differentiation of the tumors. Our result was in agreement with previous studies using either IHC (Elsabah & Adel, 2013; Piton et al., 2015) or PCR assays (Sammoud et al., 2012). Nevertheless, other reports detected an association between mutant *KRAS* with mucinous subtype and greater differentiation of CRC (Zhang et al., 2015). Unfortunately, in our study, we only had one sample of poorly differentiated CRC, and showing negative *KRAS* protein staining.

5 CONCLUSIONS

The prevalence of positive *KRAS* protein in CRC was relatively the same as the prevalence of *KRAS* mutation. However, the use of polyclonal antibody which not specific to detect *KRAS* mutant became one of the limitations of *KRAS* IHC assays. Therefore, the development of a monoclonal antibody designed against the mutated *KRAS* domain is necessary. This could greatly assist the screening of CRC patients for anti-EGFR therapies. In the future, IHC could become a promising tool in diagnostic and prognostic decisions.

REFERENCES

- Allred, D. C., Harvey, J. M., Berardo, M., & Clark, G. M. (1998). Prognostic and predictive factors in breast cancer by immunohistochemical analysis. *Mod Pathol*, *11*(2), 155-168.
- Cree, I. A. (2016). Diagnostic RAS mutation analysis by polymerase chain reaction (PCR). *Biomol Detect Quantif*, *8*, 29-32. doi:10.1016/j.bdq.2016.05.001
- De Roock, W., Jonker, D. J., Di Nicolantonio, F., Sartore-Bianchi, A., Tu, D., Siena, S., . . . Tejpar, S. (2010). Association of KRAS p.G13D mutation with outcome in patients with chemotherapy-refractory metastatic colorectal cancer treated with cetuximab. *JAMA*, *304*(16), 1812-1820. doi:10.1001/jama.2010.1535
- Elsabah, M. T., & Adel, I. (2013). Immunohistochemical assay for detection of K-ras protein expression in metastatic colorectal cancer. *J Egypt Natl Canc Inst*, *25*(1), 51-56. doi:10.1016/j.jnci.2013.01.003
- Hughes, L. A. E., Simons, C., van den Brandt, P. A., van Engeland, M., & Weijenberg, M. P. (2017). Lifestyle, Diet, and Colorectal Cancer Risk According to (Epi)genetic Instability: Current Evidence and Future Directions of Molecular Pathological Epidemiology. *Curr Colorectal Cancer Rep*, *13*(6), 455-469. doi:10.1007/s11888-017-0395-0
- Jemal, A., Bray, F., Center, M. M., Ferlay, J., Ward, E., & Forman, D. (2011). Global cancer statistics. *CA Cancer J Clin*, *61*(2), 69-90. doi:10.3322/caac.20107
- Kanik, P., Gajjar, K., & Ghosh, N. (2018). Immunohistochemical Localization of KRAS and BRAF and its Clinical Utility in Patients with Colorectal Cancer. *Colorectal Cancer: Open Access*, *04*(01). doi:10.21767/2471-9943.100051
- Kircher, S. M., Mohindra, N., & Nimeiri, H. (2015). Cost estimates and economic implications of expanded RAS testing in metastatic colorectal cancer. *Oncologist*, *20*(1), 14-18. doi:10.1634/theoncologist.2014-0252
- Kostic, A. D., Gevers, D., Pedamallu, C. S., Michaud, M., Duke, F., Earl, A. M., . . . Meyerson, M. (2011). Genomic analysis identifies association of *Fusobacterium* with colorectal carcinoma. *Genome Research*, *22*(2), 292-298. doi:10.1101/gr.126573.111
- Larki, P., Gharib, E., Yaghoob Taleghani, M., Khorshidi, F., Nazemalhosseini-Mojarad, E., & Asadzadeh Aghdaei, H. (2017). Coexistence of KRAS and BRAF Mutations in Colorectal Cancer: A Case Report Supporting The Concept of Tumor Heterogeneity. *Cell J*, *19*(Suppl 1), 113-117. doi:10.22074/cellj.2017.5123
- Lee, S. H., Chung, A. M., Lee, A., Oh, W. J., Choi, Y. J., Lee, Y.-S., & Jung, E. S. (2017). KRAS Mutation Test in Korean Patients with Colorectal Carcinomas: A Methodological Comparison between Sanger Sequencing and a Real-Time PCR-Based Assay. *Journal of Pathology and Translational Medicine*, *51*(1), 24-31. doi:10.4132/jptm.2016.10.03
- Li, W., Qiu, T., Zhi, W., Shi, S., Zou, S., Ling, Y., . . . Lu, N. (2015). Colorectal carcinomas with KRAS codon 12 mutation are associated with more advanced tumor stages. *BMC Cancer*, *15*, 340. doi:10.1186/s12885-015-1345-3
- Liu, X., Jakubowski, M., & Hunt, J. L. (2011). KRAS gene mutation in colorectal cancer is correlated with increased proliferation and spontaneous apoptosis. *Am J Clin Pathol*, *135*(2), 245-252. doi:10.1309/AJCP7FO2VAXIVSTP
- Muirhead, D., Aoun, P., Powell, M., Juncker, F., & Mollerup, J. (2010). Pathology economic model tool: a novel approach to workflow and budget cost analysis in an anatomic pathology laboratory. *Arch Pathol Lab Med*, *134*(8), 1164-1169. doi:10.1043/2000-0401-OA.1
- Piton, N., Borrini, F., Bolognese, A., Lamy, A., & Sabourin, J. C. (2015). KRAS and BRAF Mutation Detection: Is Immunohistochemistry a Possible Alternative to Molecular Biology in Colorectal Cancer? *Gastroenterol Res Pract*, *2015*, 753903. doi:10.1155/2015/753903
- Porru, M., Pompili, L., Caruso, C., Biroccio, A., & Leonetti, C. (2018). Targeting KRAS in metastatic colorectal cancer: current strategies and emerging opportunities. *J Exp Clin Cancer Res*, *37*(1), 57. doi:10.1186/s13046-018-0719-1
- Rajagopalan, H., Bardelli, A., Lengauer, C., Kinzler, K. W., Vogelstein, B., & Velculescu, V. E. (2002). Tumorigenesis: RAF/RAS oncogenes and mismatch-repair status. *Nature*, *418*(6901), 934. doi:10.1038/418934a
- Raskov, H., Pommergaard, H. C., Burcharth, J., & Rosenberg, J. (2014). Colorectal carcinogenesis--update and perspectives. *World J Gastroenterol*, *20*(48), 18151-18164. doi:10.3748/wjg.v20.i48.18151
- Rosty, C., Young, J. P., Walsh, M. D., Clendenning, M., Walters, R. J., Pearson, S., . . . Buchanan, D. D. (2013). Colorectal carcinomas with KRAS mutation are associated with distinctive morphological and molecular features. *Modern Pathology*, *26*(6), 825-834. doi:10.1038/modpathol.2012.240
- Sammoud, S., Khiari, M., Semeh, A., Amine, L., Ines, C., Amira, A., . . . Saadia, B. (2012). Relationship between expression of ras p21 oncoprotein and mutation status of the K-ras gene in sporadic colorectal cancer patients in Tunisia. *Appl Immunohistochem Mol Morphol*, *20*(2), 146-152. doi:10.1097/PAL.0b013e3182240de1
- Shia, J. (2008). Immunohistochemistry versus microsatellite instability testing for screening colorectal cancer patients at risk for hereditary nonpolyposis colorectal cancer syndrome. Part I. The utility of immunohistochemistry. *J Mol Diagn*, *10*(4), 293-300. doi:10.2353/jmoldx.2008.080031
- Tong, J. H., Lung, R. W., Sin, F. M., Law, P. P., Kang, W., Chan, A. W., . . . To, K. F. (2014). Characterization of rare transforming KRAS mutations in sporadic colorectal cancer. *Cancer Biol Ther*, *15*(6), 768-776. doi:10.4161/cbt.28550
- Wan Juhari, W. K., Wan Abdul Rahman, W. F., Mohd Sidek, A. S., Abu Hassan, M. R., Ahmad Amin Noordin, K. B., Zakaria, A. D., . . . Zilfalil, B. A. (2015). Analysis of Hereditary Nonpolyposis Colorectal Cancer in Malay Cohorts using

Immunohistochemical Screening. *Asian Pac J Cancer Prev*, 16(9), 3767-3771.

doi:10.7314/apjcp.2015.16.9.3767

Zhang, J., Zheng, J., Yang, Y., Lu, J., Gao, J., Lu, T., . . . Liu, T. (2015). Molecular spectrum of KRAS, NRAS, BRAF and PIK3CA mutations in Chinese colorectal cancer patients: analysis of 1,110 cases. *Sci Rep*, 5, 18678. doi:10.1038/srep18678

