

Perianal Giant Condyloma Acuminatum with HIV Treated with Surgical Excision

Irvin Aldikha^{1*}, Rr. Widya Kusumaningsih¹, Asih Budiastuti¹, Muslimin¹,
Meira Dewi Kusuma Astuti²

¹Department of Dermatovenereology, Medical Faculty of Diponegoro University / Dr. Kariadi Hospital, Semarang

²Department of Pathological Anatomy, Medical Faculty of Diponegoro University / Dr. Kariadi Hospital, Semarang

*Corresponding author

Keywords: Giant condyloma acuminatum (GCA), HPV

Abstract: Giant condyloma acuminatum (GCA) is a large condyloma caused by Human papillomavirus (HPV) infection mostly type 6 and 11, that is locally invasive and does not metastasize. Homosexual is at risk for HIV infection and acquiring condyloma acuminatum with 53% of prevalence rate. Currently, there is no gold standard in managing the GCA case. A 20-year-old man presented with a single wart on the perianal area for four months previously. He had a past unprotected sexual history and multiple male partners. Physical examination revealed a cauliflower-like verrucous tumor on the perianal area, 8 x 6 x 3 cm in size. The anti-HIV screening was reactive. The histopathological examination showed hyperplastic stratified keratinized squamous epithelium with papillomatous growth, acanthosis and koilocytosis, supported the diagnosis of condyloma acuminatum. Due to the size of the tumor, the location of the tumor, and the patient's immune status; the patient was treated with surgical excision combined with ARV therapy (tenofovir, lamivudine, efavirenz). The third-month post-surgery evaluation showed no sign of recurrence. Surgical excision and ARV therapy in perianal GCA patient with HIV yielded a satisfactory result. Regular evaluation after surgery is required to identify and prevent recurrence or metastasize potential.

1 INTRODUCTION

Giant condyloma acuminatum (GCA), also known as Buschke-Lowenstein tumor (BLT) is a large condyloma of the anogenital region caused by HPV infection primarily type 6 and 11, that is locally invasive and does not metastasize.¹ Immunosuppressive condition, especially in HIV patients, are ten times susceptible to condyloma acuminatum (Indriatmi et al, 2018). HIV-positive men who have sex with men (MSM) have a higher risk to acquire condyloma acuminatum, with the prevalence rate of 53%. (Heukelom,2016) GCA has a risk for transformation into an aggressive squamous cell carcinoma (Kose et al, 2016).

Therapeutic option for this condition is various, such as topical therapy, surgery, and systemic therapy (Murtiastutik et al, 2008). Currently, there is no gold standard in managing the GCA case (Mistrangelo et al, 2018). Recurrences after therapy often occur. A study found that condyloma acuminatum relapsed as much as 12,9% on HIV-infected patients, compared

to 9,3% on non-HIV-infected patients (Indriatmi et al, 2018).

This case report aims to report a case of perianal giant condyloma acuminatum with HIV, which was treated with excisional surgery and anti-retroviral drugs (ARV).

2 CASE

The patient was an unmarried, 20-year-old male, of Javanese race (Indonesian nationality), who came to Dermatovenereology Clinic at Dr. Kariadi General Hospital Semarang with a perianal wart since four months previously. Initially, the size was as small as a corn kernel; eventually, it grew bigger; it was not painful or itchy and did not easily bleed. The patient also felt uncomfortable when sitting. His wart has not been treated, and it was his first time experiencing this kind of condition. According to his sexual history, he had anogenital sexual intercourse with

multiple male partners about a year before these symptoms appeared. He did not use condoms during intercourse. There was no history of a genital wound, receiving a blood transfusion, or using injected narcotic drugs. There was no family history of a similar condition. The patient was unemployed. Health services cost was covered by BPJS (national health coverage insurance). The socioeconomic status appeared to be below average.

On physical examination, the patient was fully conscious but experiencing mild pain. He had body height of 164 centimeters and the bodyweight of 57 kilograms, blood pressure was 110/70 mmHg, heart rate 84 times/minute, respiratory rate 20 times/minute and the axillary temperature was 36,6°C. Upon perianal examination, we found a cauliflower-like tumor with a size of 8 x 6 x 3 cm, with verrucous surface and flesh-like color.

Laboratory examination revealed reactive Anti-HIV screening test with CD4 amount of 220 cells/mm³, 16,1 g/dL hemoglobin, and all other blood tests were within average values. On rectoscope examination, the intrarectal mucosa was reddish and no mass found. Histopathology test showed hyperplastic stratified keratinized squamous epithelium with papillomatous growth, acanthosis, koilocytosis; dermis consisted of hyperemic fibrous connective tissue along with scattered lymphocytes, histiocytes, and PMN leucocytes; there were no signs of malignancy. The histopathology result was suggestive of condyloma acuminatum.

The diagnosis of this patient was perianal giant condyloma acuminatum with HIV co-infection. The patient was treated with excisional surgery 1 cm around the border of the lesion and given oral anti-retroviral (ARV) therapy consisted of efavirenz 600 mg, lamivudine 300 mg, and tenofovir disoproxil fumarate 300 mg. Post-operative therapy for this patient was tranexamic acid 500 mg injection three times daily and ketorolac 30 mg injection three times daily. The post-surgery wound healed well. The patient was discharged from the hospital with an excellent general condition and no signs of hemorrhage.

On the third month of evaluation, there were no complaints and signs of recurrences. We suggested him to do another hospital visit at six months after surgery or if the lesion reappeared.

3 DISCUSSION

Classification and nomenclature of broad and extensive condyloma acuminatum remain

controversial. Some authors argue that the classification of GCA applies if the size is more than 2,5 cm.⁶ GCA is a sexually transmitted disease that is presumably caused by HPV infection, mostly HPV type 6 and 11. HPV type 6 and 11 were found in 66% and 33% of the cases of GCA. (Kose et al, 2016). The characteristics of GCA are as follows: slow-growing lesion, locally invasive, and a verrucous surface that cannot spontaneously heal..(Kim et al, 2018)

The patient was a 20-year-old male, with unprotected sexual history and had multiple male partners. From the literature, we found that the incidence of GCA was 0,1%, and a male was more susceptible to GCA than women (2,3:1).(Kim et al, 2018) The mean age at presentation is 44 years old (Kauffman et al,2018) Other possible risk factors are smoking, multiple sex partners, anaerobic infections, local chronic inflammation, and immune deficiency.(Diani et al,2015) The patient was a homosexual which increases his susceptibility to acquiring HIV infection and condyloma acuminatum, even at younger ages. The most common presenting signs of GCA are perianal mass (47%), pain (32%), perianal abscess or fistula (32%) and bleeding (18%). Pruritus, difficulty in walking and defecation have also been reported.¹⁰ This patient also reported discomfort when sitting, but without any pain.

The diagnosis of GCA can be made based on clinical manifestations. Upon physical examination, we found a cauliflower-like perianal tumor with a size of 8 x 6 x 3 cm, with verrucous surface and flesh-like color. From the literature, we found that giant condyloma acuminatum could manifest as a large, exophytic mass with cauliflower-like shape and irregular surface.(Guttadauro et al,2015) GCA is commonly seen in the anogenital region.(Akdag et al,2018) GCA, unlike simple condyloma, it is locally aggressive and destructive. (Kose et al, 2016). In this case, the lesion initially appeared four months ago, and the size increased gradually until it reached the current size. The quick progressivity of GCA might be related to the immunosuppressed state of the patient (CD4 levels of 220 cells/mm³), that significantly affects the process of diminishing HPV infections on the patient. HPV infections on GCA can only be ascertained by the finding of HPV DNA using *polymerase chain reaction* (PCR) method or *Hybrid Capture 2* (HC2) test. The examination using 3 to 5 percent of acetic acid was not performed as it was prone to false-positive. (Indriatmi et al, 2018).

A biopsy could potentially be conducted if the clinical findings were uncertain, such as cases in immunocompromised patients, condyloma acuminatum that has been unsatisfactorily treated in

the past, cases of pigmented warts, warts with ulcerations and to exclude the possibility of malignancies. (Indriatmi et al, 2018). Upon histopathology examination, we found stratified keratinized squamous epithelium with papillomatous growth, acanthosis, and koilocytosis. The dermis consisted of fibrous connective tissue that was hyperemic, along with scattered lymphocytes, histiocytes, and PMN leucocytes. There were no signs of malignancy found within the lesions. This finding is consistent with the literature, where histopathological findings on condyloma acuminatum are characterized by acanthosis and papillomatosis on Malpighi layer, thickening, and elongation of rete ridges, with parakeratosis on the cornified layer. On stratum corneum, we can find mitosis, nucleus koilocytosis, and mononuclear inflammatory cells that infiltrated into the dermis.⁴ The histopathology appearance of GCA is similar to the normal condyloma acuminatum, but it has to be distinguished from squamous cell carcinoma. We can differentiate this condition from squamous cell carcinoma with the aid of histopathological findings because we did not find signs of malignancy (such as infiltration of basal membranes, a vast amount of mitosis, invasion of blood vessels and metastatic lymphatic lesions) in this patient. (Murtiastutik et al, 2008).

Untreated GCA can be locally very destructive, extending into the pelvic organs and bony structure, causing secondary infections, bleeding and its complication. (Kauffman et al, 2018)

Giant condyloma acuminatum can be treated using topical therapeutic modality (podophyllin, fluorouracil, or radiotherapy), surgery (cryotherapy, CO₂ laser surgery, electrosurgery or excisional surgery), and systemic therapeutic modalities such as chemotherapy, immunotherapy or aminolevulinic acid. (Murtiastutik et al, 2008). Because there is no gold standard in managing GCA cases, the chosen treatment for GCA is determined by size, amount, location of the lesion, patient preference, cost, side effects and the experience of the attending doctor. (Mistrangelo et al, 2018)

The patient was treated with excisional surgery 1 cm from the margin of the lesion using a scalpel and then continued with step-by-step cauterization from perianal region to the inner mucosa of the rectum (below the dentate line). According to the literature, surgery was found to be the primary therapeutic modality for GCA with a success rate of 63 to 91%, even after recurrence. (Bessi et al, 2019) Although the post-surgery recurrence rate is still at 50-60%, the

surgical method still has the lowest recurrence risk compared to any other therapeutic modality of this condition. On several cases of GCA treated with massive excisional surgery, there were no recurrences after a notable period of observation. Excisional surgery with 1-cm disease-free margins seems to guarantee the lowest rate of recurrence. (Guttadauro et al, 2015)

The application of topical therapy with podofilin or fluorouracil is no indication for this patient. Podofilin or fluorouracil has a poor outcome in GCA. (Kose et al, 2016). Systemic therapies, although possible, actually were rarely used for treating patients with GCA. This was one of the reasons that encouraged us to choose excisional surgery to treat this patient.

The patient also got tranexamic acid 500 mg injections three times a day and ketorolac 30 mg three times a day by intravenous route as the post-operative therapy. Post-surgery wound healed well during the hospital stay. We discharged the patient on the fifth-day post-surgery, with the good general condition and without any signs of hemorrhage. We suggested the patient visit the hospital one week after the surgery for routine evaluation, or if the lesion reappeared.

Recurrence is a big problem with giant condyloma, particularly in the immunocompromised patient. The estimate of recurrence rate is 66%. (Atkinson et al, 2014) The third-month post-surgery evaluation in this patient showed no complaint and recurrence sign. We then suggest the patient do re-evaluation in the sixth months after surgery. According to the literature, some authors recommend to see patient with a history giant condyloma every six months in the first two years after surgery and then annually. The average time of recurrence is approximately ten months. (Atkinson et al, 2014) Another literature stated that recurrence of the lesion usually happens within the first three months after therapy. (Murtiastutik et al, 2008).

The prognosis for this patient are as follow: *quo ad vitam* and *quo ad sanam* are *dubia ad malam*. This is caused by the inability of the immune system to prevent the entry of pathogens due to the ongoing HIV infection. Not only this will aggravate the current STD condition or make the STD resistant to the therapy, but the patient might potentially get infected with another pathogen that might risk the patient's life. The patient had *quo ad cosmeticam* prognosis of *dubia ad bonam* because the excisional surgery can remove the existing lesions, and the risk of scarring is quite low.

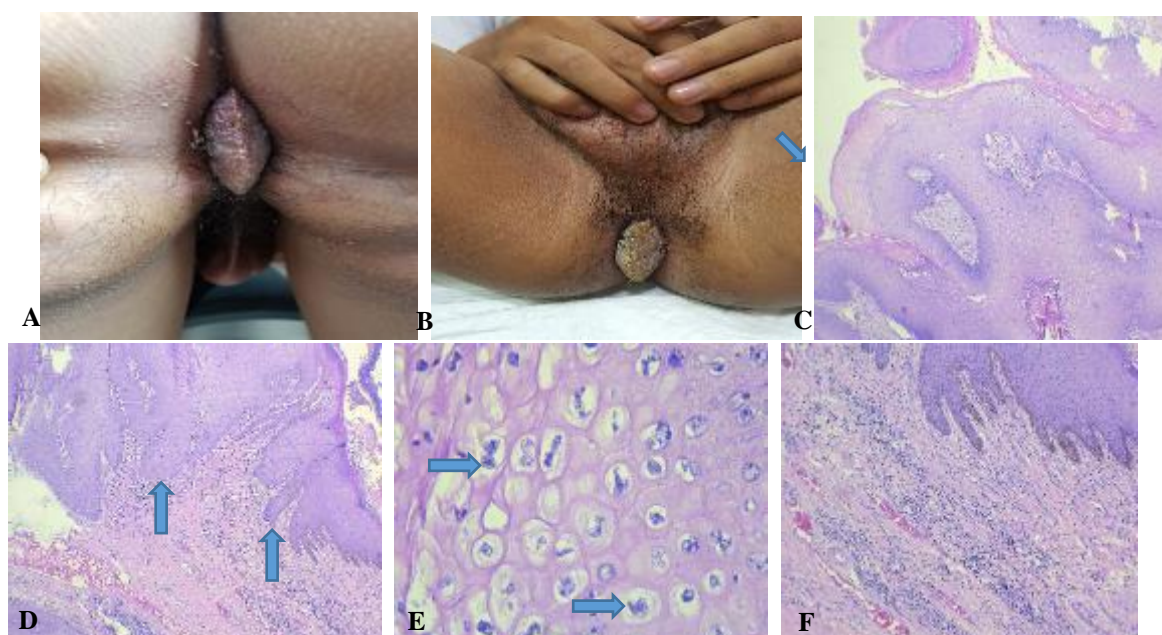


Figure 1. Results of physical and histopathology examination. **A & B.** Physical examination on August 23rd, 2018 at the Dermato-venereology Clinic, Dr. Kariadi General Hospital Semarang; **C.** hyperplastic stratified keratinized squamous epithelium with papillomatous growth [Hematoxylin & eosin (H&E), 40x]; **D.** acanthosis (H&E, 40x); **E.** koilocytosis (H&E, 400x); **F.** dermis consisted of inflammatory cells (H&E, 100x).

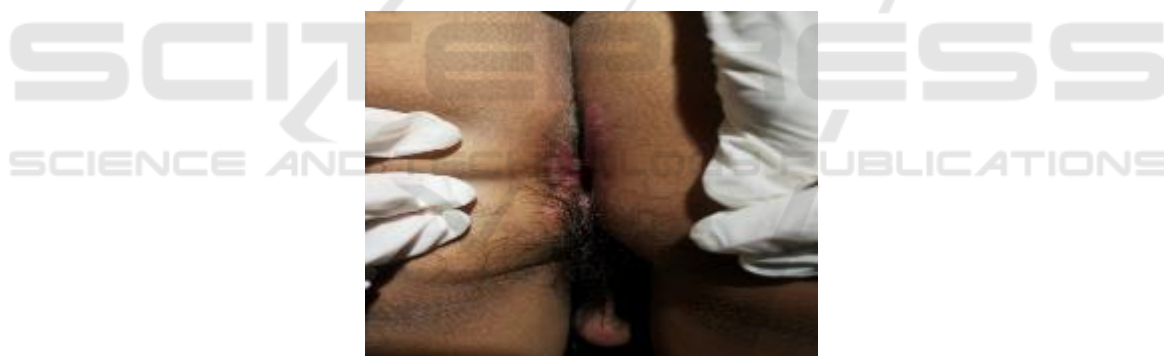

Figure 2. The patients' condition three months after surgery on January 29th, 2019, at the Dermatovenereology Clinic, Dr. Kariadi General Hospital Semarang.

4 CONCLUSION

Surgical excision and ARV therapy in perianal GCA patient with HIV yielded a satisfactory result. The prognosis of the patient, including *quo ad vitam* and *quo ad sanam* are *dubia ad malam*, but *quo ad cosmeticam* is *dubia ad bonam*. Regular evaluation after surgery is required to identify and prevent recurrence or metastasize potential.

REFERENCES

- Akdag O, Yildiran G. 2018. *Malign differentiation of a large Buschke Loewenstein tumor in penis.* Surg J. 4:53-4.
- Atkinson AL, Pursell N, Sisay A. 2014. *The giant condyloma (Buschke Lowenstein Tumor) in the immunocompromised patient.* Case rep obsgyn.1-4.
- Bessi ME, Dougaz W, Jonez M, et al. 2019. *A giant anorectal condyloma is not synonym of malignancy.* J Gastrointest cancer. 1-3.
- Diani M, Boneschi V, Ramoni S, et al. 2015. *Rapidly invasive Buschke Lowenstein tumor associated with*

- Human Papillomavirus types 6 and 52*. Am sex transm dis. 42(10):547-8.
- Guttadauro A, Chiarelli M, Macchini D, et al. 2015. *Circumferential anal giant condyloma acuminatum : a new surgical approach*. Dis of colon and rectum. 58(4):49-52.
- Heukelom SV. 2016. *Condylomata acuminata of HIV-positive men may harbour focal areas of dysplasia: relevant implications for the management of human papillomavirus-induced disease in high-risk patients*. Br J Dermatol. 175:735-43.
- Indriatmi W, Daili SF. 2018. *Kutil anogenital pada infeksi HIV/AIDS*. In: Hidayati AN, Daili SF, Niode NJ, et al, editors. Manifestasi dan tatalaksana kelainan kulit dan kelamin pada pasien HIV/AIDS. 1st ed. Jakarta: FKUI. p. 66-72.
- Kauffman LC, Alexandrescu DT. 2018. *Giant condyloma acuminata of Buschke and Loewenstein*. eMedicine Spec Derm Viral Inf. Available from: <https://emedicine.medscape.com/article/1132178-overview#showall> [accessed 25 February 2018].
- Kim HG, Kesity JE, Griswold JA. 2018. *Giant anorectal condyloma acuminatum of Buschke-Löwenstein presents difficult management decisions*. Surg J. 4:1-4.
- Kose R, Tas S. 2016. *Treatment of a giant condyloma acuminatum by surgical excision*. Firat Med J. 21(1):54-6.
- Koukoura O, Klados G, Strataki M, et al. 2015. *A rapidly growing vulvar condyloma acuminatum in a young patient*. BMJ case rep. 1-2.
- Mistrangelo M, Dal CI, Volpatto S, et al. 2018. *Current treatments for anal condylomata acuminata*. Minerva chir. 73(1):100-6.
- Murtiastutik D. 2008. *Kondiloma akuminata*. In: Barakbah J, Lumintang H, Martodihardjo S, editors. Infeksi Menular Seksual. 1st ed. Surabaya: Airlangga University Press. p. 170-9.