

# Perianal Giant Condyloma Acuminata in Men Who Have Sex with Men with HIV

Eunice Gunawan<sup>1\*</sup>, Syafrida Zidni<sup>1</sup>, Retno Indar Widayati<sup>1</sup>, Puguh Riyanto<sup>1</sup>, Ika Pawitra Miranti<sup>2</sup>  
<sup>1,2,3,4</sup>Departement of Dermatovenereology, Medical Faculty of Diponegoro University/ Dr. Kariadi Hospital, Semarang  
<sup>5</sup>Departement of Pathological Anatomy, Medical Faculty of Diponegoro University/ Dr. Kariadi Hospital, Semarang  
*\*Corresponding auhtor*

Keywords: Giant Condyloma Acuminata, HIV, HPV, MSM

Abstract: Giant condyloma acuminata (GCA) is a large condyloma caused by the proliferation of squamous epithelial cells in the presence of Human Papillomavirus (HPV) infection, mostly type 6 and 11. It is most commonly seen in the genital, anal, and perianal regions. Sexual behavior of MSM further increases the risk of HIV infection and other viral infections such as GCA. An unmarried Javanese 38-year-old man complained of a wart on his perianal area since one year ago. Initially, the lesion was small and progressively enlarged to the size of a chicken's egg. The patient was an MSM with multiple sexual partners. The patient was HIV-positive and received antiretroviral therapy (ARV). The clinical finding showed a large cauliflower-like growth tumor on the perianal area, 7x5 x 2centimeters in size, with a positive ace-to-whitening test. Histopathological examination showed papillomatosis, hyperkeratosis, parakeratosis, and koilocytosis, in accordance with GCA diagnosis. The VCT result showed a CD4 of 51cell/ml. Therapy for this patient was electrodesiccation and curettage. The diagnosis of GCA was established on the history, clinical findings, and histopathological examination. Electrodesiccation and curettage and ARV therapy in perianal GCA patient showed a satisfactory result. Regular examination after therapy is required to identify and prevent recurrence or metastasize potential.

## 1 INTRODUCTION

Giant condyloma acuminata (GCA) is a large condyloma caused by the proliferation of squamous epithelial cells in the presence of Human Papillomavirus (HPV) infection, mostly type 6 and 11. It is most commonly seen in the genital, anal, and perianal regions. GCA also is known as Buschke-Lowenstein Tumor (BLT)-is classified as a sexually transmitted infection due to the fact that more than 90% of cases are transmitted through sexual contact. GCA is a semi-malignant verrucous tumor characterized by aggressive growth into the underlying dermal structure. It is recurrent in 30-70% of cases and can progress slowly into exophytic, ulcerative, and cauliflower-like tumors that can form abscesses and fistulas (Suarez et al, 2016; Rahmayunita et al, 2017).

Due to a variety of sexual behavior nowadays, i.e., men who have sex with men (MSM) can further increase the risk of HIV infection and other viral infections such as GCA. The prevalence of HPV on

MSM with HIV increased sixty-fold compared to men in the general population (Indriatmi et al, 2016).

The treatment for GCA is based on size, location, and a number of lesions. The therapeutic options include topical ointments, cryotherapy, laser vaporization, electro-surgery, and surgical excision (Suarez et al, 2016; Murtiastutik et al, 2008; Mistrangelo et al, 2018).

The aim of this case report is to report a case of perianal giant condyloma acuminata, which is one of the sexually transmitted infections, on an HIV patient with MSM sexual behavior treated with electrodesiccation and curettage.

## 2 CASE

An unmarried Javanese 38-year-old man came to the dermatology and venereology clinic of Dr. Kariadi Hospital Semarang. He complained of a wart on the perianal area since one year ago at first

small and then grew to the size of a chicken's egg. Sometimes itchy but not painful and not quickly bled. HIV screening result from two years ago was positive. The patient takes ARV regularly, consisting of Efavirenz 600mg, Lamivudine 300 mg, and Tenofovir disoproxil 300 mg. The patient had never complained of any wart before. He had a history of sex with multiple men. The patient has never used a condom during intercourse. The history of injury on the genital was denied, the patient has never received a blood transfusion, nor has he had a history of injection drug use. None of his family experienced the same complaint. The patient was a store employee. Health cost was covered by BPJS. The social, economic status was below average.

From the physical examination, we found the patient to be *compos mentis*, with a body height of 165 centimeters, and the bodyweight of 58 kilograms. The blood pressure was 110/70 mmHg, pulse rate 88 times/minute, respiratory rate 20 times/minute, and the axillary temperature was 36.8° C. Dermatologic status found a large cauliflower-like growth tumor covering all perianal area, 7x5 x 2 centimeters in size, with positive acetowhitening test.

Laboratory examination found reactive VCT examination with CD4 of 51 cells/ml, a serologic examination of TPHA and VDRL were negative, and other blood tests were within average values. The rectal examination and the colonoscopy showed the anal canal mucosa was healthy and free of tumor. The histopathological examination showed hyperplastic stratified keratinized squamous epithelium with papillomatosis, parakeratosis, and koilocytosis. Dermis consisted of hyperemic fibrous connective tissue along with scattered lymphocytes, histiocytes, PMN leucocytes; there was no sign of malignancy. And all of these histopathological findings were in accordance with GCA diagnosis.

The diagnosis we established was giant perianal condyloma acuminata on HIV patient. Electrodesiccation and curettage therapy in the lithotomy position and general anesthesia was performed to the patient. Post-operative therapy was Clindamycin 300 mg twice a day for seven days, Mefenamic acid 500 mg three times a day, wound care, and Fusidic acid cream 2% twice daily on post electrodesiccation and curettage wound. The patient also took anti-retroviral (ARV) medicine.

On the first week post-surgery, the wound healed well. And on the fourth-month post-surgery, there was no sign of recurrence.

### 3 DISCUSSION

The diagnosis of Giant condyloma acuminata (GCA) was established from anamnesis, physical examination, and histopathological examination. An unmarried Javanese 38-year-old man came to the dermatology and venereology clinic of Dr. Kariadi Hospital Semarang. He complained of a wart on the perianal area since one year ago at first small and then grew to the size of chicken's egg. Sometimes itchy but not painful and not quickly bled. He had a history of sex with multiple men. The literature mentions that GCA is a verrucous tumor characterized by aggressive growth and mostly seen in the genital, anal, and perianal regions. GCA caused by HPV infection, in which the risk factors for HPV infection are related to sexual behavior, like homosexuality, multiple sexual partners, poor genital hygiene, and chronic genital infection. The incidence of HPV infection is common in active sexual individuals. The prevalence of HPV infection rises over the age of 25 years to 40 years and over. (Suarez et al, 2016; Rahmayunita et al, 2017).

The patient's HIV screening result was positive from two years ago. The patient takes ARV regularly consisting of Efavirenz 600mg, Lamivudine 300 mg, and Tenofovir disoproxil 300 mg. The literature mentions that HIV is one of immunocompromised conditions that also included in sexually transmitted infection. In HIV patients, condyloma acuminata can be an opportunistic infection that often occurs in stage 2, 3, and 4 of HIV. The frequency of condyloma acuminata in men and women is the same, in which the sexual behavior of male who has sex with male (MSM) increases the risk of HIV infection and other viral infections such as HPV infection. Infection is transmitted by sexual contact with the initial lesion at the trauma site during intercourse. Generally, CA does not cause any complaints, but the CA on the perianal region sometimes can cause irritation, pain, or bleeding. (Indriatmi et al, 2016; Murtiastutik et al, 2008)

From the physical examination, we found a sizeable cauliflower-like growth tumor covering all perianal area, 7x5 x 2 centimeters in size, with positive acetowhitening test. According to the literature, the clinical manifestations of GCA can resemble cauliflower-like tumor, consisting of papules or dermal and epidermal nodules on the perineum, genitals, and anus. The literature mentions that GCA is not like a simple condyloma, GCA is a large condyloma, although it is still controversial in the determination of the size. Acetic acid is helpful in visualizing lesions on the cervix and anus. This

examination is necessary for unusual lesions or subclinical lesions. (Indriatmi et al, 2016; Atkinson et al,2014;Murtiastutik et al,2008)

The histopathological examination showed hyperplastic stratified keratinized squamous epithelium with papillomatosis, parakeratosis, and koilocytosis. Dermis consisted of hyperemic fibrous connective tissue along with scattered lymphocytes, histiocytes, PMN leucocytes; there was no sign of malignancy. This finding is consistent with the literature, where histopathological findings for condylomaacuminata are characterized by acanthosis and papillomatosis on Malpighi layer, thickening, and elongation of rete ridges, with parakeratosis on the cornified layer. On stratum corneum, can be found mitotic cells, nucleus koilocytosis, and mononuclear inflammatory cells that infiltrated into the dermis, and no sign of malignancy. The histopathology appearance of GCA is similar to the simple condyloma and difficult to differentiate, but it has to be distinguished from squamous cell carcinoma. (Suarez et al, 2016; Murtiastutik et al, 2008; Murtiastutik et al, 2008)

Management of this patient was electrodesiccation and curettage. Post-operative therapy was Clindamycin 300 mg twice a day for seven days, Mefenamic acid 500 mg three times a day, wound care, and Fusidic acid cream 2% twice daily on post electrodesiccation and curettage wound. Based on the literature, there are several options that are available to treat human papillomavirus (HPV) related anogenital disease, with the treatment of CA being the most widely studied. Treatment of CA is generally not directed at the treatment of HPV infection but rather at the physical removal of lesions or stimulation of the host immune response. Available therapeutic modalities fall into two categories; The first one is patient-applied, such as imiquimod, podofilox gel, the newer polyphenon E ointment, and topical cidofovir; The second is provider-administered, including cryotherapy, surgical removal (electrosurgery, curettage, excision, cryotherapy), intralesional interferon (IFN), trichloroacetic acid (TCA), and intralesionalcidofovir. While there are many available treatment options for HPV-related anogenital disease, comparative trials to evaluate the efficacy of various treatment modalities are lacking, and there is often a lack of consensus regarding best practices among clinicians treating these diseases. The treatment of GCA is determined by the size of the lesion, the location, amount of the lesion, patient preference, maintenance cost, comforts, side effects

and provider experience (Rahmayunita et al, 2017; Indriatmi et al, 2016;Gormley et al,2012).

The prognosis of this patient was quo ad vitam and quo ad sanam dubia ad malam. Due to the inability of the immune system against the entry of pathogenic effectof HIV infection.Furthermore, any STI that the patient suffers from can get worse, recurrent or resistant, and the possibility of developing another life-threatening infection is higher.(Mudrikova et al,2008) Quo ad cosmeticam wasdubiaadbonam. Due tothe complete removal of all lesions and a low risk of scarring.

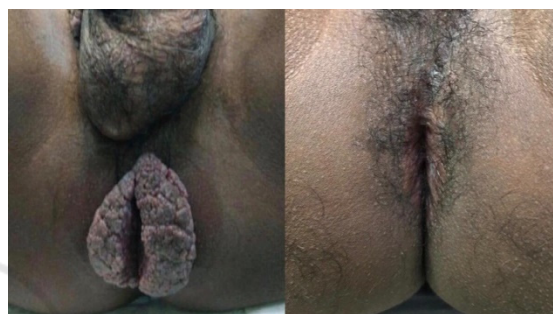

Figure 1. **A.**Pre-operative status of the disease. **B.**The postoperative result after electrodesiccation and curettage (four months post-treatment)

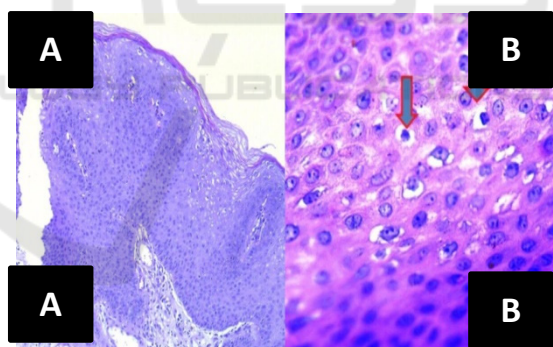


Figure 2. Histopathological Findings. **A.** Acanthosis, Papillomatosis, Koilocytosis (100x). **B.** Koilocytosis (400x) (H&E)

#### 4 CONCLUSION

A case of perianal giant condyloma acuminata in an MSM man with HIV.The management of this patient was performed with electrodesiccation and curettage. The prognosis of this patient was quo ad vitam and quo ad sanam dubiaadmalam, and quo ad cosmeticam dubia ad bonam.

## REFERENCES

- Androphy EJ, Lowy DR. 2013. *Human Papilloma Virus Infection*. In: Fitzpatrick TB, Johnson RA, Wolff K. Color Atlas and Synopsis of Clinical Dermatology. 4<sup>th</sup> edition, United States: McGraw-Hill, h 2878-90.
- Atkinson AL, Pursell N, Sisay A. 2014. *The giant condyloma (Buschke-Lowenstein Tumor) in immunocompromised patient*. Case rep obstetgynecol, pp.1-4
- Gormley RH, Kovarik CI. 2012. *Human – papillomavirus related genital disease in the immunocompromised host*. Journal of the American Academy Dermatology. Vol.66 (6):1-17.
- Indriatmi W, Hanoko RP. 2016. *Kondiloma Akuminatum*. In: Menaldi S, Bramono K, Indriatmi W, editor. Ilmu penyakit kulit dan kelamin. 7<sup>th</sup> edition. Jakarta: FKUI. p.481-3.
- Mistrangelo M, Dal CI, Volpatto S, et al. 2018. *Current treatments for anal conylomata acuminata*. Minerva chir. 73(1):100-6.
- Mudrikova T , Jaspers C, Ellerbroek P, Hoepelman A. 2008. *HPV-related anogenital disease and HIV infection: not always ‘ordinary’condylomata acuminata*. The Netherlands Journal of Medicine. March, 66-3
- Murtiastutik D, Barakbah J, Lumintang H, et al. 2008. *Kondiloma Akuminata*. In: Infeksi Menular Seksual. 1<sup>st</sup> edition. Surabaya: Airlangga University Press. P. 170-9
- Murtiastutik D, Barakbah J, Lumintang H, Martodihardjo S. 2008. *Kondiloma Akuminata*. In: Infeksi Menular Seksual. Surabaya: Airlangga University Press. p.165-69.
- Rahmayunita G, Wibawa LP, Suprpto N. 2017. *Pendekatan Diagnostik dan Penerapan Dermatoterapi Berbasis Bukti*. Jakarta : Indonesian University. p.210-7.
- Suarez-Ibarrola R, Heinze A, Sanchez-Sagastegu F, et al. 2016. *Giant condylomaacuminatum in the genital, perineal, and perianal region*. 7:14-16