

Generalized Pustular Psoriasis in Childhood

Milka Wulansari Hartono^{1*}, Ernawati Hidayat¹, Buwono Puruhito¹, Asih Budiastuti¹,
Meira Dewi Kusuma Astuti²

¹Department of Dermatovenereology, Faculty of Medicine, Diponegoro University /
Dr. Kariadi General Hospital

²Department of Pathological Anatomy, Faculty of Medicine, Diponegoro University /
Dr. Kariadi General Hospital

*Corresponding author

Keywords: Childhood generalized pustular psoriasis, cyclosporine

Abstract: A Generalized pustular psoriasis is a rare form of psoriasis in children. The prevalence of psoriasis in children is $\approx 0.71\%$, the pustular type occurring in 0.6-7%. It is more severe in children and characterized by a generalized pustule, forming the lake of pus, on an erythematous base. A 9-year-old boy presented with fever and sudden onset of pustules eruption on erythematous base over the face, trunk, and extremities. There was no past or family history of psoriasis. The laboratory result was leucocyte count 14.000/ μL , CRP 1.43 mg/L, qualitative ASTO (+). Histopathologic examination revealed skin lesions with psoriasiform reactions, microabscess Munro (+), dermis contained adnexa of the skin, stroma hyperemia with lymphocytes, histiocytes, PMN leucocytes, supporting the diagnosis of generalized pustular psoriasis. Patient was treated with cyclosporine tablet 3 mg/kgbw/day, desoximetasone cream 0.25% twice daily, loratadine tablet 10 mg/day, paracetamol tablet 3x500 mg. Generalized pustular psoriasis often requires systemic and topical therapy because of the severity of the disease. Cyclosporin is recommended as a first-line drug for pediatric generalized pustular psoriasis. Cyclosporin acts by inhibiting T-cell and IL-2. Treatment using oral cyclosporin gave a good outcome in this patient. The eruptions markedly improved after administration of oral cyclosporine 3 mg/kgbw/day for seven days. Topical treatment using a potent corticosteroid, which has anti-inflammatory and antiproliferative properties were co-administered to increase the efficacy. Prognosis *quo ad vitam ad bonam, quo ad sanam dubia ad bonam dan quo ad kosmetikam ad bonam.*

1 INTRODUCTION

Psoriasis is a chronic inflammatory skin disease, characterized by complex alterations in epidermal growth and differentiation (Gudjonsson et al, 2012; Griffi et al, 2010). The exact etiology and pathogenesis is unknown but immunologic driven mediated primarily by T cells in the dermis, genetic and environmental factors also are implicated in the development of the disease (Gudjonsson et al, 2012; Griffi et al, 2010; Voorhees et al, 2019).

Psoriasis is universal in occurrence, affecting 2 to 4% of the world's population, equally common in males and females, may begin at any age, but it is uncommon under the age of 10 years (Saikaly et al, 2016). The prevalence of psoriasis in children is $\approx 0.71\%$. Many subtypes of childhood psoriasis have been described, including generalized pustular

psoriasis (GPP), which is a rare form, affecting 0.6-7% of psoriasis patients (Gupta et al, 2015; Bhuiyan et al, 2017).

Generalized pustular psoriasis is a rare type of psoriasis first described in 1910 by Von Zumbusch, and it is the most severe type and can be potentially life-threatening. It presents abruptly with constitutional symptoms and diffuse erythematous lesions, followed by yellow-colored sterile pustules. The etiology of pustular psoriasis is uncertain. Its onset has been associated with triggering factors such as trauma, infections, emotional stress, vaccinations, sunlights, metabolic factors, alcohol and smoking, drugs, and HIV. The abrupt withdrawal of systemic and topical corticosteroids and the withdrawal of cyclosporin have also been implicated (Gudjonsson et al, 2012;

Griffi et al, 2010; Voorhees et al, 2019; Saikaly et al, 2016; Hoegler et al, 2018).

The pathogenesis of GPP is only partially understood. GPP can present in patients with existing or prior psoriasis Vulgaris or in patients without a history of psoriasis Vulgaris. More than half of the GPP individual cases are caused by recessive mutations in *IL36RN*. *IL36RN* encodes interleukin-36-receptor antagonist (IL-36Ra), which antagonizes three interleukin cytokines (IL-1F6, IL-1F8, and IL-1F9) that are involved in the activation of pro-inflammatory signaling pathways (Hoegler et al, 2018).

The clinical presentation of generalized pustular psoriasis usually presents with 2-3 mm sterile pustules overlying painful, erythematous skin. Patients are visibly ill, with high-grade fever, malaise, leucocytosis, elevated C-reactive protein levels (Hoegler et al, 2018). Diagnostic criteria proposed by Umezama *et al.* are consisted of 1) multiple sterile pustules overlying erythematous skin, 2) fever, malaise and other systemic symptoms, 3) Kogoj spongiform pustules on histopathological analysis, 4) laboratory abnormalities including left shift leucocytosis, elevated erythrocyte sedimentation rate, elevated CRP, elevated ASTO levels, elevated IgG or IgA levels, hypoproteinemia, hypocalcaemia, 5) recurrence of these clinical/histopathological features. (Hoegler et al, 2018) The differential diagnosis of pustular psoriasis is with acute generalized exanthematous pustulosis (AGEP), but AGEP tends to occur and resolve more quickly and is particularly associated with antibiotic use (Hoegler et al, 2018).

For the diagnostic examination, we can do a biopsy for a histopathology examination. The histopathology findings in pustular psoriasis consist of confluent parakeratosis, hyperkeratosis, neutrophils in stratum corneum (Munro microabscesses) and in spinous layer (spongiform pustules of Kogoj), hypergranulosis, sub-parapapillary thinning of the epidermis, regular acanthosis, often with clubbed rete ridges, dilated capillaries in dermal papillae, perivascular lymphocytes (Rapini, 2012).

A broad spectrum of antipsoriatic treatments, both topical and systemic, is available for the management of psoriasis (Gudjonsson et al, 2012). In patients with erythrodermic and pustular psoriasis, treatments with acitretin, methotrexate, or short-course cyclosporine are the treatments of the first choice (Gudjonsson et al, 2012). For children with GPP, first-line treatment is similar to that in adults. As retinoids can cause premature epiphyseal

closure, skeletal hyperostosis, and extraosseous calcification, it may not be ideal first-line therapy. Cyclosporine has fewer known side effects and is often the first treatment used before retinoids. Methotrexate is not approved in children under the age of 2 years. Both methotrexate and cyclosporine must be used with caution because of the long-term oncogenic potential. A recent retrospective chart review assessed the efficacy of cyclosporine in pediatric patients having extensive plaque-type, erythrodermic, and pustular psoriasis. Excellent efficacy (>75% reduction in PASI) was observed in all but three patients (Gudjonsson et al, 2012; Rapini, 2012; Dogra et al, 2017; James et al, 2016; Dogra et al, 2018). Corticosteroids should be utilized with caution, especially in patients with concomitant psoriasis Vulgaris because of the potential to initiate flares. Combination therapies are employed in almost 50% of the children with generalized pustular psoriasis in order to provide optimum disease control. Pustular psoriasis in children has a more favorable course as compared to adults. The response to treatment is good, and remission lasts longer as compared to adults (Dogra et al, 2018).

2 CASE

A nine-year-old boy, Indonesian people, Javanese, was brought by her parents to the dermatovenereology clinic in Karyadi General Hospital on August 10th, 2018 with a chief complaint of sudden onset of pustules eruptions on an erythematous base over the face, trunk, and extremities.

The lesions were developed within 24 h after the patient got vaccinated in his school. The lesion was initially on his face then became more generalized with the involvement of the face, trunk, and extremities. The symptoms were also accompanied by fever and pain on his body. Then his parents brought him to a dermatologist. There he received treatment with topical cream and oral capsule, but the lesions did not improve, so he was referred to Karyadi Hospital.

The patient did not suffer from any other diseases or use any topical or systemic medication before. He had no food or drug allergy. There was no past and family history of dermatosis, including psoriasis. The patient was the first child, and he has a healthy 5-year-old little brother. He was in 2nd-grade junior high school, and his academic status was functional. His parents worked as an employee.

The payment method was using BPJS insurance, and the economic status impression was low.

On the initial physical examination, the patient was looked ill-appearance, body height: 120 cm and body weight: 17 kg. He had a fever, $t = 38^{\circ}\text{C}$. He

also had difficulty to walk because of the pain on his leg. On the dermatology, examination showed typical widespread pustules that developed on an erythematous base on his face, trunk, and extremities. (figure 1).

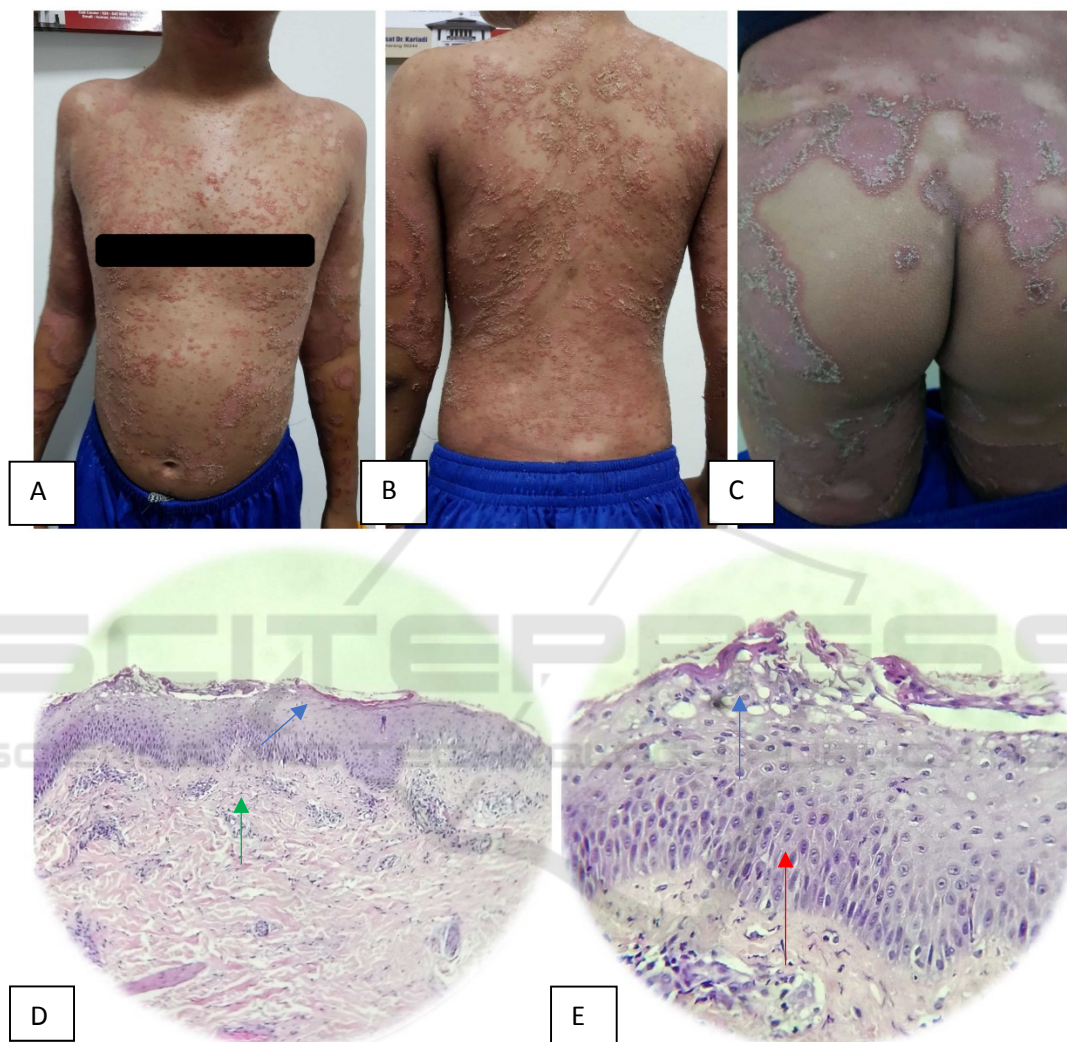


Figure 1. A&B&C. The clinical appearance of the lesion. D. (i) Histopathology examination showed: parakeratosis, \rightarrow dermis with lymphocytes and PMN leucocytes E. Munro's microabscesses acanthosis.

Then we did the laboratory examination, and there were some abnormality including, leucocyte count $14.000/\mu\text{L}$, CRP $1,43\text{ mg/L}$, qualitative ASTO (+). Histopathologic examination revealed skin lesions with psoriasiform reactions, Munro's microabscess (+), dermis contained adnexa of the skin, stroma hyperemia with lymphocytes, histiocytes, PMN leucocytes, supporting the diagnosis of generalized pustular psoriasis. (figure 1)

Based on history taking, physical and dermatology examination, laboratory and

histopathology examination, the diagnosis of generalized pustular psoriasis was made. Differential diagnosis with drug reaction was eliminated.

The patient was treated with cyclosporine tablet 3 mg/kgbw/day , desoximetasone cream $0,25\%$ twice daily, loratadine tablet 10 mg/day , paracetamol tablet $3 \times 500\text{ mg}$. The patient experienced rapid improvement of his skin lesion. At one week follow up, the skin had markedly improved. (figure 2) Then the dosage of cyclosporine was tapered off.

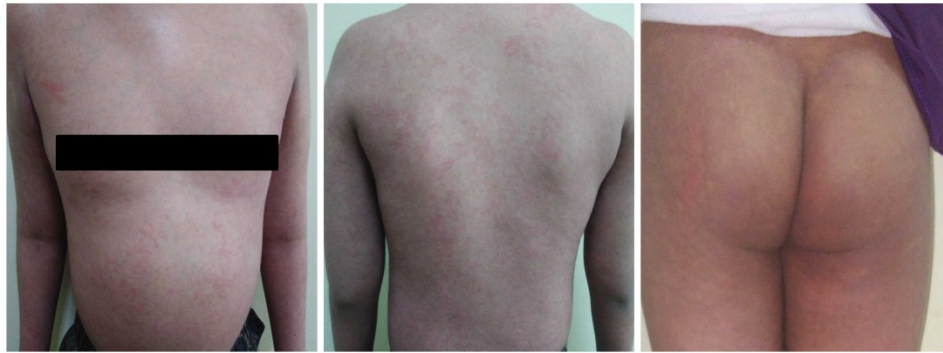

Figure 2. Clinical improvement after one-week administration of cyclosporine and topical desoximetasone Discussion

Diagnosis of generalized pustular psoriasis was made based on history taking, physical and dermatology examination, laboratory, and histopathology examination.

From history-taking, a 9-year-old boy had suddenly developed widespread pustules on an erythematous base, 24 hr after he got vaccinated in his school. There was no past and family history of dermatosis, including psoriasis, and he also admitted that he did not use any topical or systemic medication before. According to the theory, psoriasis is a complex inflammatory skin condition with abnormal epidermal keratinocyte differentiation and hyperproliferation. It is universal in occurrence, equally common in males and females, may begin at any age, but it is uncommon under the age of 10 years. The exact etiology and pathogenesis is unknown but immunologic, genetic, and environmental factors with triggering factors such as trauma, infections, emotional stress, vaccinations, sunlights, metabolic factors, alcohol and smoking, drugs and HIV also are implicated in the development of the disease. (Gudjonsson et al, 2012; Griffi et al, 2010; Voorhees et al, 2019; Saikaly et al, 2016).

From the physical examination, the patient presented typical widespread pustules that developed on an erythematous base on his face, trunk, and extremities, accompanied by constitutional symptoms such as fever and tenderness on the lesion. Psoriasis has many clinical patterns of skin presentation, such as psoriasis vulgaris, guttate psoriasis, small plaque psoriasis, inverse psoriasis, erythrodermic psoriasis, pustular psoriasis. Several clinical variants of pustular psoriasis exist generalized pustular psoriasis (von Zumbusch type), annular pustular psoriasis, impetigo herpetiformis, and two variants of localized)and acrodermatitis continua of Hallopeau. Generalized pustular psoriasis is a distinctive acute variant of psoriasis. It is

characterized by fever, and sudden generalized eruption of pustules arise on erythematous skin. This form of psoriasis is usually associated with prominent systemic

signs and can potentially have life-threatening complications. (Gudjonsson et al, 2012)

A laboratory and histopathological examination were done. Findings revealed some abnormalities such as leucocyte count 14,000/ μ L, CRP 1,43 mg/L, qualitative ASTO (+). Histopathologic examination revealed skin lesions with psoriasiform reactions, Munro's microabscess (+), dermis contained adnexa of the skin, stroma hyperemia with lymphocytes, histiocytes, PMN leucocytes. It is consistent with generalized pustular psoriasis' histopathology findings.

The treatment in this patient were using cyclosporine tablet 3 mg/kgbw/day (tapered-off after 1 week), desoximetasone cream 0,25% twice daily, loratadine tablet 10 mg/day, paracetamol tablet 3x500 mg. According to the theory, combination therapies are employed in almost 50% of the children with generalized pustular psoriasis in order to provide optimum disease control. An initial daily oral regimen of 2.5 mg/kg cyclosporine equally divided in two doses has been recommended. Improvement may be seen within days, but if this does not occur within two weeks, the dosage may be increased gradually to a maximum of 5 mg/kg/day. Maintenance dosage should be reduced to the minimum that allows adequate control. A systematic review of therapies for severe psoriasis concluded that 'cyclosporine is a well-tested treatment for severe psoriasis and in the short term, ideally 3-4 months, is probably more effective than other forms of systemic therapy's (Griffi et al, 2010)

Topical corticosteroid was used in adjunct to systemic cyclosporine as local therapy to increase the efficacy, but the duration and the dosage should be monitored carefully because of the potential

induction of pustules. The paracetamol and loratadine herewere used as symptomatic therapy.(Fujita et al,2018).

In this case report,the patient experienced rapid improvement of his skin lesion. At one week follow up, the skin had markedly improved. Prognosis *quo ad vitam ad bonam, quo ad sanam dubia ad bonam* dan *quo ad kosmetikamad bonam*.

3 CONCLUSION

Generalized pustular psoriasis is a rare form of psoriasis, and onset at children is even rarer. In this case report, combination therapies using systemic cyclosporine and topical desoximetasone, gave a good outcome. There are many factors influence the remission and relapse/worsening of this disease, so despite the therapy, we also provided education for the patient and her family that his disease was a chronic disease, and could be triggered with various factors and to maintain the remission, it needed cooperation between patient, doctors, and parents.

REFERENCES

- Bhuiyan MSI, Zakaria ASM, Haque AKMZ, Shawkat SM, Sultana A. 2017. *Clinico-epidemiological study of childhood psoriasis*. Bangabandhu Sheikh Mujib Med Univ J. 10(2):119.
- Dogra sunil, Bishnoi Anuradha. 2018. *Childhood Psoriasis: What is New and What is News*. Indian Journal of Paediatric Dermatology. 308-14
- Dogra S, Mahajan R, Narang T, Handa S. 2017. *Systemic cyclosporine treatment in severe childhood psoriasis: A retrospective chart review*. J Dermatolog Treat. 28(1):18–20.
- Fujita H, Terui T, Hayama K, Akiyama M, Ikeda S, Mabuchi T, et al. 2018. *Japanese guidelines for the management and treatment of generalized pustular psoriasis: The new pathogenesis and treatment of GPP*. J Dermatol. 45(11):1235–70
- Griffith CEM, Camp RDR HI, Baker J. 2010. *Psoriasis*. In: Burn T, Breathnach S, Cox N, Griffith C, editors. *Rook's textbook of dermatology*. 8th ed. Massachusetts: Blackwell Publishing. p.351- 69.
- Gudjonsson JE, Elder JT. 2012. *Psoriasis*. In: Wolff K, Goldsmith LA, Katz SI, Gilchrist BA, Paller AS, Leffell DJ, editors. *Fitzpatrick's dermatology in general medicine*. 8th ed. New York: McGraw-Hill Companies Inc. p.197-231.
- Gupta S, Deo K, Wadhokar M, Tyagi N, Sharma Y. 2015. *Juvenile generalized pustular psoriasis in a 10-year-old girl*. Indian J Paediatr Dermatology. 0(0):0
- Hoegler KM, John AM, Handler MZ, Schwartz RA. 2018. *Generalized pustular psoriasis: a review and update on treatment*. J Eur Acad Dermatology Venereol. 32(10):1645–51
- James WD, Elston DM, Berger T, editors. 2016. *Seborrheic Dermatitis, Psoriasis, Recalcitrant Palmoplantar Eruptions, Pustular Dermatitis, and Erythroderma*. In: *Andrew's Diseases of The Skin Clinical Dermatology*. twelfth ed. Philadelphia: Elsevier Inc. 187-95
- Rapini RP. 2012. *Eczematous and Paposquamous Diseases*. In : *Practical Dermatopathology*. 2nd edition. London: Elsevier Saunders. 52-4
- Saikaly SK, Mattes M. 2016. *Biologics and Pediatric Generalized Pustular Psoriasis: An Emerging Therapeutic Trend*. Cureus.8(6).
- Voorhees AV, Wanat Karolyn. 2019. *Psoriasis:Erythrodermic and Pustular Variants*. Clinical Advisor Dermatology.