

Generalized Pustular Psoriasis in Childhood with Exogenous Cushing's Syndrome

Fitri Azizah^{1*}, Yusnita Rahman¹, Rahadi Rihatmadja¹, Triana Agustin¹,
Rinadewi Astriningrum¹, Githa Rahmayunita¹

¹*Department of Dermatology and Venereology Faculty of Medicine Universitas Indonesia/
Dr. Cipto Mangunkusumo National General Hospital, Indonesia*

Keywords: Pustular Psoriasis, Childhood, Cushing's Syndrome, Steroid Misuse

Abstract: Pustular psoriasis is characterized clinically by yellowish sterile pustules surrounded by erythema. Pustular psoriasis in children is very rare and could be appear following steroid withdrawal in psoriasis vulgaris. Psoriasis in children usually mild and can be managed with topical treatment, which is considered as the first-line therapy. Misuse of topical and systemic steroid in children could lead to Cushing's syndrome. It is a multisystem disorder resulting from prolonged exposure to excess glucocorticoids, both systemic or topical. Children could easily develop systemic reactions to topical steroids due to their higher ratio of total body surface area to body weight. Here we reported a case of generalized pustular psoriasis (GPP) in a 14-year-old girl who had suffered from Cushing's syndrome due to misuse of oral and topical steroid.

1 INTRODUCTION

Since the introduction in 1950s, topical steroids have become the most commonly prescribed drugs by dermatologists in outpatient setting. Used properly, they are safe and effective, with minimal side effects. Easy access to the drugs and practice of self-medication has resulted in widespread misuse of topical corticosteroids. (Meena S et al., 2015) In case of childhood psoriasis, topical corticosteroids remained the first line therapy and majority of children can be managed only with topical treatment. (Bronckers et al., 2015) Excess intake of glucocorticoids, either systemic or topical could lead to Cushing's syndrome, which characterized clinically by moon face, appearance of dorsocervical and supraclavicular fat pads (buffalo hump), and stretch marks. Cushing's syndrome in children could also manifests as growth deceleration. (Stratakis CA, 2018)

Over the last 35 years, there are 43 cases reported of iatrogenic Cushing's syndrome due to misuse of very potent topical steroid usage in children and adult, particularly in developing countries. The most common purpose of steroid use in the children group is infants with diaper dermatitis and in adult group is psoriasis. (Sahana PK et al., 2015). Pustular psoriasis

is a rare disease, especially in children. Patients with the generalized type of von Zumbuschs and erythroderma have higher risk of mortality due to systemic involvement. Few complications of generalized pustular psoriasis (GPP) are septicemia, hyperthermia, liver damage, and acute renal failure. (Al Aboud DM et al., 2019) Psoriasis vulgaris can either progressed into generalized pustular psoriasis or appear after pustular psoriasis. Various precipitating factors have been reported to trigger or flare acute generalized pustular psoriasis, including corticosteroid use and withdrawal. (Al Aboud DM et al., 2019) Here we reported a case of exogenous Cushing's syndrome resulting from years of topical and oral corticosteroids misuse in a pustular psoriasis patient.

2 CASE

A 14-year-old girl came to our outpatient clinic 5 months ago with generalized erythematous plaques worsening 3 months prior to admission. Her lesions first appeared when she was 4-year-old and was then self-treated with various ointments. The plaques never fully subsided until approximately 5 years later. In the age of 11, she had her first menstrual period and the lesions flared up all over her body and scalp. Her

mother usually bought so-called bitter antipruritic pills from pharmacy to relieve her of the symptoms. She continuously took the medication everyday for almost a year. The plaques recurred temporarily and she had never had her period again since 4 years ago. A year ago, the lesions flared up again and she bought very potent topical steroid to apply all over the body twice daily for about 7 months. Her lesions were not improving so she went to a dermatologist 8 months ago and was sent for biopsy. The histopathology result was psoriasis. She was then given 8 mg methylprednisolone twice daily along with 10 mg cetirizine and mometasone furoate cream. In 2018, she had topical steroids for almost 10 months and oral steroids for around 3 months.

At the time she went to our outpatient clinic, she had moon face, her body weight was 46 kgs and her height was only 137 cm which was short for her age (BMI 24.5). Her skin was thin along with multiple red-purple striae all over her body. She also had an ulcer from a previous motorcycle accident which did not heal completely. Multiple erythematous scaly plaques were found on her scalp, neck, back, and thighs (Figure 1). Dermoscopic findings show regular dotted vessels distributed uniformly across the plaque along with white scales (Figure 2). On her first visit, we tapered off the oral and topical steroid.

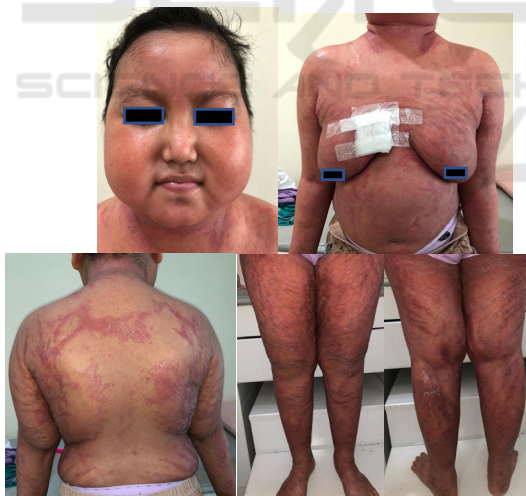

Figure 1. Moon face, striae, and erythematous plaques with scales.

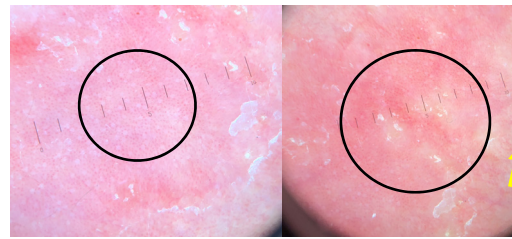


Figure 2. Dermoscopy showed regular dotted vessels (black circle) and white scales (yellow arrows).

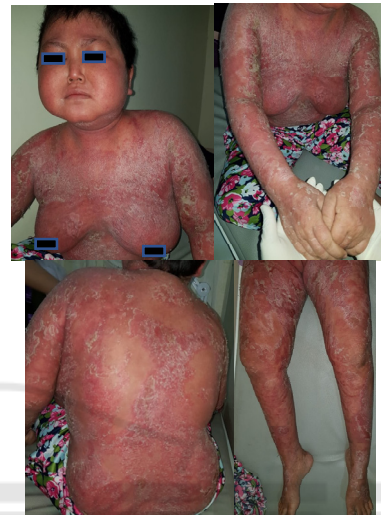


Figure 3. Erythroderma with multiple pustules, lake of pus, and yellow crust.

Until one month later she could not come back to our outpatient clinic. Her medication ran out for the past one week, both oral and topical steroid. Four months ago, she was admitted to the emergency unit with generalized erythematous plaques and multiple pustules with lake of pus and yellow crust (Figure 3). She was moderately ill and tachycardic but without any fever. Her laboratory studies showed elevated white blood cell count of 16,400/ μ L, low morning cortisol level of 1.5 μ g/dL (3.7 – 19.4), and normal level of liver and kidney function. She was given 50 mg cyclosporine twice daily and a change course of oral steroid to hydrocortisone under pediatric endocrinologist's supervision. She had hydrocortisone 40-40 mg and 40-20 mg, every other day and a decrease of 25% of her dose each week was planned to tapered off. She also had petroleum jelly and coconut oil for her scalp.

After two to four weeks of 100 mg cyclosporine per day, her lesions were getting better but then she experienced a flared up which was suspected from stress due to her school's exam. After two months of treatment, her lesions were not fully subsided so her dose was titrated to 125 mg/day and her condition has

improved a lot up until now (Figure 4). Currently her oral steroid is still tapered off, changing back to methylprednisolone 3 mg and 2 mg every other day. Her gynecology ultrasound revealed uterus and ovarium hypoplasia and low level of LH 0.8 mIU/mL, normal level of FSH 6.7 mIU/mL, normal level of estradiol 16.6 pg/mL, and normal level of anti Mullerian hormone 1.39 ng/mL. She still has not had her period and currently on obstetrician-gynecologist supervision because her clinical and laboratory studies did not add up.

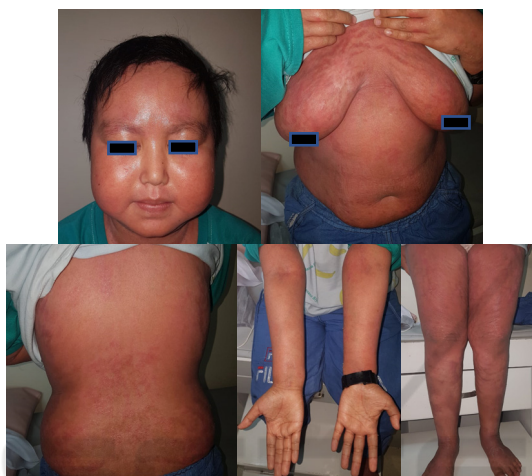

Figure 4. Improvement in both moon face and skin lesions after 3 months.

3 DISCUSSION

Pustular psoriasis is characterized clinically by widespread yellowish sterile pustules surrounded by erythema. The acute generalized type (von Zumbusch) usually presents with systemic symptoms and might evolve into erythroderma. (Al about DM., 2019). Pustular psoriasis in children is very rare, according to a review from Australia, there were only 0.6% cases with pustular variants in 1262 childhood psoriasis patients. (Wang Q, 2017). Various precipitating factors have been reported to trigger acute generalized pustular psoriasis, including corticosteroid use and withdrawal. (Hyde K et al., 2016). Cutaneous lesions characteristics of psoriasis vulgaris can be present before, during, or after an acute pustular episode. In childhood psoriasis, majority of children can be managed only with topical treatment, such as topical steroids. (Bronckers et al., 2015) But when stopped abruptly after long period of usage, corticosteroids withdrawal could triggered the flare of generalized pustular psoriasis. In our case, initially she had psoriasis vulgaris but later developed

generalized pustular psoriasis when her medication stopped.

Misuse of topical steroids in children could easily lead to systemic reactions because of their higher ratio of total body surface area to body weight. Topical corticosteroids were easily absorbed through normal intact skin. Damaged or inflamed skin may increase percutaneous absorption of the drug. Application of steroids to large surface areas, occlusion, vehicle, location of application, and more potent derivatives such as clobetasol propionate, directly increase the risk of hypothalamic-pituitary-adrenal (HPA) axis suppression.⁸ As little as 2 g/day of clobetasol propionate 0.05% cream can cause a decreased morning cortisol level after only a few days. (Hengge UR et al., 2016). (Rahmayunita G et al., 2008) reported a case of Cushing's syndrome due to misuse of topical steroid in a childhood psoriasis but fortunately the patient was able to recover from Cushing's syndrome completely only with permanent striae. In childhood, the characteristics of Cushing's syndrome are truncal obesity, growth failure, striae, hypertension, appearance of dorsocervical and supraclavicular fat pads, and moon face. Clinically, there is no difference between exogenous or endogenous Cushing's syndrome. (Stratakis CA, 2018; Lodish MB et al., 2018). Hypercortisolism is also associated with bone age advancement and premature epiphyseal maturation. Decreased bone mineral density, osteoporosis, and related fragility fractures have been reported in almost 60% patients with glucocorticoid excess. (Raff H et al., 2014). The likelihood of catch up growth after the cure of Cushing's syndrome depends on bone age advancement at the time of diagnosis, but final height in patients with Cushing's syndrome in childhood is known to be compromised. (Raff H et al., 2014). Our patient had low morning cortisol level, moon face, striae, growth retardation, and secondary amenorrhea. High cortisol levels could suppress gonadotropin releasing hormone (GnRH), luteinizing hormone (LH), and follicle stimulating hormone (FSH) release thus ended in amenorrhea. (Raff H et al., 2014). Due to the inconsistent laboratory and clinical data, our patient is currently planned to have more diagnostic tests.

To slowly tapered down exogenous steroids, our patient was given hydrocortisone by pediatric endocrinologist from Department of Child Health. Hydrocortisone are the least potent glucocorticoids but with the highest mineralocorticoid property. Thus, hydrocortisone and cortisone are generally preferred for use in patients with adrenal insufficiency. (Liu D et al., 2013). Recovery from

steroid-induced adrenal insufficiency is time dependent and the adverse effects are generally reversible with lower dosage or discontinuation of treatment. Abrupt cessation of the drugs may precipitate adrenocortical insufficiency, therefore the drugs must be gradually discontinued. (Stratakis CA, 2018; Lodish MB et al., 2018). The physiologic dose of steroids should be given for about 6-9 months because the recovery period of HPA axis suppression is 3.49 ± 2.92 months. (Tempark T et al., 2010). Our patient was tapered down slowly over the past 3 months and was planned to have her morning cortisol level check again in May 2019, 6 months after the initial test.

Depends on the severity, treatments available for childhood psoriasis are emollients, salicylic acid, calcipotriol, coal tar, topical steroids, phototherapy, retinoids, and cyclosporine (Rahmayunita G et al., 2008). Topical steroids are not indicated in severe psoriasis due to the possible side effects of excessive usage. Whereas first line treatment for erythrodermic or pustular psoriasis is acitretin, followed by cyclosporine, phototherapy, methotrexate, anti-TNF agents, and systemic steroids. (Bronckers et al., 2015; Gudjonsson JE et al., 2012). Acute GPP has proven to be, like many psoriasis variants, a difficult disease to treat. (Hyde K et al., 2016). Severe and extensive disease is likely to most effectively be treated with infliximab (TNF- α inhibitor) or cyclosporine, given the quicker onset of action with these drugs. (Hyde K et al., 2016). Our patient was prescribed cyclosporine with initial dose of 100 mg daily. Cyclosporine is an calcineurin inhibitor which inhibits the T-cell activation mediated by antigen. (Gudjonsson JE et al., 2012) It has a rapid onset of action of 2-4 weeks and notable side effects are nephrotoxicity, hypertension, nausea, and diarrhea. (Bronckers et al., 2015; Gudjonsson JE et al., 2012) To date, the efficacy of cyclosporine in pediatric psoriasis is limited. (Hyde K et al., 2016).

Children may require higher dosage than recommended in adults because of greater body surface area to weight ratio. Therefore, the lowest possible dose and shortest treatment period should be used. (Bronckers et al., 2015; Al Aboud DM et al et al., 2019; Hyde K et al., 2016).

Ideally high-potency topical steroids should be obtained only with prescription in order to prevent misuse of topical steroids. (Sahana PK et al., 2015) Patients and especially parents should be informed about the appropriate usage and the possible side effects of the drug. Children are more susceptible to side effects, thus parents should clearly understand

how to use topical steroid wisely. One of the side effects of steroids is immunosuppression which may increase the risk of opportunistic and bacterial infections. Semiz et al reported a fatal case of disseminated cytomegalovirus infection in a Cushing's syndrome patient due to topical steroid use in the diaper area. (Semiz S et al., 2008). Therefore, topical steroids should be used wisely especially in children.

4 CONCLUSION

Adverse effects of steroid-induced adrenal insufficiency is generally reversible and the recovery is time dependent thus the cessation of exogenous steroid should be gradual. During the gradual discontinued of exogenous steroids, systemic agents for psoriasis ie. acitretin or cyclosporine should be initiated. Parents should be noted that misuse of topical and oral corticosteroids could be harmful for children and severe immunosuppression state could end fatally.

REFERENCES

- Al Aboud DM, Kumar S. Pustular psoriasis. 2019. In: *StatPearls [Internet]*. Treasure Island (FL).
- Bronckers IMGJ, Paller AS, Geel MJ, Kerkhof PCM, Seyger MMB. 2015. Psoriasis in children and adolescents: diagnosis, management and comorbidities. *Pediatr Drugs*.;17(5):373-384.
- Gudjonsson JE, Elder JT. Psoriasis. In: Goldsmith L, Katz S, Gilchrest B, Paller A, Leffell D, Wolff K, eds 2012.. *Fitzpatrick's Dermatology in General Medicine*. Eight. McGraw-Hill;:197-231
- Hyde K, Kivelevitch D, Mansouri B. 2016. Pustular psoriasis: pathophysiology and current treatment perspectives. *Psoriasis Targets Ther*.;6:131-144.
- Hengge UR, Ruzicka T, Schwartz RA, Cork MJ. 2006. Adverse effects of topical glucocorticosteroids. *J Am Acad Dermatol*.:1-15.
- Liu D, Ahmet A, Ward L, et al. 2013. A practical guide to the monitoring and management of the complications of systemic corticosteroid therapy. *Allergy Asthma Clin Immunol*.;9(1):30.
- Lodish MB, Keil MF, Stratakis CA. 2018. Cushing's syndrome in pediatrics: an update. *Endocrinol Metab Clin N Am*.;47:451-462.
- Meena S, Gupta LK, Khare AK, et al. 2017. Topical corticosteroids abuse: a clinical study of cutaneous adverse effects. *Indian J Dermatol*.;62(6):675.
- Rahmayunita G, Pulungan AB, Wiryadi BE, Wisesa TW, Sugito TL. 2008. Cushing's syndrome induced by misuse of topical corticosteroids in a child with psoriasis vulgaris. *Med J Indones*.;17(4):281-286.
- Raff H, Sharma ST, Nieman LK. 2014. Physiological basis for the etiology, diagnosis, and treatment of adrenal

- disorders: Cushing's syndrome, adrenal insufficiency, and congenital adrenal hyperplasia. *Compr Physiol.*;4(2):739-769.
- Stratakis CA.2008.. An update on Cushing syndrome in pediatrics. *Ann Endocrinol (Paris)*
- Sahana PK, Sarma N, Sengupta N, Somani PS. 2015. A florid case of iatrogenic Cushing's syndrome induced by topical steroid with osteoporosis and hypogonadism. *Indian J Dermatol.*;60(4):420.
- Semiz S, Is Y, D M. 2008.Two cases of Cushing's syndrome due to overuse of topical steroid in the diaper area. *Pediatr Dermatol.*;25(5):544-547.
- Tempark T, Phatarakijirund V, Chatproedprai S, Watcharasindhu S, Supornsilchai V, Wananukul S. 2010. Exogenous Cushing's syndrome due to topical corticosteroid application: case report and review literature. *Endocr.*;38:328-334.
- Wang Q. 2017.Clinical features of von Zumbusch type of generalized pustular psoriasis in children: a retrospective study of 26 patients in southwestern China.;92:319-322.

