

A Rare Case of Epidermolytic Hyperkeratosis: Recognition of Distinctive Clinical and Histopathological Signs

Sarah Mahri^{1*}, Lidwina Anissa¹, Rinadewi Astriningrum¹, Githa Rahmayunita¹,
Triana Agustin¹, Rahadi Rihatmadja¹

¹Department of Dermatology and Venereology Faculty of Medicine Universitas Indonesia/
Dr. CiptoMangunkusumo National Central General Hospital, Indonesia

Keywords: Epidermolytic hyperkeratosis, clinical signs, histopathology

Abstract: Epidermolytic hyperkeratosis (EHK) is a rare autosomal dominant genodermatosis with a prevalence of 1:100,000 to 1:300,000. Mutations primarily of keratin 1 or keratin 10 cause defective keratinization, leading to skin fragility, blistering, and hyperkeratosis. Neonates with EHK are at risk of developing electrolyte imbalance, sepsis and malnutrition leading to a considerable mortality. Therefore its diagnosis is important. As the clinical features of EHK become more apparent with age, a wide spectrum of other genodermatosis should be considered as differentials at different stages of the disease process. A 5-year-old boy presented to our department with dirty brown, corrugated plaques distributed all over his body. He had had history of trauma-related blistering since two days after birth. As he aged, there was a decrease in development of blisters and erosions, with accompanying increase in severity of hyperkeratosis and foul odor. Physical examination revealed thickened, brown plaques over the neck, trunk, extremities, and scalp. Cobblestone pattern were visible over the knees, elbows, and posterior of hands and feet, in addition to multiple superficial erosions. Histopathologic examination showed massive hyperkeratosis, acanthosis, spongiosis, lysis and clumping of keratinocytes in the stratum spinosum to granulosum. The diagnosis of EHK was made. Vaseline, coconut oil, and antiseptic soap gave slight, but acceptable improvement. EHK is rare, thus recognizing its distinctive clinical patterns is necessary to avoid delayed diagnosis and gave necessary genetic counselling and prompt treatment.

1 INTRODUCTION

Epidermolytic hyperkeratosis (EHK), also known as bullous congenital ichthyosi form erythroderma is an autosomal dominant trait with a prevalence of approximately 1 in 100,000 to 300,000 persons.¹⁻⁴ The disease is named for the distinctive histopathologic feature of vacuolar degeneration and associated hyperkeratosis of the epidermis.⁴ EHK is caused by mutations in keratin 1 or keratin 10, resulting in subsequent skin cell collapse and fragility. This clinically manifests as blistering, later followed by hyperkeratosis and hyper proliferation. Onset typically occurs in newborn, with generalized erythroderma. Erosions, blisters, and peeling are present. Although the blistering and erythema often improve over time, hyperkeratotic scale becomes prominent, most commonly over the neck, hands, feet, and joints. Other affected areas include the scalp and infragluteal folds.¹⁻⁴ Neonates with EHK

are at risk of developing sepsis, electrolyte imbalance, and malnutrition leading to a considerable mortality, therefore its diagnosis is important.

Between 2016-2018 there were no cases of epidermolytic hyperkeratosis in our institution. We herein report a rare case of epidermolytic hyperkeratosis in a 5-year-old boy. The purpose of this report is to familiarize with its characteristic features that enable clinician to make early diagnosis and distinction with other ichthyosis and bullous diseases of childhood, as well as to discuss the therapeutic possibilities.

2 CASE

A 5-year-old boy was consulted to our clinic with dirty brown, corrugated hyperkeratotic plaques

distributed all over his body beginning two years before.

The history started two days after birth, when he developed blisters on his trunk and extremities, which ruptured and became eroded. Lesions recurred over his whole body, sparing the palms, soles, and face. Blisters and erosions usually healed leaving hyperpigmentation without scarring. Although he continued to develop erythema and blisters, they decreased in severity and frequency with age. Superficial erosions ceased few months after his birth and followed by hyperkeratosis lesions.

By the age of three, the patient developed generalized hyperkeratosis and scaling over his trunk, extremities and scalp. The lesions occasionally became pruritic. He would scratch and peel the affected skin and sometimes they became infected. As hyperkeratosis became more

pronounced, so did the foul odor. The disease did not appear to involve the nail or impair neurological functions.

He has a history of hyper IgE and delayed speech. He is the only child of healthy, non-consanguineous parents. No family history of similar disorders and no history of restrictive membrane at birth.

Thickened, brown, dirty corrugated plaques were found on physical examination, distributed over the neck, trunk, extremities, and scalp, affecting approximately 95% of his body surface area. Cobblestone pattern were visible over the knees, elbows, and posterior of hands and feet. Areas of superficial erosion were evident on his left ear, back, upper and lower limbs. His scalp hair were enclosed in thick whitish scales.(Figure 1-3).

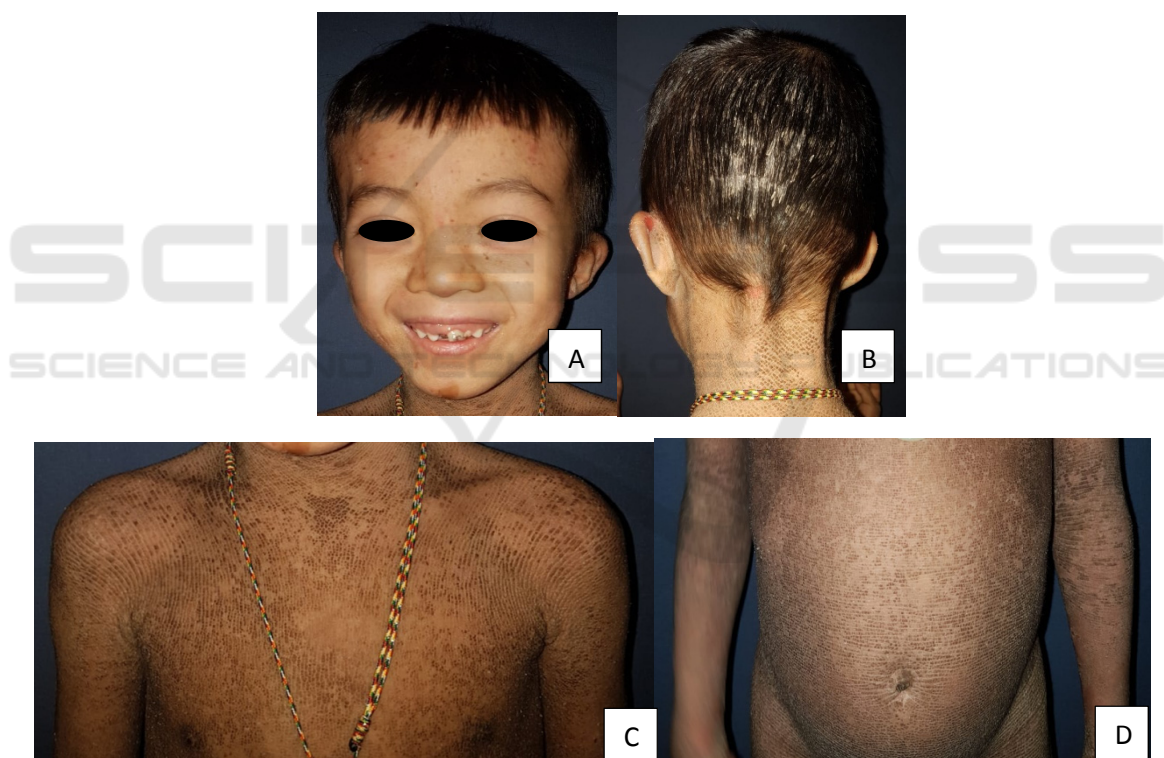

Figure 1. Clinical manifestation. A. Face is spared B. Whitish thick scales on the scalp C,D. Dirty brown, corrugated plaques over the trunk along with areas of superficial erosion.

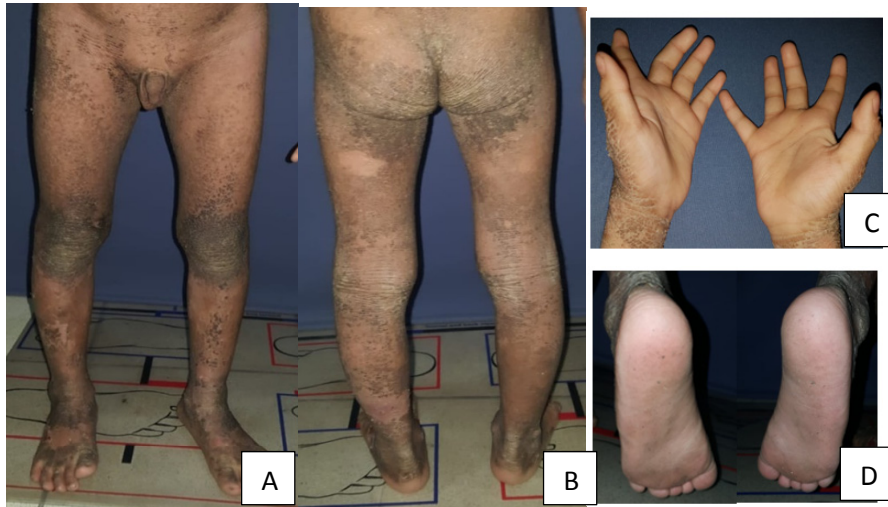

Figure 2. Clinical manifestation. A,B. Hyperkeratotic warty plaques widely spread over the lower limb with areas of superficial erosion C,D. Sparing palms and soles

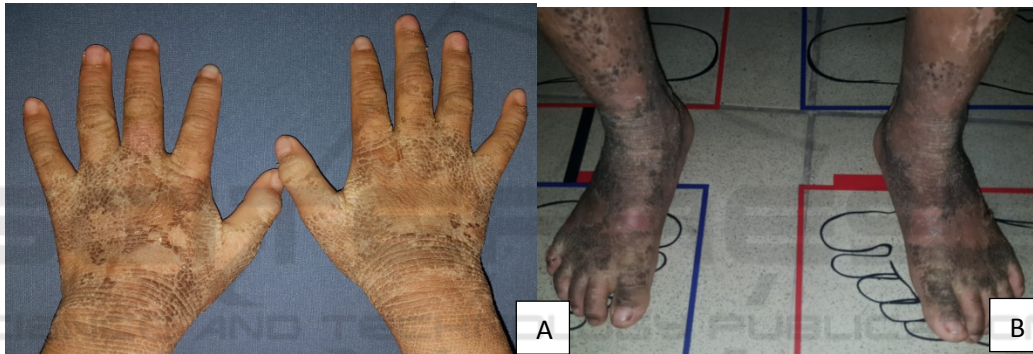

Figure 3. Clinical manifestation. A,B. Dirty brown, cobblestone, hyperkeratotic plaques over the posterior of hand and feet

Histopathology from an area of hyperkeratosis on his left knee showed massive hyperkeratosis, acanthosis of stratum malpighi, spongiosis, lysis and clumping of keratinocytes in the stratum spinosum to stratum granulosum. Lymphocytic cells are seen around blood vessels. The findings were consistent with EHK. (Figure 4 A-C)

On the basis of clinical and histopathological feature epidermolytic hyperkeratosis was diagnosed. The patient was treated with vaseline, coconut oil for scalp, and antiseptic soap. The patient was consulted to paediatrician, ophthalmologist and dentist.

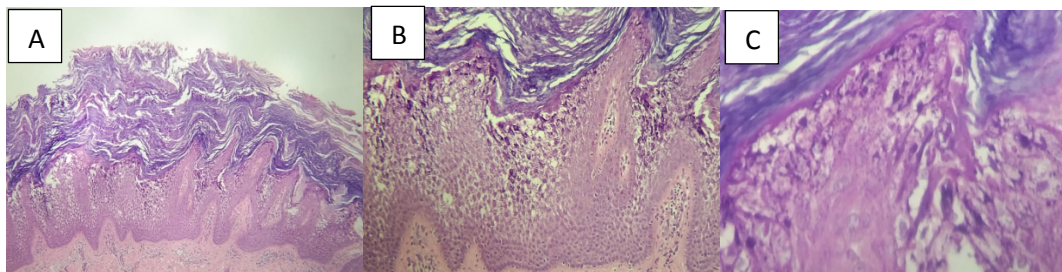


Figure 4. Routine histopathology (haematoxylin-eosin) revealed massive hyperkeratosis, acanthosis, and spongiosis (A,B) and lysis and clumping of hyperkeratocytes (C)

3 DISCUSSION

Our case was presented with classical symptoms and signs of EHK: dirty brown, corrugated hyperkeratotic plaques distributed all over the body, with history of trauma-related blistering a few day after birth that decrease by the age only to be subsequently replaced by malodorous hyperkeratosis. This clinical description is characteristic. Brocq first described EHK in 1902, and coined the term bullous ichthyosiform erythroderma, to distinguish it from the non-blistering condition, congenital ichthyotic erythroderma. It starts at birth with generalized erythroderma, blisters, and peeling with even mild trauma, leading to superficial ulcerations. As the child grows, the erythroderma and blisters decrease, and the hyperkeratosis increase. The distinct foul odor is caused by the bacterial colonization of the macerated scales.³

From anamnesis we found that parents were not affected and so were the rest of the family. He is the only child of healthy and non-consanguineous parents. This disease is mostly inherited as an autosomal dominant trait, albeit 50% of cases result from spontaneous mutations, and recently an autosomal recessive inheritance has been reported. Mutations in keratin 1 and 10 encoding genes, localized on chromosome 12 and 17, respectively, are responsible for EHK. Mutations in keratin 1 encoding gene are associated with severe palmoplantar keratoderma, while mutations of keratin 10 encoding gene are not.⁵The lack of palmoplantar involvement in this case suggested that keratin 10 could be involved.

The histopathologic features of our patient is consistent with epidermolytic hyperkeratosis with massive hyperkeratosis, acanthosis, spongiosis, lysis and clumping of keratinocytes in the stratum spinosum to spinosum. The typical histopathologic features of EHK, which were first described by Nikolsky in 1897, include acanthosis, marked hyperkeratosis, coarse keratohyalin granules, and multiple perinuclear vacuoles present in the upper spinous layer. Clumping of keratin intermediate filaments at the suprabasal level can be visualized by means of electron microscopy, while immunohistochemistry can show a defect in the expression of keratin 1 and/or 10.⁵A diagnosis of EHK is usually made clinically, and can be confirmed by the presence of typical histopathological features.

During childhood, EHK can be differentiated from congenital recessive X-linked ichthyosis on the

basis of the history of blistering and histological findings. Epidermolytic palmoplantar keratoderma is limited to the palms and soles, whereas ichthyosis bullosa of Siemens lacks erythroderma, localization of dark grey hyperkeratosis to the flexural sites, and areas of peeling of the skin known as the "Mauserung phenomenon".^{5,6} Ichthyosis-like Curth-Macklin type patients may look like EHK patients, but there is no clinical or histological evidence of blister formation.⁵

The patient was treated with vaseline and coconut oil for thick scales on his scalp, and antiseptic soap to minimize the foul odor. The patient was consulted to paediatrician to evaluate the delayed speech and his general growth and development, and also to ophthalmologist to evaluate the involvement of eyes. To evaluate whether he had dental dysplasia or not, the patient was also consulted to dentist. Follow up after one month showed improvement in the hyperkeratotic plaques and the malodor. Consultations to paediatrician, ophthalmologist and dentist have been done. There were no abnormalities on his eyes and no dental dysplasia. The delayed speech was probably caused by multilingual parents and is not associated with the disease.

Initial treatment early in disease is targeted towards symptomatic relief and management of the secondary complications of the erosions.^{5,7,8} These complications include electrolyte imbalance, dehydration, infection, and sepsis, especially in neonates with blisters and erosions. Erosions need to be managed meticulously with barrier protection and gentle handling of the skin to minimize the development of secondary infection. Bacterial overgrowth, particularly from *Staphylococcus aureus*, and an odor can develop as a result of scale accumulation, which may be controlled with chlorhexidine or antibacterial cleansers.^{5,7,8} Later in disease, emollients as well as topical and systemic retinoids can be considered. Topical emollients are considered mainstay therapy, as well as creams or ointments that possess keratolytic properties to reduce the hyperkeratosis scale that develops in these patients. Examples include urea, alpha-hydroxy acids, lactic acid, and glycerin, although lactic acidosis is a concern with topical lactic acid in infants and small children.

For more severe cases, oral and topical retinoids have also been shown to improve the skin condition, although retinoids may promote desquamation and exacerbate blistering. For unknown reasons, individuals with keratin 10 gene mutations respond better to topical or systemic retinoid therapy, as

compared to those with keratin 1 gene mutations.⁵ Although indicated, we didn't give retinoids in this patient due to a lack of availability in Indonesia. After one month followed up, parents reported improvement, so we decided to continue the current therapies.

Education is important in this case. After genetic counseling, we gave the parents and family information about high protein diet, patient hygiene in order to prevent secondary infection and minimized malodor, and also how to keep the patient from overheating because in patients with ichthyosis, sweating is often inadequate owing to the occlusion of eccrine ducts. Affected individuals should be guarded against overheating during winter months and kept in air-conditioning during warmer months, with frequent wetting of the skin or even cooling suits during sports activities.⁹

For the prognosis, widespread blistering clears after newborn period while the hyperkeratotic scale usually lifelong. Generalized involvement may improve to localized disease after puberty.

4 CONCLUSION

Epidermolytic hyperkeratosis is rare and has a challenging differential diagnosis. Nevertheless, it is important for clinicians to identify the disease early in order to reduce morbidity and mortality.

REFERENCES

- Fleckman P, DiGiovanna JJ, Elder JT. The Ichthyoses. In: Goldsmith LA, Katz SI, Gilchrist BA, Paller AS, Leffell DJ, Wolff K, Eds. Fitzpatrick's Dermatology in General Medicine. 8th Ed. New York: McGrawHill; 2012. p.507-38.
- Spitz, Joel L. Genodermatoses: A Clinical Guide to Genetic Skin Disorders. 2nd Ed. Philadelphia: Lippincott Williams & Wilkins; 2005. p. 6-9.
- Hayashida MT, Mitsui GL, Reis NI, Fantinato G, Neto DJ, Mercante AMC. Epidermolytic Hyperkeratosis - case report. *An Bras Dermatol*. 2015;90(6):888-91.
- Pan K, Chakrabarti S, Choudhury R, Sarkar A, Mitra R. Epidermolytic hyperkeratosis: a rare case. *Int J Res Med Sci*. 2014 Feb;2(1):347-9.
- Alshami M, Mohana M, Alshami A. Epidermolytic Hyperkeratosis: A Case Report from Yemen. *Invest Dermatol Venerol Res*. 2016;2(1):61-3.
- Charlene U, Ang-Tiu, Marie Eleanore O, Nicolas. Ichthyosis bullosa of Siemens. *J Dermatol Case Rep*. 2012; 6(3):78-81.
- Siavash M, Shanehsaz, Bittar R, Anis A, Ishkhanian S. Bullous ichthyosiform erythroderma: case presentation.

- Journal of Pakistan Association of Dermatologists*. 2014;24 (1):86-8.
- Millsop JW, Sivamani RK, Lee DC, Konia T, Subramanian N and Fung MA. A Case of Bullous Congenital Ichthyosiform Erythroderma, a Rare Pediatric Genodermatosis, in a Newborn. *Austin J Dermatol*. 2014;1(4):1016.
- Paller A, Mancini AJ. Hurwitz clinical pediatric dermatology: A textbook of skin disorders of childhood and adolescence. 5th ed. New York: Elsevier/Saunders; 2016.