

Nevus Comedonicus, a Rare Case: Dermoscopic and Histopathological Findings

Adniana Nareswari^{1*}, Mardiana¹, Nugrohoaji Dharmawan¹, Oyong²

¹*Dermatovenereology Department Medical Faculty of Sebelas Maret University/ Dr. Moewardi General Hospital, Surakarta, Indonesia*

²*Pathology Anatomy Department Medical Faculty of Sebelas Maret University/ Dr. Moewardi General Hospital, Surakarta, Indonesia*

Keywords: Nevus, nevus comedonicus, adnexal hamartoma.

Abstract: Nevus comedonicus is a very rare adnexal hamartoma of pilosebaceous apparatus, with approximately 200 cases reported in the literature so far. It appears as cluster of adjacent dilated follicular openings with firm pigmented keratin plugs resembling comedones. The comedones oftentimes arranged in linear or zosteriform pattern, paralld to Blaschko's lines. The lesions are commonly unilateral, although bilateral occurrence have been reported. The predilection sites are face, neck, upper arms, chest and abdomen. We report a case of a 5-year-old boy with open brown to black comedones in a linear pattern localized on the back of the left thigh that appearing since birth. The lesions gradually increased in number and size. The plugs were firm and difficult to be extracted mechanically, leaving a big pore on the skin. Pain, itch and discharge were not obtain. There were some episodes of infection, due to manual removal done by his mother which left some hypertrophic scars. The patient was otherwise healthy, without any congenital abnormalities, extracutaneous lesion, and internal involvement. Dermoscopic examination revealed the distinctive pattern consisting of pigmented, sharply demarcated keratin plugs of 1-3 mm in diameter, some open pores, multiple structurless, various shades of brown homogenous circular areas surrounding the plugs. Punch biopsy of the lesion histologically showed an aggregation of dilated follicular infundibulum with laminated keratinous material plugging. The follicular walls were comprised of several keratinocyte layers. Based on the history taking, typical features of the lesion, dermoscopic and histopathological findings, this patient was then diagnosed with nevus comedonicus.

1 INTRODUCTION

Nevus comedonicus is an extremely rare developmental abnormality of the pilosebaceous unit, which presenting as a constellation of dilated follicular orifices filled with dark keratinous plugs. It was first described as 'comedo nevus' (Kofmann,1895). Its prevalence has been estimated from 1 in 45,000 to 1 in 100,000, affecting any race and gender (Kaliyadan,2017). Retrospective study conducted in Mexico City from 1971 to 2001, among 417,511 paediatric patients , 443 displayed epidermal naevi, but only 5 of them diagnosed as nevus comedonicus (Vidaurri,2004). In Indonesia itseft, there is no data on nevus comedonicus prevalence.

The diagnosis of nevus comedonicus is relatively easy. It has a typical and different feature compared

to other epidermal nevi. Dermoscopy, a safe non-invasive easy-to-repeat diagnostic method mainly used in melanocytic lesion helps in establishing the diagnosis of nevus comedonicus (Winciorek,2011). However the use of this tool is rare, and only a few reports has been published regarding its use. A typical histopathological feature confirms the diagnosis in uncertain case.

This study aimed to present a rare case of nevus comedonicus with regard to its clinical, dermoscopic, histopathological features and the use of dermoscopy in this rare condition.

2 CASE

A 5-year-old Indonesian boy presented to our outpatients clinic, Dermatovenereology Department,

dr. Moewardi General Hospital, Surakarta, Indonesia for evaluation of open brown to black, firm and protude comedones, localized to the back of his left thigh in a linear pattern along Blaschko's lines (Figure 1), which has occurred since birth. His mother reported that the lesions gradually increased in number and size with time. The patient ever been evaluated in our hospital when he was 1 month old. At that time he received various topical treatments but there was no satisfactory improvement.

The parents took him again to our outpatient clinic after years due to their concern about this asymptomatic lesion which became increased in number and size. There were no complaints of pain, itch and discharge. His mother tried to remove the plugs herself which left a big pore on the skin and caused some episodes of infections. Though it healed, it left some hypertrophic scars. Medical history was unremarkable with no similar complaint in his family. The parents denied for consanguinity. Pregnancy and labor were uneventful. The mother also denied for any drug consumption during pregnancy.

Clinical examination on his back of the left thigh revealed multiple, comedo-like openings with brown to black, firm keratin plugs dispersed over a hypopigmented, linear spot of 20 cm x 4 cm, with some hypertrophic scars on it. His vital signs, body weight and height were normal for his age. There was no other cutaneous findings on the other part of body.

Ophthalmological and neurological examinations did not reveal any abnormality. Laboratory findings (complete blood count, liver functions and kidney functions) were unremarkable. The dermoscopic revealed the distinctive pattern consisting of pigmented, sharply demarcated keratin plugs of 1-3 mm in diameter, some open pores, multiple structurless, various shades of brown homogenous circular areas surrounding the plugs (Figure 2A). A 3 mm punch biopsy was obtained from his back of the left thigh. Histopathological examination showed an aggregation of dilated follicular infundibulum with laminated keratinous material plugging. The follicular walls were comprised of several layers of keratinocytes. Epidermis was within normal limit (Figure 2B). This patient was diagnosed with nevus comedonicus based on the history taking, clinical examination which pictured the typical lesion of nevus comedonicus, dermoscopic and histopathological finding.

3 DISCUSSION

Nevus comedonicus is an extremely rare dermatological problem with an estimated occurrence of 1 case in every 45,000–100,000 individuals (Kaliyadan,2017). A study by Inoue et al., reported that there were only 200 cases until the year of 2000 (Inoue,2000). A retrospective study conducted in Mexico City from 1971 to 2001, among 417,511 paediatric patients, 443 displayed epidermal naevi, but only 5 of them diagnosed as nevus comedonicus (Vidauri,2004). There has not been any data about the prevalence or even the case report of nevus comedonicus in Indonesia so far.

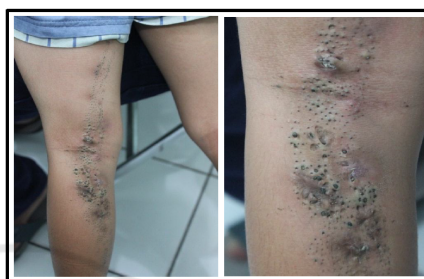

Figure 1. Nevus comedonicus on the back and left thigh. A cluster of firm, pigmented, protrude comedo-like papules in a linear pattern along Blaschko's line.

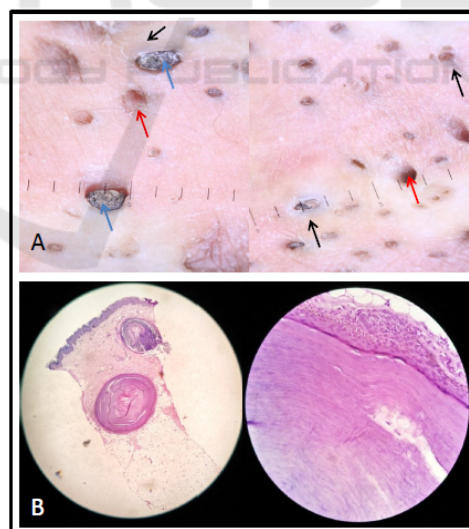


Figure 2. A: Dermoscopy of nevus comedonicus. Multiple dilated follicular openings (red arrow) with pigmented keratin plugs 1-3 mm in diameter (blue arrow) and structurless, various shades of brown homogenous circular areas surrounding the plugs (black arrow). B: Histopathology of nevus comedonicus. Laminated keratinous material plugging on dermis and epidermis within normal limit. The follicular walls are comprised of several keratinocyte layers.

Approximately 50% of nevus comedonicus cases appear at birth, with the other 50% developed symptoms during childhood, usually before the age of 10 years. There is no predilection for race or gender (Pierson,2003).

Clinically, nevus comedonicus present as a collection of discrete, dilated follicular ostia plugged with horny brown to black pigmented keratin. The lesions are most commonly found on face, neck, upper arms, chest and abdomen, usually arranged in groups, bands, or in a linear pattern along Blaschko's lines (Solomon,1975). Normally it is unilateral but can be bilateral in certain case (Mahran,2017). Nevus comedonicus is classified into two groups, reflecting the severity of the condition: the first group is characterized by the presence of slightly pronounced skin lesions or comedo-like changes, which represent only a cosmetic defect, the second one presents with severe cutaneous symptoms including large cysts with scarring, often with a tendency to recurrence with the formation of fistulas and abscesses (Guldbakke,2007). Nevus comedonicus in unusual cases, may appear as an extensive inflammatory lesion involving large areas of the body, with inflammation and residual scarring (Kirtak,2004).

Several disorders have been known to be associated with nevus comedonicus. Cases showing any of these findings are included in nevus comedonicus syndrome, an entity considered within the larger group of epidermal nevus syndrome. Nevus comedonicus syndrome is characterized as a combination of nevus comedonicus with ocular defect (cataracts, corneal erosion), skeletal defect (syndactily, clinodactily, preaxial polydactily, absence of a ray of hand bones, scoliosis, vertebral defects) and neurologic defect (microcephaly, mental deficiency, dysgenesis of corpus callosum) (Happle,2010). In our patient, the nevus comedonicus present alone without any other cutaneous or extracutaneous lesion and also no abnormalities found in ophthalmological and neurological examination.

In our patient, the dermoscopic examination revealed the distinctive pattern consisting of dark, sharply demarcated keratin plugs of 1-3 mm in diameter, some open pores, numerous structureless, circular and barrel shaped, homogenous areas with hyperkeratotic plugs of various shades of brown. These features were suggestive of nevus comedonicus. Winciorek and Spiewak defined dermoscopic features of nevus comedonicus as numerous circular and barrel-shaped homogenous areas in light and dark-brown shades with

remarkable keratin plugs (Winciorek,2013). Dermoscopy as a diagnostic tool is safe, non-invasive and easy-to-repeat procedure which is mainly used in melanocytic lesion. Its also helpful in diagnosing nevus comedonicus (Winciorek,2011). However, the use of this diagnostic tool has not been widely applied, only two reports have been published (Winciorek,2013) (Vora,2017). Dermoscopy is useful in differentiating nevus comedonicus from comedones of acne and other rare epidermal nevi, such as sebaceous nevus and hair follicle nevus. Comedones of acne vulgaris show numerous, homogenous areas, light and dark-brown, sometimes black in color, depending on the type of acne, open or closed comedones, predominantly circular and situated superficially on dermoscopy. Sebaceous nevus shows bright, yellow spot which are not associated with hair follicles. Many follicular openings and interfollicular "pseudo-pigment network" on dermoscopy characterized hair follicle nevus (Okada,2008).

Histopathological examination of nevus comedonicus demonstrate a wide, deep invagination of the epidermis filled with keratin. These invaginations resemble dilated hair follicle; in fact, as evidence that they actually represent rudimentary hair follicles, occasionally found in the lower portion of an invagination one or even several hair shafts (Elder,2009). These similar with histological findings of our patient. Histologically it is important to differentiate it with comedonal acne. In comedonal acne, the pilosebaceous units are complete whereas those in nevus comedonicus are poorly formed. Furthermore in nevus comedonicus, hyperkeratosis and papillomatosis are frequently seen in the interpapillary epidermis and absent in comedonal acne. Dilated pore of Winer can sometimes be confused with nevus comedonicus histologically. However, this condition is usually observed in the elderly and can be differentiated clinically.

Clinical findings themselves can be used to establish the diagnosis of nevus comedonicus as the diagnosis of nevus comedonicus is predominantly clinical. The differentiation of nevus comedonicus from other epidermal nevi is easy as the former shows presence of "comedones", which on extraction will leave a big pore on the skin surface. The finding of groups of lesions paralleled to Blaschko's lines ruled out comedonal acne. In the majority of cases, dermoscopy may prove helpful while biopsy is only indicated in uncertain cases.

4 CONCLUSION

Diagnosing nevus comedonicus is relatively easy, however clinician should be aware of the potential association of nevus comedonicus with other cutaneous lesion and extracutaneous features, such as ocular, skeletal and neurologic abnormalities as nevus comedonicus syndrome. Furthermore, our case report shows a typical feature and dermoscopic findings of nevus comedonicus which is rarely described in literature. This case report also prove that dermoscopy examination, a simple non-invasive diagnostic tool is very helpful in diagnosing nevus comedonicus. We recommend this tool to differentiate the diagnosis of other rare epidermal nevi, such as sebaceous nevus and hair follicle nevus while histopathological examination should be performed only in uncertain cases.

REFERENCES

- Elder, D.E., Elenitsas, R., et al., 2009. Lever's Histopathology of The Skin. 10th re. Ed. Lippincott Williams & Wilkins. P.793. Happle R. 2010. The group of epidermal nevi syndrome Part I - Well defined phenotypes. *J Am Acad of Derm.* Vol 63: 1-23.
- Guldbakke, K. K., Khachemoune, A., Deng, A., & Sina, B., 2007. Naevus comedonicus: a spectrum of body involvement. *Clinical and Experimental Dermatology: Clinical dermatology*, 32(5), pp. 488-492.
- Inoue, Y., Miyamoto, Y., & Ono, T., 2000. Two cases of nevus comedonicus: successful treatment of keratin plugs with a pore strip. *Journal of the American Academy of Dermatology*, 43(5), pp. 927-929.
- Kaliyadan, F., & Bhimji, S., 2017. Nevus comedonicus; in StatPearls. Treasure Island, StatPearls Publishing.
- Kirtak, N., Inaloz, H. S., Karakok, M., Erguven, H. G., & Ozgoztasi, O., 2004. Extensive inflammatory nevus comedonicus involving half of the body. *International journal of dermatology*, 43(6), pp. 434-436.
- Kofmann, S., 1895. A case of rare localization and spreading of Comedones. *Arch Dermatol Syphilol*, 32, 177-178.
- Mahran, A.M., Abdelsamea, G.M., Mekkawy, M.M., 2017. Bilateral nevus comedonicus successfully treated with topical adapalene: a case report. *Clinical Dermatology Journal*, Vol 2 issue 6.
- Okada, J., Moroi, Y., Tsujita, J., et al., 2008. Hair follicle nevus – a dermoscopic approach. *Eur J Dermatol.* 18: 185-7. Pierson D, Bandel C, Ehrig T et al. 2003. Benign epidermal tumors and proliferations. In: *Dermatology* (Bologna JL, Joseph LJ, Rapini RP, eds). London: Mosby. 1712–1713.
- Solomon, L. M., & Esterly, N. B., 1975. Epidermal and other congenital organoid nevi. *Current problems in pediatrics*, 6(1), 3-56.
- Vidaurri-de la Cruz, H., Tamayo-Sánchez, L., Durán-McKinster, C., De La Luz Orozco-Covarrubias, M., & Ruiz-Maldonado, R., 2004. Epidermal nevus syndromes: clinical findings in 35 patients. *Pediatric dermatology*, 21(4), 432-439.
- Vora, R. V., Kota, R. S., & Sheth, N. K., 2017. Dermoscopy of Nevus Comedonicus. *Indian dermatology online journal*, 8(5), pp. 388-388.
- Winciorek, G.K., & Śpiewak, R., 2011. Basic dermoscopy of melanocytic lesions for beginners. *Postępy Hig Med Dośw (Online)*. 65, p. 501-508.
- Kamińska-Winciorek, G., & Śpiewak, R., 2013.. Dermoscopy on nevus comedonicus: a case report and review of the literature. *Advances in Dermatology and Allergology/Postępy Dermatologii i Alergologii*, 30(4), 252-254.