

Hair Shaft Alteration in Children Undergoing Chemotherapy

Reti Anggraeni, Ardelia Dyah Ayu, M. Eko Irawanto, Suci Widhiati, Muhammad Riza
Faculty of Medicine Sebelas Maret University/ Dr. Moewardi General Hospital, Surakarta

Keywords: alteration, chemotherapy, hair shaft

Abstract: Hairs have no vital function but it may use as an indicator for the human's health. Hair shaft is a unique structure which composed of inner cortex and protective outer cuticle. Hair shaft disorders may be inherited or acquired, as in a local or systemic disease. One of the acquired causals is chemotherapy. Chemotherapy agent can damage the structure or morphology of the hair including hair shaft pattern. Cross sectional analytical study was conducted in Dr. Moewardi General Hospital Surakarta. Forty five subjects, aged 1-14 years old were enrolled. The study subjects (n=30) were pediatric patients undergoing chemotherapy, the control group (n=15) comprised of children who never had chemotherapy. Of the 30 subjects from study group, 27 (90%) had altered hair shaft. Two (13.3%) of fifteen children in control group had hair shaft alteration. Statistical analysis using Mann-Whitney U Test obtained $p=0.000$ which means there was a significant different between incidents of hair shaft alteration between children undergoing chemotherapy and children never had chemotherapy. Further study is needed to describe more about the most common group of chemotherapeutic agents which cause the alteration and the relation between the type of cancer and hair shaft alteration.

1 INTRODUCTION

Humans have over 2 million hair follicles, which may have significant positive and negative influences on skin health.(McElwee and Sinclair, 2008) The hair shaft is protected by the cuticle layer with its overlapping cells which resemble shingle on its roof. If there is damage in cuticle, the exposed hair cortex is still bonded but it is more susceptible to environmental damages and fractures.(yu et al., 2006; Mirmirani et al., 2011)

The most common treatment performed for cancer is chemotherapy. It has adverse side effects to healthy tissue and organs including the hair. It affects the hair in two mainly parts, the hair growth and the hair shaft. About 65% of patients undergoing chemotherapy will get chemotherapy-induced hair loss (chemotherapy-induced alopecia), known as anagen effluvium, which is usually reversible when the therapy ends.(Trüeb, 2010)

Chemotherapy may also affect the structure and morphology of the hair leading to the damage of the hair follicle and later causing hair shaft alteration.(Lindner et al., 2012) The alteration of hair shaft reveals in many patterns caused by diminishing of the follicle function, such as fractured hairs,

narrowings (the most common is Pohl-pinkus constriction), node-like appearance, curls and twist hairs, short hairs and disorders on the band hair.

There have been many studies about anagen effluvium due to chemotherapy agent but there are only a few studies about hair shaft alteration. Therefore we performed this study to reveal whether chemotherapy may cause the hair shaft alteration. Thus when we have patients undergoing chemotherapy, especially with altered hair, we can give more education supports. As it would be a psychologically problem leading to negative impact on their perceptions of appearance.

2 METHODS

Cross sectional analytical study was conducted in pediatric ward of Dr. Moewardi General Hospital Surakarta between December 2017 and January 2018. Forty five subjects, aged 1-14 years old were enrolled in our study by using consecutive sampling method. The study subjects (n=30) were pediatric patients undergoing chemotherapy and the control group (n=15) comprised of children who never had chemotherapy. Each subject's scalp was

photographed by using dermoscope, 20 hairs were removed, put under object glass and examined under microscope. The photograph and microscopic features were interpreted by three observers.

3 RESULTS

Of the 30 study subjects, there were 27 (90%) had hair shaft alteration whereas the control group 2 (13.3%) of 15 subjects experienced altered hair shaft (Figure 1).

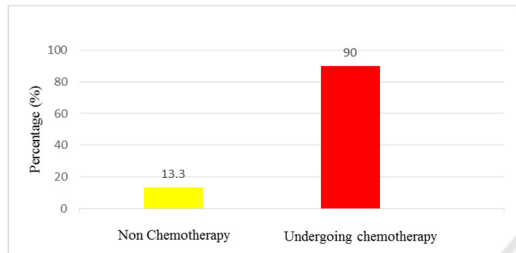


Figure 1. The percentage of the hair alteration of the enrolled subjects

Table 1. The hair shaft alteration of study subject compared to control group

Study Subject (n=30)	Total	Percentage (%)
Altered	27	90
No-alteration	3	10
Control (n=15)		
Altered	2	13.3
No-alteration	13	86.7

This present study used Mann-Whitney U Test ($p=0.000$) which revealed that there was a significant difference of hair shaft alteration between children undergoing chemotherapy and children never had chemotherapy.

The demographic characteristic (Table 2) obtained that the diagnosis of acute lymphoblastic leukemia (ALL) was the most common cancer (30%, n=9) followed by osteosarcoma (16.8%, n=5). The chemotherapy agents was varied, used as a single or combination therapy. The most chemotherapy agent combination used was methotrexate and vincristine (36.8%, n=11) while the single therapy was mostly cyclophosphamide (10%, n=3).

Of the 27 altered hair shaft subjects, there were many patterns with the most common pattern was Pohl-pinkus (n=9) followed by hair cast node-like appearance (n=3) (Figure 2).

4 DISCUSSION

The hair consist of two distinct structures, the hair follicle, the living part located under the skin, and the hair shaft which is fully keratinized nonliving part above the skin surface. The follicle is the essential growth structure of the hair and basically has two main parts, upper part consists of infundibulum and isthmus whereas the lower part comprise of hair bulb and suprabulbar region.(Berker et al., 2012) The hair shaft has three layers: cuticle, cortex and medulla.(Berker et al., 2012; McElwee and Sinclair, 2008) Hair has no essential function but if there is a damage it leads to hair loss or even the alteration of hair shaft. The individual will have a psychosocial problem related to his/ her physical performance.

Table 2. Demographic characteristics of study subjects

	Total (n=30)	Percentage (%)
Age (year)		
0 – 5	14	46.7
6 – 11	12	40
12 – 17	4	13.3
Diagnosis		
Acute Lymphoblastic Leukemia	9	30
Osteosarcoma	5	16.8
Acute Myeloid Rhabdomyosarcoma	3	10
Trombositopenia Systemic Lupus Erythematosus	2	6.7
Nephtiris Lupus	2	6.7
Retinoblastoma	1	3.3
Nephroblastoma	1	3.3
Pheochromocytoma	1	3.3
Genu Cell Tumor	1	3.3
Carcinoma Testis	1	3.3
Nephrotic Syndrome	1	3.3

Chemotherapy Agent		
Methotrexate + vincristine	11	36.8
Etoposide + carboplatin	8	26.7
Cyclophosphamide	3	10
Doxorubicin + vincristine + cyclophosphamide	2	6.7
Ifosfamide + etoposide	1	3.3
Cyclophosphamide + metilprednisolone	1	3.3
Methotrexate + doxorubicin	1	3.3
Etoposide + bleomycine + vincristine	1	3.3
Cisplatin + bleomycine + vincristine	1	3.3
Vincristine	1	3.3

One of the causal factors for hair disorder is chemotherapy which is the most common treatment for cancer. The chemotherapeutic agents either use as single or combination regimen may damage the follicle function of the hair which later will destroy the growth of the hair shaft appearing to the skin surface. Firstly hair loss which can be seen within days to weeks of the initiation of chemotherapy and complete loss occurs in 3 months later. In 60% cases after the hair loss, patients experiencing differences in hair color, alteration in thickness, texture or waviness of their regrowth hair in 1 to 3 months after chemotherapy ends.(Kanwar and Narang, 2013; Kanti et al., 2014)

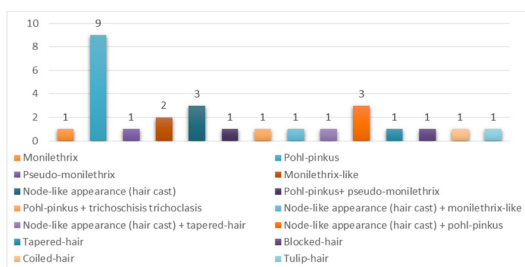


Figure 2. The varieties of hair shaft patterns of the 27 altered hair shaft subjects

The alteration of the hair after hair loss occurs the shape of the hair shaft. As the hair follicle is surrounded by dense of capillaries network, growing hair is sensitive to metabolic imbalances resulted

from internal disease, local inflammation or drug-side effects.(Rogers, 1995; Tosti and Pazzaglia, 2007) This remains unclear why chemotherapy agents may lead to the alteration of hair shaft.(Trüeb, 2010)

The hair shaft alteration reveals in many patterns consisting of fractured hairs (trichoptilosis, trichoschisis or trichoclasia, broken (fractured) hairs and golf tee hairs), narrowings (monilethrix, monilethrix-like congenital hypotrichosis, monilethrix-like hairs or Pohl-pinkus constriction, pseudomonilethrix, exclamation mark hairs and tapered hairs), node-like appearance (trichonodosis, trichorrhexis nodosa, trichorrhexis invaginata and hair casts), curls and twist hairs (pigtail, coiled, comma, corkscrew, zigzag, pili torti and wooly hairs), short hairs (upright regrowing, vellus hairs, dark lines, tulip hairs, block hairs, i-hairs, broom hairs, broom fibers and flame hairs) and disorders on the band hair (continuous or interrupted medulla, pilli annulati, and interrupted hairs).(Itin and Fistarol, 2005; Tosti and Piraccini, 2006; Rudnicka et al., 2012) The most common alteration is Pohl-pinkus constriction in which its morphological change occurs in the hair roots.(Williamson and de Berker, 2005) De Berker et al stated that the monilethrix pattern caused by cortical defect resulting in a disorientation of the fibrils which lie along the cortical cells.(Rogers, 1995) Another study by Ito et al suggests that the basic cause of the monilethrix alteration is malfunction of the germinative cells of the hair matrix leading to abnormalities affecting the cuticle, internal sheath and mostly affects the cortex.(Ito et al., 1990) There is an intermediate state whereas the follicle function decreases but does not stop the hair fibre production, therefore there is a short span along the hair of diminished bore.(Williamson and de Berker, 2005)

In the present study, we found that there was 27 (90%, total n=30) in study subjects got hair shaft alteration and only 2 (13.3%, total n=15) in the control group had altered, as it is seen by the result of Mann-Whitney test with $p < 0.05$ ($p = 0.000$) which means that there was a significant difference of hair shaft alteration between children undergoing chemotherapy and children never had chemotherapy. Of the 27 study subjects who had altered, there was many varieties of patterns. The most common pattern was Pohl-pinkus constriction (n=9), followed by node-like appearance hair cast (n=3) and Pohl-pinkus constriction combined with node-like appearance hair cast (n=3).

A further study is required to determine the most common group of chemotherapeutic agents which may cause hair shaft alteration and the relation

between the type of cancer and the hair shaft alteration.

5 CONCLUSIONS

Children undergoing chemotherapy experienced a significant hair shaft alteration. This suggests that chemotherapy may damage the hair structure leading to the alteration of hair shaft. The most common pattern of the hair shaft alteration in our study was Pohl-pinkus constriction.

REFERENCES

- Berker, D.D., Higgins, C.A., Jahoda, C., Christiano, A.M. 2012. *Biology of hair and nails*. In: Bologna Dermatology 3rd Edition. Bologna JL, Jorizzo JL, Schaffer JV, editors. United States: Elsevier Saunders Ltd.; 2012. p. 1075-92.
- Itin, P.H., Fistarol, S.K., 2005. Hair shaft abnormalities - Clues to diagnosis and treatment. *Dermatology*.
- Ito, M., Hashimoto, K., Katsuumi, K., Sato, Y., 1990. Pathogenesis of monilethrix: Computer stereography and electron microscopy. *Journal of Investigative Dermatology* 95, 186–194.
- Kanti, V., Nuwayhid, R., Lindner, J., Hillmann, K., Stroux, A., Bangemann, N., Kleine-Tebbe, A., Blume-Peytavi, U., Garcia Bartels, N., 2014. Analysis of quantitative changes in hair growth during treatment with chemotherapy or tamoxifen in patients with breast cancer: A cohort study. *British Journal of Dermatology* 170, 643–650.
- Kanwar, A., Narang, T., 2013. Anagen effluvium. *Indian Journal of Dermatology, Venereology, and Leprology* 79, 604.
- Lindner, J., Hillmann, K., Blume-Peytavi, U., Lademann, J., Lux, A., Stroux, A., Schneider, A., Garcia Bartels, N., 2012. Hair shaft abnormalities after chemotherapy and tamoxifen therapy in patients with breast cancer evaluated by optical coherence tomography. *British Journal of Dermatology* 167, 1272–1278.
- McElwee, K.J., Sinclair, R., 2008. Hair physiology and its disorders. *Drug Discovery Today: Disease Mechanisms*.
- Mirmirani, P., Huang, K.P., Price, V.H., 2011. A practical, algorithmic approach to diagnosing hair shaft disorders. *International Journal of Dermatology*.
- Rogers, M., 1995. Hair shaft abnormalities: Part I. *Australasian Journal of Dermatology* 36, 179–184.
- Rudnicka, L., Olszewska, M., Rakowska, A. 2012. *Atlas of Trichoscopy*. New York: Springer.
- Tosti, A., Piraccini, B.M. 2006. *Diagnosis and Treatment of Hair Disorders*. Great Britain: CPI.
- Tosti, A., Pazzaglia, M., 2007. Drug Reactions Affecting Hair: Diagnosis. *Dermatologic Clinics*.
- Trüeb, R.M., 2010. Chemotherapy-induced alopecia. *Current Opinion in Supportive and Palliative Care* 4, 281–284.
- Williamson, P.J., de Berker, D., 2005. Pohl-Pinkus constrictions of hair following chemotherapy for Hodgkin's disease. *British Journal of Haematology* 128, 582–582.
- yu, M., Finner, A., Shapiro, J., lo, B., Barekatin, A., Mcelwee, K.J., 2006. Hair follicles and their role in skin health. *Expert Review of Dermatology* 1, 855–871.