

The Effect of Pakoasi (*Chromolaena odorata L.*) Leaf Extract in Curing Open Wound of Rabbit Skin (*Oryctolagus cuniculus*)

F. Ramdani¹, M. Sriasih², A. S. Dradjat²

Postgraduate student at Magister Program (Manajemen Sumber Daya Peternakan) of Animal Science Faculty, University of Mataram. Jalan Majapahit No. 62 Mataram, NTB

² Faculty of Animal Science, University of Mataram, Jl. Majapahit No. 62 Mataram, NTB

Keywords: Open Wound, Pakoasi, Rabbit

Abstract: Pakoasi (*Chromolaena odorata L.*) is a weed that is often used in treating wounds, but its effectiveness has not been widely studied. The purpose of this research was to evaluate the effect of Pakoasi leaf extract on open wound healing process in rabbit. Twenty healthy male rabbits were wounded with diameter of 2 cm under local anaesthesia, and were divided into four groups: G0 (placebo), G1 (treated with 10% extract), G2 (treated with 20% extract) and G3 (positive control). Macroscopic and microscopic observations were carried out, and the obtained data were analysed using analysis of variance. The macroscopic results showed that on day 4, there was a significant difference ($p < 0.05$) of wound diameter among groups, with G1 showing the shortest wound diameter (1.78 ± 0.08 cm). Seventeen days after treatment, the wound diameter (cm) in G1, G2, G3 and G0 were 0 ± 0 ; 0.08 ± 0.04 ; 0.17 ± 0.06 and 0.35 ± 0.08 , respectively. The complete healing process of open wound occurred as fast as 16 days after treatment in G1 based on macroscopic and microscopic observation. This study concluded that ointment containing 10% of pakoasi extract is effective for curing open wound.

1 INTRODUCTION

Pakoasi (*Chromolaena odorata L.*) is a weed belongs to *Compositae* family. This weed is easy to grow, widespread and fast in tropical areas (Madhavan, 2015) so that grassland cannot be overgrown with grass. Some societies in West Nusa Tenggara commonly use pakoasi as a traditional medicine to treat open wounds, burns and other traumas. However, the effectiveness of pakoasi as a traditional medicine has not been widely studied yet.

Previous studies showed that the application of pakoasi leaf extract of 2.5%, 5% and 10% in ethanol has no effect in curing open wound in rabbits (Arif, 2016). The findings might be influenced by the small number of samples, the number of wound made in each rabbit and the absence of microscopic assessment. Hence in this study, we evaluated pakoasi (*C. odorata L.*) leaf extract effectiveness by examining pakoasi ointment (10% and 20%) on the wound healing process in male rabbits (*Oryctolagus cuniculus*) skin. We made macroscopic and microscopic evaluations.

2 MATERIALS AND METHODS

2.1 Leaf Extraction

The pakoasi leaves were removed by breaking the stalk. They were washed thoroughly, dried and powdered. The powder was then extracted with 96% ethanol solution. The process was followed by phytochemical test by gas chromatography-mass spectrometry (GCMS) to evaluate the extract chemical content.

2.2 Ointment Preparation

Ointment containing different concentration of pakoasi extract was prepared as described by Goeswin (2006). The formulation is presented in Table 1.

Table 1 : Component and content of pakoasi ointment.

| No | Component | Pakoasi extract | |
|----|-----------------|-----------------|-----|
| | | 10 % | 20% |
| 1 | Pakoasi Extract | 1 | 2 |

| | | | |
|---|---------------|------|-----|
| 2 | Vaselin Album | 7.65 | 6.8 |
| 3 | Adeps Lanae | 1.35 | 1.2 |
| 4 | Ointment | 10 | 10 |

2.3 Rabbit Skin Incision

Twenty male healthy rabbits were wounded 2 cm in diameter. Before making skin incision, the fur was shaved around 5 cm. The skin was cleaned using 70% alcohol and was then anesthetized using lidocaine. After 5 minutes, a circum incision of 2 cm in diameter was performed on the top of vertebra.

The wounded rabbits were randomly divided into four groups, with each group consisting of 5 rabbits as follows; G1: the wounded rabbit was treated with ointment of 10% pakoasi leaf extract, G2: treated with 20% of pakoasi leaf extract, G3: treated with povidone iodine as a positive control, while G0: no treatment was given as a negative control. The treatment was given twice a day in each group until the wound was completely closed. The observations were done macroscopically on day 4, 11 and 17, and microscopically on day 7 and 21. The results were then analysed by analysis of variance.

3 RESULTS AND DISCUSSION

3.1 Phytochemical Evaluation of *C. odorata* L.

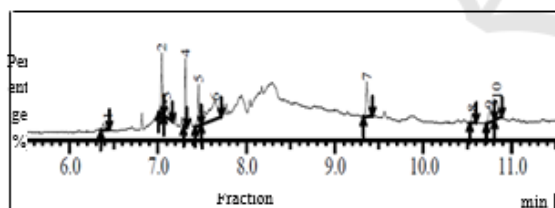


Figure 1: The results of phytochemical test of *C. odorata* L. leaf extract.

Figure 1 shows that there were five main components, showing more than 5%, derived from the extract. Those were Germacrene D (23.86%) and seemed to be the highest content of the extract. Germacrene D is derived from terpenoid as a precursor of hydrocarbons (Nils et al., 2000). Second, Trans (beta) -caryophyllene, which can be classified as terpenoids sesquiterpen (21.07%). The compounds have antimicrobial, antioxidant, anesthetic and anti-inflammatory activities (Ghelardini et al., 2001). Third, Cadinene which is a

class of terpenoids sesquiterpen (14.30%). Sesquiterpene compounds have considerable effects as antimicrobial, antifungal and antibiotic (Ali et al., 2008; Guo et al., 2008). Other component was Hexadecanoic acid (CAS) Palmitic acid (12.07%), a derivative of saponin which has anti-inflammation and antifungal, by damaging the structure of walls and cell membranes of fungi. This synergistic mechanisms is led by various compounds such as terpenoids, which may increase the effect of antifungal activity (Padmin et al., 2010). Last component was Octadecatrienoic acid methyl ester (6.30%), a class of fatty acids and has an anti-inflammatory function (Mei Dong et al., 2000).

3.2 Macroscopic Evaluation

Figure 2 shows the measurement results of open wound diameter in rabbits after treatment with pakoasi leaf extract ointment

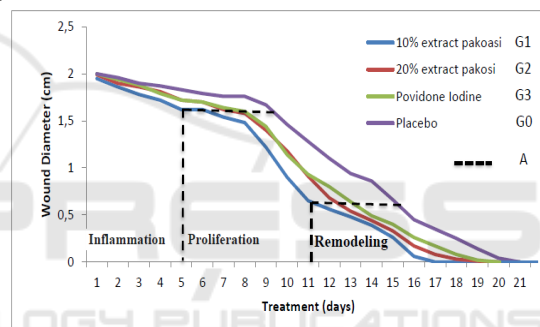


Figure 2: Healing process of each group following treatment.

Data presented in Figure 2 show that healing process began with inflammatory phase during day 1 to 4, then proliferative phase from day 4 to 11. The process was followed by remodelling phase that began from day 11 to 21. With 58% terpenoid and 12.07% saponin found in pakoasi extract, the wound healing process observed from the inflammatory phase could be accelerated by a difference of 0.35 cm within 4.5 days between G1 and G0. The inflammatory phase causes neutrophil migration, before progressing to the wound area that is replaced by monocytes (Yuliani, 2012). Thus, the inflammation process to the proliferation stage becomes faster, and accelerates the healing process.

Terpenoids sesquiterpen on pakoasi leaf extract has a function as an antioxidant. Antioxidant will bind unstable free radicals that can damage cell membranes. With this bond, free radicals are expected to be stable, so that cell membrane damage

can be reduced, and proliferation phase can be more rapid (Ardiana *et al.*, 2015).

Table 2. Wound diameter (mean cm ± SD) on day 4, 11 and 17 after treatments.

| Groups | Treatments | The day 4 | The day 11 | The day 17 |
|--------|---------------------|----------------------------|----------------------------|----------------------------|
| G1 | 10% Pakoasi extract | 1.72± 0.04 ^a | 0.65± 0.05 ^a | 0±0 ^a |
| G2 | 20% Pakoasi extract | 1.81± 0.02 ^b | 0.91± 0.07 ^b | 0.08± 0.04 ^b |
| G3 | Povidone Iodine | 1.79± 0.05 ^b | 0.93± 0.08 ^b | 0.17± 0.06 ^c |
| G0 | Placebo | 1.87± 0.04 ^b | 1.28± 0.08 ^c | 0.35± 0.08 ^d |

Note: Value with different superscript in the same column is significantly different ($p < 0.05$).

On day 4, there was a significant difference ($p < 0.05$) of wound diameter between G1 (1.75 ± 0.04) and G2, G3 and G0. The mean and standard deviation of wound diameter obtained by G1 on day 11 after treatment was significantly different from mean diameter of G2 and G3 ($p < 0.05$). The treatment given in G2 and G3 did not cause any significant difference ($p > 0.05$), whereas G2 and G3 were significantly different with G1 and G0. On day 17, the average diameter and standard deviation in G1, G2, G3 and G0 was 0 ± 0 , 0.08 ± 0.04 , 0.17 ± 0.06 and 0.35 ± 0.08 , respectively, and all treatments showed significant differences ($p > 0.05$).

3.3 Microscopic Evaluation

The results of histopathologic examination on day 3 and 7 (Table 3) showed significant increases in blood vessels and fibroblasts in G1 compared with other groups ($p < 0.05$).

Table 3. Scoring of epiteilization, collagenation, fibroblast development, PMN response, and blood vessel number of all groups on day 3, 7 and 21.

| Groups | Epithelisation | Collagen | Fibroblast | PMN | Blood vessel |
|--------|-----------------------------|----------------------------|-----------------------------|----------------------------|----------------------------|
| G1 | 1.33± 0.57 ^a | 0.67± 1.15 ^a | 2.33 ± 1.15 ^a | 2.00± 1.00 ^a | 3.67± 0.57 ^a |
| G2 | 1.67± 0.57 ^b | 0.00± 0.00 ^b | 1.33± 0.57 ^b | 1.67± 0.57 ^b | 1.00± 0.00 ^b |
| G3 | 1.67 ± 0.57 ^b | 0.67± 0.57 ^a | 0.67± 0.57 ^c | 1.67± 0.57 ^b | 1.33± 0.57 ^c |
| G0 | 1.33 ± 0.57 ^a | 0.67± 0.57 ^a | 1.33± 0.57 ^b | 1.33± 0.57 ^c | 0.66± 0.57 ^d |

Note: Value with different superscript in the same column is significantly different ($p < 0.05$).

Macrophages and neutrophils play roles during inflammatory phase. Neutrophil immediately exits blood vessels, and its number increases from 24 to 48 hours (Regan and Barbul, 1994). The number decreases on day 3 as it is replaced by macrophages. Macrophages and neutrophils have functions in preventing infection by phagocytosis of microorganisms that enter the wounded area. In the absence of infection in the wounded area, polymorphonuclear leukocytes are relatively short in time, and the number decreases rapidly after day 3 (Regan and Barbul, 1994).

The results of histopathology examination on day 3 and 7 in Table 3 show a significant increase in the number of blood vessels and fibroblasts in G1 compared to other groups. On day 3, the average number of blood vessels that are at that time blood vessel buds or endothelial progenitor cells go to the blood circulation to the granulation tissue become mature endothelium that will initiate angiogenesis (Icha *et al.*, 2016).

The next phase is proliferation or migration. The cells that play roles in this phase are macrophages, lymphocytes, fibroblasts and endothelial cells. Macrophages have a longer life span than polymorphonuclear leukocytes, and they remain until healing process has complete (Yuliani and Viktor 2015). Observation on day 7 showed the highest number of blood vessels due to endothelial cells experiencing the peak of the proliferation phase. Saponin content in pakoasi leaf extract increases monocyte proliferation. This leads to increasing number of macrophages. Macrophages produce and secrete growth factors to attract more fibroblasts to the wounded area, to synthesize collagen and to increase proliferation of capillary blood vessels (Ardiana *et al.*, 2015). Therefore, G1 had a high proportion of fibroblasts and blood

vessels in microscopic examination compared to other groups (Table 3).

The presence of growth factors may increase cell propagation or proliferation, and this will become a frame of fibroblast receptorization and proliferation. When fibrin clumped, fibroblasts will proliferate, and the number of fibroblasts will increase (Diegelmann, 2004). According to Thang et al. (1998), the active components present in *C.odorata* can stimulate fibroblast proliferation .

In the remodeling phase, the wound surface restores epithelial integrity and epithelialization from the basement membrane. Wound epithelial cells begin to show increasing mitotic activity and migrate the living connective tissue. Marginal basal cells on the edges of the wound become loosely bonded from the dermis nearby, enlarge and migrate to the surface of the wound that has filled the previous matrix (Singer and Clark, 1999). The microscopic results showed that the treatment given in G1 influenced re-epithelization, collagen formation, fibroblast formation, PMN cell inflammation, and blood vessel formation faster than G2, G3 and G0. This is consistent with a study carried out by Henshaw et al. (2017) that showed that the ethanol extract of *C. odorata L.* significantly increased the number of red blood cells, haemoglobin concentration and cell volume in white mouse animal experiments.

4 CONCLUSIONS

Pakoasi leaf extract ointment with concentration of 10% cure open wound faster than 20% concentration ointment, positive control (povidon iodine) and negative control (without treatment).

ACKNOWLEDGEMENTS

Acknowledgments are given to Mr. Suparman for technical assistance, Kholik DVM, M.Vet and Chandra Dwiatma DVM, M.Si for assisting in macroscopic and microscopic evaluations.

REFERENCES

Ardiana T, Andina R. P. dan Muhammad D F. 2015. *Efektivitas Pemberian Gel Binahong (Anredera Cordifolia) 5% Terhadap Jumlah Sel Fibroblast Pada Soket Pasca Pencabutan Gigi Marmut (Cavia*

Cobaya). ODONTO Dental Journal. Volume 2. Nomer 1. Juli 2015.

Arif M. Z. 2016. *Formulasi Sediaan Salep Ekstrak Etanol Daun Kirinyuh (Euphatorium Odoratum L.) Sebagai Penyembuh Luka Terbuka Pada Kelinci*. Fakultas Farmasi Universitas Muhammadiyah Surakarta

Ali N.A, Martina W, Arnold N, Lindequist U, Wessjohan L. 2008. *Essential Oil Composition from Oleogum Resin of Soqotraen Commiphora kua*, Rec. Nat. Prod. 2 (3): 70- 75

Diegelmann 2004. *Wound Healing: An Overview of Acute, Fibrotic, and Delayed Healing*. *Frontiers in Bioscience*, hal 283-289.

Ghelardini C, Galeotti N, Di Cesare Mannelli L, Mazzanti G, and Bartolini A. 2001. *Local anaesthetic activity of β -caryophyllene/ Farmaco*, vol. 56, no. 5-7, pp. 387–389.

Goeswin A. 2006. *Pengembangan Sediaan Farmasi. Institut Teknolgi Bandung*. Bandung.

Guo L, Jin-zong W, Tin H, Tong C and Khalid R. 2008. *Chemical Composition, Antifungal and Antitumor Properties of Ether Extracts of Scapania verrucosa Heeg. and its Endophytic Fungus Chaetomium fusiforme, Molecules*, 13: 2114-2125, DOI: 10.3390/molecules 13092114

Henshaw U O, Ifeyinwa M.O, Emmanuel K.U, Item J.A. 2017. *Some hematological parameters of Wistar rats treated with Chromolaena odorata leave extracts*. *JoJournal of Biological Research*; volume 90:6210

Icha Nofikasari, Afifah Rufaida, Chynintia Dewi Aqmarina, Failaso, Annisa Rahmi Fauzia, Juni Handajani. 2016. *Efek aplikasi topikal gel ekstrak pandan wangi terhadap penyembuhan luka ginggiva*. *Majalah Kedokteran Gigi Indonesia* Vol 2 No 2 – Agustus 2016 ISSN 2460-0164 (print), ISSN 2442-2576

Madhavan M. 2015. *Quantitative Estimation of total phenols and antibacterial studies of leaves extracts of Chromolaena odorata (L.) King & H.E. Robins* *International Journal of Herbal Medicine* 2015; 3(2): 20-23

Mei Dong, Yukiko Oda, Mitsuru Hirota. 2000. *10E,12Z-90Hdroxy-10,12,15-octadecatrienic acid Methyl Ester as an Anti-Inflammatory Compound From Ehretia dicksonii*. *The United Graduate Sholl of Agricultural Science, Gifu University, Japan. Biosci. Biotechnol, Biochem.*, 64 (4), 882-886.

Nils Bulow, Wilfried A Konig. 2000. *The role of germacrene D as a precursor in sesquiterpene biosynthesis: investigations of acid catalyzed, photochemically and thermally induced rearrangements*. *Phytochemistry* Volume 55, Issue 2, September 2000, Pages 141-168

Regan, M.C., and Barbul, A., 1994. *The Cellular Biology of Wound Healing in Fibrin Sealing in Surgical and Nonsurgical Fields*.

Singer, J.A. and Clark, R.A.F., 1999. *Cutaneous Wound Healing*. *Departements of Emergency and Dermatology*. State University of New York. Stony

- Brook. New York. The New England Journal of Medicine; Vol 341.
- Thang, T.P., Hughes, M.A., and Cherry, G.W.,1998. *Enhanced Proliferation of Fibroblast and Endothelial Cells Treated with an Extract of the Leaves of Chromolaena odorata (Eupolin), an Herbal Remedy for Treating Wound*. Plastic Reconstr. Surgery. 101.
- Padmin E.A, Valarmathi A, and Rani M.U. 2010. *Comparative Analysis of Chemical Composition and Antibacterial Activities of Mentha spicata and Camellia sinensis*. Asian J. Exp. Biol. Sci, 1 (4) : 772 – 781
- Yuliani S H. 2012. *Formulasi Sediaan Hidrogel Penyembuhan Luka Ekstrak Etanol Daun Binahong (Anredera Cordifolia (Ten) Steenis)* Program Pasca Sarjana. Program Study Ilmu Farmasi Fakultas Farmasi UGM. Yogyakarta.
- Yuliani N.S dan Viktor L. (2015). *Pengaruh Ekstrak Daun C.Odorata Terhadap Proses Kesembuhan Luka Insisi Pada Tikus Sprague-Dawley*. Jurnal Kajian Veteriner Desember 2015 Vol. 3 No. 2 : 93-99.

