

# Experimental Study on the Early Immunological Rejection in Xenotransplantation of Rabbit Fracture Hematoma Cells

Yan Fang<sup>1</sup>, Xia Dong<sup>1</sup>, Zhengjin Liu<sup>2</sup> and Xiaoping Ying<sup>1</sup>

<sup>1</sup>Laboratory of Molecular Pathology, Shaanxi University of Chinese Medicine, (Xiayang 712046) ;

<sup>2</sup>Zhongshan Hospital Xiamen University, (Xiamen 361004) .

**Keywords:** Xenotransplantation, hematoma cells, rejection.

**Abstract:** Objective: To investigate if xenotransplantation of rabbit fracture hematoma cells in the broken ends of fractured bone can lead to obvious hyper acute and acute immune rejection. Methods: We conducted a trial involving 90 rabbits with 4~6 weeks old, weighting 2.2~2.6kg, male and female in half. They were randomly divided into three groups: fracture group (n=30), fracture transplantation normal saline group (n=30), and fracture transplantation hematoma group (n=30). 3 days after animal models of sawed-off cubital bone was established, rabbits fracture hematoma cells which were derived from the ordinary livor blue rabbits' fracture hematoma and cultured in vitro were transplanted into the broken ends of fractured bone. Ten rabbits were sacrificed in each group at the 1st, 4th, and 8th day after the transplantation. Immunohistochemical method was adopted to observe the survival rate of fracture common chinchilla rabbit fracture hematoma cells, CD68+ macrophage infiltration and splenic lymph follicles. Immunohistochemical SABC method was used to detect the expression of CD68 in the macrophages of New Zealand white rabbits around the allograft. Results: After transplantation, the fracture hematoma cells of xenogeneic rabbits survived a lot at the fracture end, and the cells' structure was normal. The splenic lymphoid follicles did not proliferate significantly in each group and there was no significant difference in the expression of CD68 macrophages at each interval between groups. Conclusion: There was no significant immunological rejection in the early stage of xenotransplantation of rabbit fracture hematoma cells in the broken ends of fractured bone.

## 1 INTRODUCTION

It is well known that the formation of the hematoma after fracture can promote fracture healing, and it has also been reported that there are cases and experiments in fracture treatment with hematoma [1,2] and these results implied that after transplantation of the fracture hematoma cells, the subjects showed early callus formation, large amount callus formation, and the average fracture healing time was significantly shorter, indicating that the fracture hematoma had a significant effect in fracture healing. However, these studies are only applicable to autologous hematoma cells, while limited sources of autologous hematoma cells cultured in vitro proliferation and poor factors limits its practical application in the clinic. Therefore, heterologous transplantation of hematoma cells could be the better choice. Although the fracture hematoma cells are in a primitive state with weak auto antigenicity, there are no reports about whether

the heterogeneous hematoma cell transplantation will lead to significant immune rejection. Fracture hematoma cells of heterologous rabbits will be transplanted into the fracture model in this experiment to observe the early immune rejection, and explore the osteogenic potential of heterologous hematoma cell transplantation in fracture healing.

## 2 MATERIALS AND METHODS

### 2.1 Materials

#### 2.1.1 Animals and Groups

The experimental animals were New Zealand white rabbits bought from the experimental animal center of The Fourth Military Medical University. We conducted an experiment involving 90 rabbits with 4~6 weeks old, weighting 2.2~2.6kg, male and female in half. They were randomly divided into

three groups: fracture group (n=30), fracture transplantation normal saline group (n=30), and fracture transplantation hematoma group (n=30).

### 2.1.2 Cell Culture Reagents and Antibodies

DMEM medium (American Hyclone company), which include 100IU/ml penicillin, 100 g/ml streptomycin (Shanghai Biological Engineering Technology Co Ltd), 15% newborn bovine serum (PAA); BrdU and anti BrdU antibody, Goat anti-rabbit CD68, IgM and IgG first antibody, Rabbit anti-goat second antibody (Fujian Maixin biological Technology Development Company).

### 2.1.3 Main Instruments

OLYMPUS IX70-SIF2 inverted microscope, table model high speed centrifuge (BIOFUGE STRATOS, Heraeus company).

## 3 METHODS

### 3.1 Isolation and Culture of Fracture Hematoma Cells

Three days after the model of common livor blue rabbit femoral fracture, the rabbits were anesthetized with 3% pentobarbital sodium (30mg/kg) through ear vein. Hematoma cells from fracture sites were extracted under aseptic condition, and were put into Heparin Sodium Single-use Automatic Quantitative Tube for Blood Specimen Collection (purchased from Wuhan Zhiyuan Medical Technology Co., Ltd), 3ml each. The specimen was shaken up repeatedly to avoid the formation of small clots, moved to super-clean worktable and added with 2ml DMEM. After consecutive pumps with No.4 syringe needle, it was made into single cell suspension. Following centrifuge(1000r/min, 10min) to get rid of fat and supernatant, the remaining cell components were inoculated into 50ml culture bottle with DMEM, 2ml each. After 7 days under standard environment (37C°, saturated humidity,5% CO2), the culture medium was totally replaced and the suspending hemopoietic stem cells as well as unattached cells were removed. Then culture medium was replaced every 3~4 days, and cell shape and growth state were observed daily through inversion microscope. Subculture: when a complete layer formed, the cells were rinsed three times with PBS (purchased from Hyclone) with the supernatant removed and were treated with 0.25% trypsinase (from Gibco) and

0.02% EDTA (from Gibco) for 5 min at the ratio of 1 : 2 before subculture.

### 3.2 BrdU Labeling of Fracture Hematoma Cells

When formed a complete single layer, these 2nd generation hematoma cells were incubated with BrdU (terminal concentration:10 mmol/L) for 24h, followed by washing with non-serum DMEM medium for 5 times, and were treated with 0.125% trypsinase and 0.01% EDTA before they were made into 1×10<sup>8</sup>/ml cell suspension for cell transplantation [3-4].

### 3.3 Rabbit Fracture Model

With ulna exposure, the New Zealand rabbits were conventionally anesthetized, fixed under aseptic conditions, Ulnas were sawed cross-sectionally across the middle part with sterile hacksaw blade, then muscle and skin were sutured. Skin was disinfected and bound with gauze. 1~5 days after operation, rabbits were administered penicillin intramuscularly every day (0.3million unit/kg)

### 3.4 Transplantation of Fracture Hematoma Cells

Hematoma cells were transplanted on the 3rd day of fracture modelling[5]. Group for fracture transplantation hematoma cell: BrdU marked hematoma cells were injected with needles perpendicular to ulna and fracture cross-sections, with 10mm and13mm in depth, inoculated with 5μL of cell suspension, and then withdrawn needle slowly after 10min. Saline group of fracture transplantation: The physiological saline was injected according to the above method.

### 3.5 Test Results

#### 3.5.1 The Growth of Hematoma Cells

After heterologous transplantation, 10 rabbits from each group were executed at the 1st, 4th and 8th days, respectively. Their ulnas were taken out and decalcificated for 60d with 15% neutral EDTA(purchased from Gibco), continued with dehydration in a graded series of alcohol before they were made into paraffin-embedded sections. DAB staining with anti-BrdU monoclonal antibody ABC method witnessed that BrdU positive reactants located at nucleus were brown, granular-like or

distributed diffusely. 5 sections from each New Zealand white rabbit were selected and observed under low-magnification microscope ( $\times 10$ ) to count the total number of BrdU positive cells for statistical processing.

### 3.5.2 The Infiltration of Neutrophils at the Broken End of the Fracture on the First Day After Xenotransplantation Was Observed Under Light Microscope

5 pieces of the ulna paraffin sections of New Zealand white rabbits executed on the first day after operation were selected and stained with conventional HE. 10 slices of vision were taken from each slice, and neutrophils were counted at high power microscope ( $\times 40$ ). Then the neutrophils were counted and processed statistically.

### 3.5.3 Immunohistochemical S-P Assay Was Used to Detect CD68 Positive Mononuclear Macrophages at Fractured End

Immunohistochemistry S-P kits and CD68, produced in Zgmed, were purchased from Fujian Maixin Biotech Co.Ltd. CD68 positive sections were chosen as positive control, while PBS, in place of first-antibody, was taken as negative control. Positive reaction arose when the total cell count of brown granules was more than 10%, and scoring was done based on positive cell count percentage and coloring intensity, and the sum of the two indexes were analyzed statistically.

### 3.5.4 Count Lymphoid Cells

On the 1st, 4th and 8th day after heterologous transplantation, 10 rabbits from each group were executed. Their ulnas and spleens were taken out and rinsed with saline, fixed with 4% neutral formaldehyde solution and dehydrated in a graded series of alcohol before they were made into paraffin-embedded sections. After routine HE staining, the largest section was observed from five randomly selected views under four-fold objective lenses. Meanwhile, lymphoid follicle count was recorded (when lymphoid follicle covered the middle-line, the left and upward sites rather than the right and downward sites were recorded). Then the data were analyzed statistically and  $\chi^2$  test was adopted.

## 3.6 Statistical Methods

All the data were analyzed with SPSS13.0 software. Measurement data was expressed with mean  $\pm$  standard deviation ( $\bar{x} \pm s$ ), and  $\chi^2$  test was adopted.

## 4 RESULTS

1. The 3th day of primary culture (Fig. 1), it can be seen sporadic hematoma cells, and most of them are short spindle or triangle. The 12th day of Primary culture (Figure 2), hematoma cells were fused into monolayer and primary growth was completed.

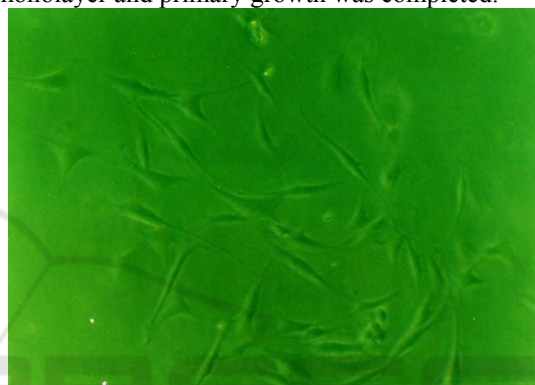


Fig. 1: the 3<sup>th</sup> day of primary culture ( $\times 100$ ).

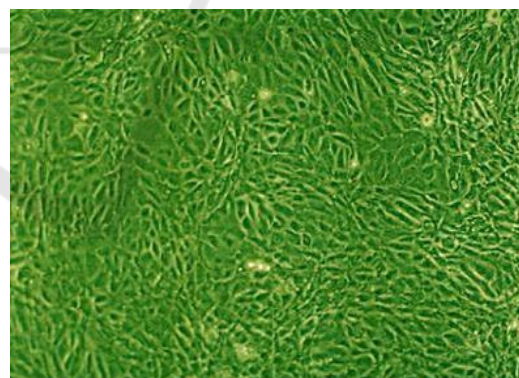


Fig. 2: the 12<sup>th</sup> day of primary culture ( $\times 100$ ).

2. Growth status of hematoma cells at different times in Hematoma Cells group: On the 1st, 4th and 8th days after heterologous transplantation, many BrdU positive hematoma cells with normal structure were visible in the transplanted region, and no obvious degeneration and necrosis could be found. Positive cell count results showed that according to comparison of positive cell counts in different post-operational periods ( $\bar{x} \pm s$ ), BrdU positive cell count on the 4th day ( $57.20 \pm 4.632$ ) outnumbered that



of on the 1st day ( $38.72 \pm 5.217$ ) and 8th day ( $46.43 \pm 4.345$ ) ( $P < 0.05$ ).

3. One day after xenotransplantation in New Zealand white rabbits, neutrophils counts in the broken ends of fracture bone ( $\bar{x} \pm s$ ): fracture group ( $8.6 \pm 0.72$ ), saline group ( $9 \pm 0.55$ ) and hematoma cell group ( $8.9 \pm 0.43$ ), neutrophils counts have no significant difference in each group ( $P > 0.05$ ) (Figure 3).

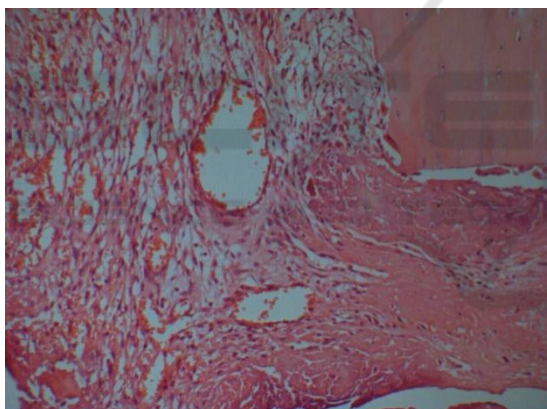
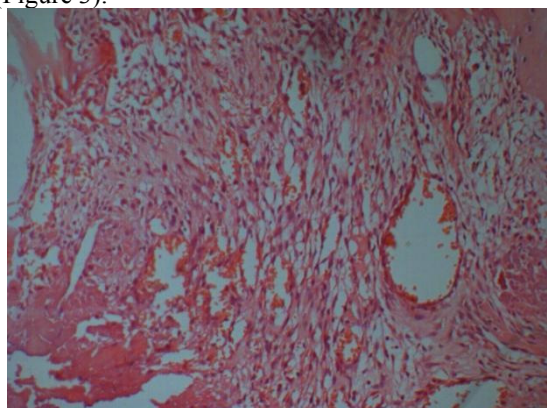


Figure 3: Neutrophilic granulocyte infiltration around the broken end of the fracture (1<sup>th</sup> day) ( $\times 100$ ).

4. The expression of IgM and IgG around the broken end of the fracture bone in New Zealand white rabbits: no obvious brown granules.

5. Different number of CD68 positive mononuclear macrophages was found in both the hematoma group and the control group (Figure 4). (Table 2)

Table 2: CD68 positive cells counts of the three rabbits' groups at different time ( $\bar{x} \pm s$ ).

N	Fracture group	Saline group	Hematoma cell group
1th day 30	$0.8 \pm 1.1$	$0.9 \pm 0.5$	$0.9 \pm 0.7$
4th day 30	$4.6 \pm 1.2$	$4.7 \pm 1.0$	$5.0 \pm 0.8$
8th day 30	$5.0 \pm 0.7$	$5.2 \pm 0.8$	$5.3 \pm 0.6$

Note: no significant difference between each group on the 1th day, 4th day and 8th day after operation ( $P > 0.05$ ).

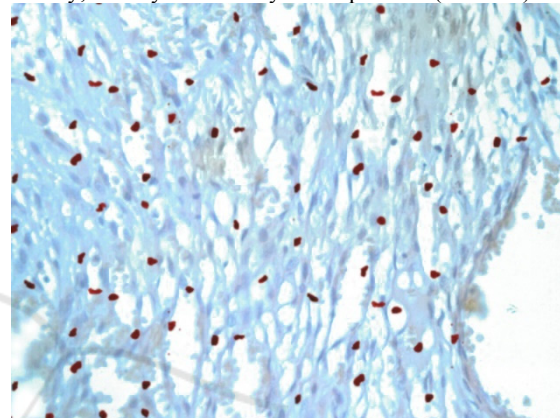


Figure 4: Count of lymphoid follicles in the spleen (4th day) ( $\times 200$ ).

6. The count of lymphoid follicles in the spleen (Table 1)

Table 1: lymphoid follicles counts of three groups of rabbits after transplantation at different time ( $\bar{x} \pm s$ ).

Fracture group	Saline group	Hematoma cell group	
1st day	$17.6 \pm 0.52$	$18.0 \pm 0.55$	$17.9 \pm 0.43$
4th day	$17.5 \pm 0.46$	$17.7 \pm 0.55$	$18.2 \pm 0.50$
8th day	$18.0 \pm 0.34$	$18.2 \pm 0.43$	$18.4 \pm 0.35$

Note: no significant difference between each group on the 1th day, 4th day and 8th day after operation ( $P > 0.05$ ).

## 5 DISCUSSION

It is known that the hematoma formed by fracture plays an important role in the process of fracture healing. The studies on extracting hematoma cells to promote fracture healing are also confirmed that hematoma cells have a significant role in fracture healing [2], however, due to the limited sources of cell and the time difference of in vitro hematoma culture, the practical application chances of it are greatly reduced. The xenogeneic fracture hematoma

cells are widely distributed, which can be stored in advance, and also highly proliferative and multipotential, so they can be one of the best seed cells to replace autologous hematoma cells transplantation for the treatment of fracture healing [6]. In recent years, the proliferation of in vitro cell culture is increasingly mature, which makes it possible to proliferate a large number of primary cells in the short term and can be reserved for a long time. In theory, it is considered that the fracture hematoma cell is a relatively primitive cell with weak antigenicity. Therefore, allograft transplantation may cause mild or even no immune rejection. But up to now, no specific experimental study at home and abroad was reported.

Schuurman et al. [7] divided xenograft rejection in the early stage into three categories: hyperacute rejection (HAR), acute humoral xenograft rejection (AHXR), and acute cellular xenograft rejection (ACXR). Studies have shown that the graft non-function were mainly due to the hyperacute rejection and the acute dissimilar rejection of the body fluid. Hyperacute rejection is a leading cause which occurs within 24 hours after transplantation, It is mainly the antibody mediated mechanism, which is the humoral immune response caused by the natural antibody IgM, and the natural antibody IgG also plays a certain role [8-10]. Dehoux [11] suggests that anti IgM and IgG play an important role in activating endothelial cells and complement. Especially the induction of anti -Gal IgG is significantly elevated in AHXR, which may play a major role. The diagnostic criteria for antibody - mediated acute graft rejection include 3 basic characteristics [12]: (1) morphological evidence for acute tissue injury. (2) immunological evidence of antibody action. (3) Serological evidence of circulating donor specific human leukocyte antigen (HLA) antibody or other donor epithelial cells antigen specific antibodies. One of the characteristics of AHXR is the infiltration of all kinds of cells to the grafts. The existence of neutrophils has a certain predictability in the diagnosis of AR, and it may represent early immune response is activated [13-15]. Fischbeck [16] study shows that DXR is mediated by immune cells such as mononuclear cells. Mononuclear phagocyte system responsible for recognition and rejection of xenogeneic antigen in xenotransplantation [17]; The lymphoid follicles in the spleen increases when the antigen and blood circulation enters the spleen and causes humoral immune response [18]. The results showed that after the ordinary rabbits hematoma cells were transplanted into New Zealand rabbits fracture of 1

days、4 days and 8 days after transplantation, a large number of xenohematomas survived in the transplanted region, no obvious degeneration and necrosis were found and no obvious IgM and IgG deposition was found around the broken end of the fracture. There was no significant difference in the infiltration of neutrophils and CD68 positive macrophages in the fracture area between each group in different time. At the same time, there was no significant difference in the number of splenic lymphoid follicles in and between groups at different time, and no significant proliferation of the splenic lymphoid follicles was found. All these indicate that there is no obvious rejection reaction between transplanted rabbit xenogeneic hematoma cells and their receptors in early stage, and good histocompatibility also imply that allogeneic hematoma cells transplantation is feasible, which provides an experimental basis for future treatment of fractures or bone defects.

## REFERENCES

1. Mizuno K, Mineo K, Tachibana T, et al. The osteogenetic potential of fracture haematoma. Subperiosteal and intramuscular transplantation of the haematoma [J]. *J Bone Joint Surg (Br)* 1990, 72(5):822-9.
2. Guo Hongwang, Li Yuxue. Reutilization of hematoma at fracture site [J]. *China Journal of Orthopaedics and Traumatology*, 2001, 14(1):50-51.
3. Guo Q, Liu Z, Zhanqing L I. Technical explore on mesenchymal stem cells in bone marrow using BrdU labelling [J]. *Journal of North China Coal Medical College*, 2004, 6(1): 4-7.
4. Guo Qicang, Zhang Yu, Wang Yufang. Characteristics and feasibility of bone marrow-derived mesenchymal stem cells labeled with 5-bromodeoxyuridine [J]. *Chinese Journal of Clinical Rehabilitation*, 2006, 10(5):144-146.
5. Li Guitao, Li Huaren, Xu Hongzhang. Experiment Study of the Osteogenetic Potential of Bone Hematoma [J]. *Chinese Journal of Bone and Joint Injury*, 2004, 19(5):323-324.
6. Grundnes O, Reikers O. The importance of the hematoma for fracture healing in rats [J]. *Acta Orthopaedica Scandinavica*, 1993, 64(3):340-2.
7. Schuurman HJ, Pino CG, Phillips MJ, et al. Incidence of hyperacute rejection in pig-to primate transplantation using organs from hDAF-transgenic donors. *Transplantation*, 2002, 73(6):1146-1157
8. Koren E, Neethling F A, Richards S, et al. Binding and specificity of major immunoglobulin classes of preformed human anti-pig heart antibodies [J]. *Transplant International*, 1993, 6(6):351.

9. Kujundzic M, Koren E, Neethling F A, et al. Variability of anti- $\alpha$ Gal antibodies in human serum and their relation to serum cytotoxicity against pig cells[J]. *Xenotransplantation*, 1994, 1(1):58-65.
10. Bach F H. Discordant xenografting: a summary and look to the future[J]. *Transplantation Proceedings*, 1992, 24(2):739-742.
11. Dehoux JP, Parra B, Latinne D, et al. Characterization of baboon anti-porcine IgG antibodies during acute vascular rejection of porcine kidney xenograft[J]. *Xenotransplantation*, 2002, 9(5): 338-349.
12. Zhang Qixu, Zhou Gang. Research progress of hyperacute rejection in xenotransplantation[J]. *Chinese Journal of Plastic Surgery*, 2006, 22(6):468-471.
13. Takahashi H, Kato T, Selvaggi G, et al. Subclinical rejection in the initial postoperative period in small intestinal transplantation: a negative influence on graft survival[J]. *Transplantation*, 2007, 84(6): 689-696.
14. Ruiz P, Takahashi H, Delacruz V, et al. International grading scheme for acute cellular rejection in small-bowel transplantation: single-center experience[J]. *Transplant Proc*, 2010, 42(1): 47-53.
15. Tong W, Bond G, Martin D, et al. Histopathologic characteristics of human intestine allograft acute rejection in patients pretreated with thymoglobulin or alemtuzumab[J]. *Am J Gastroenterol*, 2006, 101(7): 1617-1624.
16. Fischbeck JA, Baier JM, Akella R, et al. Genetic modification of alphaGal expression in xenogeneic endothelial cells yields a complex immunological response[J]. *Tissue Eng*, 2001, 7(6):743-756.
17. Papadimitriou J M, Ashman R B. Macrophages: current views on their differentiation, structure, and function[J]. *Ultrastructural Pathology*, 1989, 13(4):343-372.
18. Lingzhong Cheng. *Modern Histology*[M]. Shanghai Science and Literature Press, 2003..653-654