

A Semiautomatic Image Processing Tool to Measure Small Structures in Magnetic Resonance Images of the Brain at 7 Tesla

Application to Hippocampus Subfields of Patients with Mild Cognitive Impairment

Alessandra Retico¹, Graziella Donatelli², Mauro Costagli^{3,4}, Laura Biagi³, Maria Evelina Fantacci^{1,5}, Daniela Frosini⁶, Gloria Tognoni⁶, Mirco Cosottini^{2,4} and Michela Tosetti^{3,4}

¹Istituto Nazionale di Fisica Nucleare, Sezione di Pisa, Pisa, Italy

²Dipartimento di Ricerca Traslationale e delle Nuove Tecnologie in Medicina e Chirurgia, Università di Pisa, Pisa, Italy

³IRCCS Fondazione Stella Maris, Pisa, Italy

⁴Fondazione Imago7, Pisa, Italy

⁵Dipartimento di Fisica, Università di Pisa, Pisa, Italy

⁶Dipartimento di Medicina Clinica e Sperimentale, Università di Pisa, Pisa, Italy

Keywords: Image Processing Methods, Magnetic Resonance Imaging, Hippocampus, Mild Cognitive Impairment, Alzheimer Disease.

Abstract: The current availability of Magnetic Resonance (MR) systems that operate at ultra high magnetic field (≥ 7 Tesla) allows the representation of anatomical structures at sub-millimeter resolution. Interestingly, small structures of the brain, such as the subfields of the hippocampus, the inner structures of the basal ganglia and of the brainstem become visible. Suitable software packages that allow analyzing and measuring such small structures are not currently readily available. We developed a semi-automated procedure to measure the thickness of the stratum radiatum and lacunosum-moleculare (SRLM) of the hippocampus. The change in the thickness of this subfield of the hippocampal formation is supposed to have a role in the pathological cognitive decline. Once we developed and validated the semiautomatic procedure on the 7T high-resolution T2*-weighted images of a healthy volunteer, we carried out a preliminary study on a population affected by Mild Cognitive Impairment to investigate the correlations of the SRLM thickness with the clinical scores of the patients, e.g. the Mini-Mental State Examination score and the Free and Cued Selective Reminding Test.

1 INTRODUCTION

The use of ultra high-field (UHF) Magnetic Resonance Imaging (MRI) systems, operating at magnetic field strength of 7 Tesla and above, has opened new perspectives in clinical research studies (Kraff, 2015; van der Zwaag, 2015). Among the established advantages of UHF is the high-resolution structural imaging. Interestingly, small structures of the brain, such as subfields of the hippocampus (Thomas, 2008), become visible (Figure 1), but the understanding of their potential role in the onset of the Alzheimer's Disease is still an open research issue (Kerchner, 2012; Brown, 2014). Several groups of researchers are working to make available software packages to identify and measure the hippocampal substructures with manual,

semiautomatic and automatic procedures (Van Leemput, 2009; Wisse, 2012; Pipitone, 2014). Their reliability and usefulness is still under evaluation by the international scientific community. In particular, none of the segmentation algorithms that have been presented so far is able to measure an extremely thin structure such as the stratum radiatum and lacunosum-moleculare (SRLM) of the hippocampus. Recent studies highlighted the relevance of this thin hippocampal subfield in the early stages of pathological cognitive decline, especially the mild Alzheimer's Disease. Cognitive decline can represent a symptom of normal aging but also a forerunner of dementia; within this spectrum of disease, the Mild Cognitive Impairment (MCI), defined as a cognitive decline greater than expected for age and education that can evolve to dementia, is an interesting transitional stage to investigate.

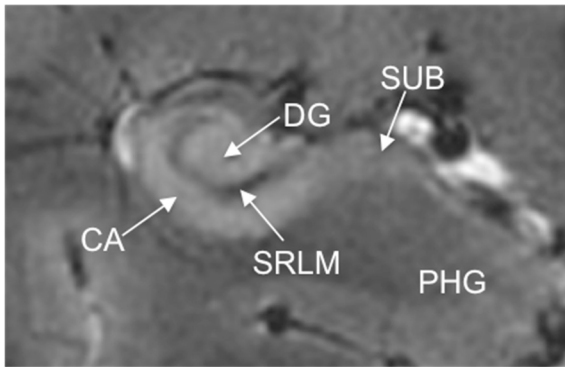


Figure 1: High-resolution coronal image of the hippocampus in vivo acquired at 7 T with 2D T2*-weighted GRE sequence (TE=22 ms, TR=240 ms, in-plane resolution $0.3 \times 0.3 \text{ mm}^2$, slice thickness = 2 mm). A slice through the hippocampus body is visible, showing detailed structures including cornu ammonis (CA), dentate gyrus (DG), stratum radiatum and lacunosum-moleculare (SRLM), subiculum (SUB) and parahippocampal gyrus (PHG). The overall thickness of the SRLM was shown to be lower in patients with mild Alzheimer's Disease compared to healthy subjects (Kerchner, 2010) and to correlate with memory performance (Kerchner, 2012).

The aim of the present work is to develop a semiautomatic procedure to measure the SRLM thickness by using 7T high-resolution T2*-weighted MR images. Once the algorithm is set up on a sample image of a healthy volunteer, the semiautomatic procedure is used to investigate the relationship between SRLM thickness and clinical scores in MCI patients.

2 METHODS

We propose a semiautomatic procedure to measure the thickness of the SRLM, which imports some basic ideas of the algorithm presented by Kerchner *et al* (2012) with the same purpose, and extend it to make the measure more reliable and reproducible.

2.1 The Semiautomatic Algorithm to Measure the SRLM Width

First of all an oblique coronal slice prescribed perpendicularly to the axis of the hippocampus, where the SRLM is visible, is presented to the user, who is asked to select the centre of the Region of Interest (ROI) for the following steps (see Figure 2). The ROI is zoomed to allow the user to modify the image contrast and the brightness and to draw a line by mouse clicking along the curved shape of the

SRLM. Then, the algorithm that estimates the SRLM width automatically starts running. It prompts the user intermediate graphs and figures, which are useful to check in real time the quality and the reliability of the estimated SRLM width obtained at the end of the procedure. Going into the details of the procedure, it consists in the following steps (Figure 2):

- 1) the user defined line following the curve shape of the SRLM is interpolated with a spline;
- 2) the normal directions to the spline are computed and the normal vectors are overlaid to the original ROI and shown to the user;
- 3) the image intensity profiles along the normal directions are computed and mounted in 2D image, where the hippocampus appears as unrolled along the SRLM;
- 4) the SRLM appears as a dark straight band in this 2D image, which is finally squeezed along the SRLM direction to obtain the average of the image intensity across all normal profiles;
- 5) as this averaged intensity profile shows a Gaussian shape, a fit with a Gaussian function is carried out, and its width (4σ) is retained as a measure of the SRLM thickness.

As shown in Figure 2, a first check on the quality and reliability of the SRLM measure obtained through this semiautomatic procedure can be done directly by the user while running the software. For the procedure to be correctly executed, the manually delineated line should be placed in the middle of the SRLM or close to either its upper or lower boundary. Only in this case the hippocampus will be correctly unrolled and the picture in Figure 2(d) will contain straight bands. This correct alignment of the profiles prevents their average to blur and the SRLM width to be overestimated.

2.2 Reproducibility of the Measure

The reproducibility of the measure of the SRLM provided by the semiautomatic procedure has to be checked. Variability in repeated measures are indeed induced by the choice of the points along the SRLM profile operated by the end user, which is scarcely reproducible from run to run. To this purpose one of the user of the proposed semiautomatic tool was asked to repeat ten times the same measurement for both the left and right hippocampi of one subject.

By means of these measurements the variability of the measurements has been estimated.

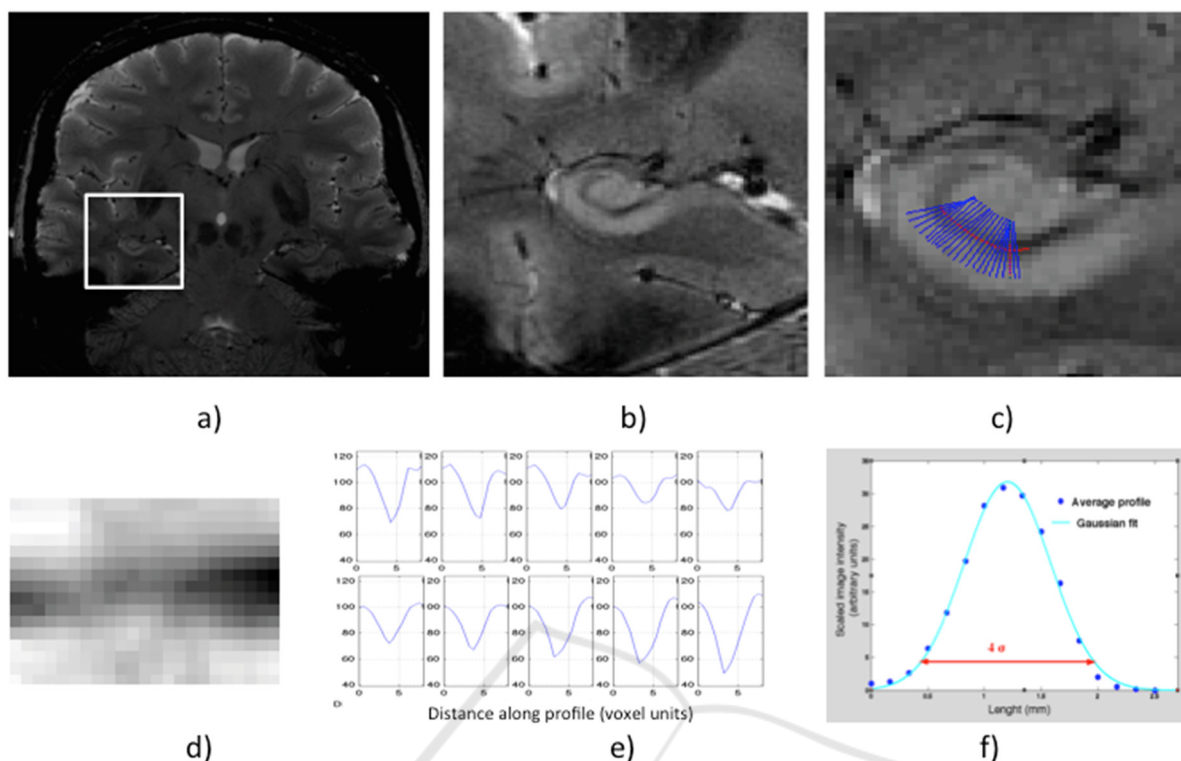


Figure 2: Main steps of the semiautomatic procedure to estimate the thickness of the stratum radiatum and lacunosum-moleculare (SRLM): a) the user selects a point in the region of interest (ROI); b) the ROI is enlarged to allow the user to draw the SRLM profile by mouse clicking; c) these point are interpolated with a spline and the normal vectors to the profiles are computed and shown; d) the image intensity profiles along the normal segments are combined in a linear image (the “unrolled” SRLM); e) a subsample of the profiles are shown to the user for a visual check; f) the linearized SRLM image (d) is squeezed along the SRLM direction, i.e. the profiles (e) are averaged and the SRLM thickness is derived from the width of the Gaussian fit (4σ).

3 SET UP AND VALIDATION OF THE ALGORITHM

3.1 Practical Implementation of the Algorithm on MRI Data

The algorithm has been implemented in Matlab (R2009b, The MathWorks, Inc.), and its execution is managed by a very basic GUI, which only aims to allow the software usage by researchers with a limited expertise in the Matlab environment.

To set up the algorithm and to fix all the free parameters, the brain 7T-MR examination of a healthy volunteer was considered. MR images were acquired with a 7T MR950 scanner (GE Healthcare Medical Systems, Milwaukee, WI, USA) equipped with a 2ch-Tx/32ch-Rx head coil (Nova Medical, Wilmington, MA USA).

The acquisition protocol included a high-resolution 2D T2*-weighted sequence prescribed perpendicular to the longitudinal axis of the hippocampus and covering the hippocampal body (gradient-recalled echo –GRE–, TE=22 ms, TR=240 ms, in-plane resolution $0.3 \times 0.3 \text{ mm}^2$, slice thickness = 2 mm).

Data are converted from the DICOM to the NIFTI format as a prerequisite to run our algorithm.

As we are only interested in the thickness on the SRLM, regardless its contrast with respect to the surrounding brain structures, we do not need to normalize the MR image intensity.

The user selects points along the SRLM, which are connected through spline interpolation. The obtained user-defined profile is sampled so to accommodate at least 15 normal segments, whose length is set to 2.5 mm. This length has been optimized on data to properly cover the SRLM

thickness plus an additional margin, which is necessary to obtain a stable Gaussian fitting.

3.2 Test of the Reproducibility of the Measure of the SRLM Thickness

The thickness of the SRLM of the left and the right hippocampi of the healthy volunteer has been measured ten times. The variability in the appearance of the linearized SRLM images obtained at each repetition of the experiment is visible in Figure 3, where only five out of the ten measures per side are shown for demonstration purpose. Also the Gaussian fits on the average profile are visible in the figure.

We obtained the following measures of the SRLM (average \pm standard deviation [range of values]): (1.61 \pm 0.10) mm [1.51–1.83 mm] for the left hippocampus and (1.53 \pm 0.04) mm [1.47–1.61 mm] for the right hippocampus. The measure is considered as highly reproducible, as the estimated error is limited to few per cents of the measured thickness, i.e. the 6% and the 3% for the left and right hippocampus, respectively.

4 APPLICATION TO MCI SUBJECTS

Once the semiautomatic algorithm has been developed and validated on the 7T MR image of a healthy volunteer, it has been used in a clinical study involving subjects affected by MCI.

4.1 Data Sample

Ten MCI patients underwent a brain 7T-MR examination including a high-resolution 2D T2*-weighted sequence targeting hippocampus. All patients underwent a neuropsychological battery including the Mini-Mental State Examination (MMSE) and the Free and Cued Selective Reminding Test (giving great attention to the free recall FCSRT-FR).

4.2 SRLM Measures on MCI Patients and Correlation with Clinical Tests

An experienced neuroradiologist used the semiautomatic image processing tool we developed to delineate the SRLM profile on a coronal oblique slice of the 7T T2*-weighted MRI of each MCI patient. The thickness of the SRLM was estimated.

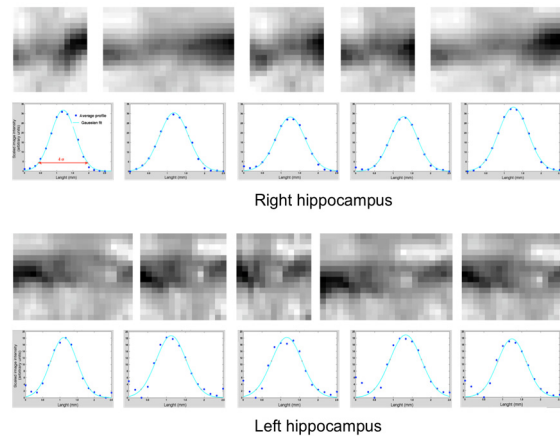


Figure 3: Test of the reproducibility of the SRLM measure. Five repetitions of the algorithms for the left and right hippocampi are shown (out of the 10 repetitions used for the test): the user-defined SRLM profile slightly changes from run to run leading to different “unrolled” SRLM images, and slightly different averaged profile and Gaussian fit.

This estimation has been done for both the right and the left hippocampi.

The correlation between the measured SRLM thickness and the numerical scores provided by the neuropsychological tests were analysed according to the Spearman’s rank test. Our preliminary results showed that the average SRLM thickness (average value between the left and right hippocampi) correlated with MMSE score ($r=0.60$; $p<0.1$; $n=10$) while the average SRLM thickness of the right hippocampus correlated with the FCSRT-FR ($r=0.97$; $p<0.05$; $n=5$).

5 CONCLUSIONS

We present in this paper a semiautomatic image processing tool to measure the thickness of small structures in anatomical images. The high-resolution structural imaging that can be acquired with MRI at UHF (7T) allows the visualization of very thin anatomical structures. Suitable tools to measure their size in a reproducible way might have a fundamental role in clinical research studies.

As a case study we focused on the measure of one of the hippocampal subfields, the SRLM, which is supposed to be involved in early degenerative changes related to pathological cognitive decline. We developed the procedure on a representative 7T T2*-weighted MR image of a healthy volunteer, and tested it on a sample of subjects affected by MCI. We found that the SRLM thickness correlated with

the MMSE and the FCSRT-FR neuropsychological scores.

The choice of a semiautomatic approach instead of a fully automated one was dictated by two main reasons: 1) the definition of the structures of interest varies according to international protocols still under study by the community of neurologists (Yushkevich, 2015); 2) a semiautomatic tool can at this stage help defining eloquent structures of interest for specific pathologies in exploratory studies by the community of neuroradiologists and neurologists. Then, once the target anatomy of interest is fully delineated, software developers can further improve the semiautomatic tools to make them fully automatic.

The possibility to extract from 7T brain MRI quantitative features related to the underlying pathological condition of the MCI subjects can open the way to the development and application of more robust predictive models of early diagnosis of Alzheimer's disease based on machine learning techniques (Chincarini, 2011; Retico, 2015).

Among the limitations of the present work are: the need to implement other segmentation strategies to obtain the global extent of the anatomical structure under evaluation (e.g. the entire hippocampus) to account for its effect in the statistical analysis; the 2D nature of the procedure, which can be extended to 3D data, where available; the need to substantiate the reproducibility test results with more than one subject's data and to validate the algorithm reliability in an inter-rater reliability test.

Finally, the algorithm proposed in this paper, despite tailored to measure the SRLM thickness, can be used to measure the thickness of other thin anatomical structures represented in 7T MR images. Moreover, as the proposed approach is only based on the assumption of a Gaussian shape of the image intensity profile, it can be extended with few modifications to measure the thickness of different anatomical thin structures appearing in images acquired with other imaging modality.

ACKNOWLEDGEMENTS

This work has been partially funded by the Italian Ministry of Health and the Tuscany Government (RF-2009-1546281 *Clinical impact of ultra high-field MRI in neurodegenerative diseases diagnosis* PI: M. Cosottini) and by the National Institute for Nuclear Physics (nextMR project).

REFERENCES

- Brown, TI, Hasselmo, ME et al., 2014. 'A high-resolution study of hippocampal and medial temporal lobe correlates of spatial context and prospective overlapping route memory', *Hippocampus*, vol. 24, no. 7, pp. 819-839.
- Chincarini, A, Bosco, P et al., 2011. 'Local MRI analysis approach in the diagnosis of early and prodromal Alzheimer's disease', *Neuroimage*, vol. 58, no. 2, pp. 469-480.
- Kerchner, GA, Hess, CP et al., 2010. 'Hippocampal CA1 apical neuropil atrophy in mild Alzheimer disease visualized with 7-T MRI', *Neurology*, vol. 75, pp. 1381-1387.
- Kerchner, GA, Deutsch et al., 2012. 'Hippocampal CA1 apical neuropil atrophy and memory performance in Alzheimer's disease', *Neuroimage*, vol. 63, pp. 194-202.
- Kraff, O, Fischer, A et al., 2015. 'MRI at 7 Tesla and Above: Demonstrated and Potential Capabilities', *J MRI*, vol. 41, pp. 13-33.
- Pipitone, J, the Alzheimer's Disease Neuroimaging Initiative et al., 2014. 'Multi-atlas segmentation of the whole hippocampus and subfields using multiple automatically generated templates', *Neuroimage*, vol. 101, pp. 494-512.
- Retico, A, Bosco P et al., 2015. 'Predictive Models Based on Support Vector Machines: Whole-Brain versus Regional Analysis of Structural MRI in the Alzheimer's Disease', *J Neuroimaging*, vol. 25, no. 4, pp. 552-563.
- Thomas, BP, Welch, EB et al., 2008. 'High-Resolution 7T MRI of the Human Hippocampus In Vivo', *J MRI*, vol. 28, pp. 1266-1272.
- van der Zwaag, W, 2015. 'Recent applications of UHF-MRI in the study of human brain function and structure: a review', *NMR in Biomedicine*, DOI: 10.1002/nbm.3275.
- van Leemput, K, Bakkour, et al., 2009. 'Automated Segmentation of Hippocampal Subfields From Ultra-High Resolution In Vivo MRI', *Hippocampus*, vol. 19, pp. 549-557.
- Wisse, LEM, Gerritsen, L et al., 2012. 'Subfields of the hippocampal formation at 7 T MRI: In vivo volumetric assessment', *Neuroimage*, vol. 61, pp. 1043-1049.
- Yushkevich, PA & Hippocampal Subfields Group (HSG). 2015. 'Quantitative comparison of 21 protocols for labeling hippocampal subfields and parahippocampal subregions in in vivo MRI: Towards a harmonized segmentation protocol', *Neuroimage*, vol. 111, pp. 526-241.