


Rheophthalmography Used for the Analysis of Blood Flow in the Posterior Part of the Eye

P. V. Luzhnov¹^a, A. A. Kiseleva¹, E. N. Iomdina², L. V. Vasilenkova² and O. A. Kiseleva²

¹*Bauman Moscow State Technical University, 5, 2-nd Baumanskaya St., Moscow, Russian Federation*

²*Hemholtz National Medical Research Center of Eye Diseases, 14/19, Sadovaya-Chernogryazskaya St., Moscow, Russian Federation*

Keywords: Rheophthalmography, Ocular Blood Flow, Primary Open-angle Glaucoma.

Abstract: The paper is aimed at developing a new rheophthalmography (ROG) technique able to measure electrical impedance signals of patients with primary open-angle glaucoma (POAG), which could facilitate early diagnostics of the disease and the differentiation of its stages. We used a technique of electrode positioning differing from the transpalpebral ROG technique used previously. Specifically, we changed the distance between the measuring electrodes and their location pattern: the axis of symmetry was rotated 90° relative to that used in the transpalpebral technique and located vertically rather than horizontally. This technique was applied to ROG signals of 32 patients (42 eyes) aged 67.7 years averagely. Of these, 6 patients (10 eyes) average aged 62.7 years had stage I (early) POAG or suspected POAG; 13 patients (17 eyes) average aged 69.4 years had stage II (developed) POAG; 10 patients (12 eyes) average aged 70.0 years had stage III (advanced) POAG; 3 patients (3 eyes) average aged 69.3 years had stage IV (terminal) POAG. The results of this study confirmed the feasibility of the above technique for ROG signal registration. The recorded signals are informative for quantitative assessment of blood flow in the posterior part of the eye, which enables early POAG diagnostics and differentiation between POAG stages.

1 INTRODUCTION

The normal functioning of the eye is essentially determined by the blood flow level in its tissues. For ocular pathologies such as progressive myopia, diabetic retinopathy, and glaucoma, eye hemodynamic examination provides the ophthalmologist with additional information about their pathogenesis, gives the opportunity for early diagnosis, prognostication of the disease development, and assessment of treatment effectiveness. The research in this area is important due to the growing incidence of these ophthalmic diseases.

The electrical impedance technique allows non-invasive assessment of blood flow in diverse segments of the human body (Patterson, 2005; Bodo, 2010; Lazarenko, 2004). It extracts information about the pulsatile blood supply of the studied segment. Furthermore, electrical impedance provides information about the biomechanical properties of

blood vessels. As far as eye electrical impedance is concerned, a special technique, called rheophthalmography (ROG), was developed (Avetisov, 1967; Lazarenko, 1999; Lazarenko, 2004). The authors of subsequent research in the field, including those of the present study (Luzhnov et al., 2015; Luzhnov et al., 2017) described one of the varieties of ROG, the transpalpebral rheophthalmography (TP ROG), in which the electrodes are superimposed on a closed eyelid. The results of mathematical modeling were used as part of the development of this technique, taking into account the anatomical structure of the vascular bed of the eyeball (Shamaev, 2017; Shamaev, 2018). Eye blood flow during the development of myopia was studied, which showed the applicability of this technique for early diagnosis of myopia progression in children (Iomdina, 2014; Luzhnov, 2015). It should be emphasised that low and moderate myopia affects most of all the blood flow of the anterior eyeball structures.

^a <https://orcid.org/0000-0003-1111-7063>

In the case of primary open-angle glaucoma (POAG), even in its early stages, changes of blood flow are observed in all parts of the eye (Cherecheanu, 2013). As is well known, this disease is one of the leading causes of blindness (Quigley, 2006). Currently, the pathogenesis of POAG is mostly associated with increased individual level of intraocular pressure (IOP). Increased IOP damages the optic nerve fibers and cells of the retina, which gradually leads to an irreversible loss of vision. However, not only an irremediable IOP level but also other factors can lead to the development and progression of POAG. One of the risk factors of progressive visual impairment due to this disease is a decrease in the blood supply level in the vessels of the brain and the eye (Schmetterer, 2015). Eye hemodynamics monitoring in POAG patients may give useful diagnostic information for glaucoma clinicians.

A number of studies, described in (Luzhnov, 2018), were carried out on the analysis of TP ROG signals in patients with POAG. It was shown that the estimation of amplitude parameters became more informative if waveform analysis is used. So, the analysis of electrical impedance signals in POAG must include a qualitative and quantitative estimation. A qualitative analysis of signals includes determining the type of the pulse wave. It is affected by biophysical, biomechanical and hydrodynamic factors, which subsequently determine the diagnostic result in the qualitative analysis of signals. At the moment, the analysis of the pulse wave shape in TP ROG is carried out using attractors (Luzhnov, 2018). This analysis allows indirect evaluation of blood flow in different parts of the eye, as well as their interaction with each other. On the whole, however, the issue of quantitative determination of blood flow indices in all (not only the anterior) parts of the eye using non-invasive electrical impedance methods remains unresolved. It is especially vital for early diagnosis of POAG and differentiation of the POAG stages.

The aim of this work, therefore, is to develop the ROG technique, which could ensure quantitative analysis of electrical impedance signals of the posterior part of the eye in patients with POAG, including the possibility of early diagnosis of the disease and differentiation between its stages.

2 MATERIALS AND METHODS

Currently, various methods are used to study the blood supply of eye structures (Kuryshva, 2017). The electrical impedance diagnostic method allows a

comprehensive assessment of blood flow state in the eye vessels as a whole, in contrast to research methods that determine the blood supply of each vessel individually. The technique of TP ROG involves a quantitative assessment of blood supply at the depth of sounding corresponding to the anterior part of the eye (Luzhnov, 2015). Therefore, a new technique for applying electrodes for the assessment of posterior eye pole hemodynamic parameters of POAG patients was used in the present work.

To reach the posterior eye pole vascular bed (Roebuck, 2015), the estimated sounding depth should be increased. Accordingly, we used increased distance between the ROG measuring electrodes, and their location was changed: the axis of symmetry was rotated 90° relative to that used in the previous ROG technique and was located vertically rather than horizontally (see Fig.1).

The vertical orientation with the arrangement of four electrodes (a pair of current electrodes and a pair of measuring ones) in the tetrapolar system of leads allowed us to provide the desired interelectrode distance during its superimposition. The distance between the electrodes was controlled by a rigid fastening system, made similarly to the method described in (Kiseleva, 2020).

To register the TP ROG signal, a semi-rigid substrate was used for attaching the electrodes. A pair of measuring electrodes was located at a distance of 13 mm from each other. This enables measuring the blood flow at a distance corresponding to the anterior part of the eye. To register the ROG PP signal, we use an ABS plastic plate with holes for electrodes. A pair of ROG PP measuring electrodes is spaced 60 mm apart. Thanks to this arrangement we are able to measure blood flow at the depth corresponding to the posterior pole of the eye. Such system parameters enable the registration of an electrical impedance signal produced by blood supply of both the posterior and the anterior part of the eye.

The distance between the round electrodes was considered the distance between their centres, or attachment points. In preliminary studies, the selected methods of applying electrodes to adult patients and children aged 8 years or older were tested. The accuracy of positioning and the quality of electrode placement made it possible to register ROG signals for subsequent analysis of ocular blood flow.

To register the signals, an impedance measuring transducer with a probe current frequency of 100 kHz was used. The signal analysis of the ROG pulse blood supply was carried out after filtering the obtained electrical impedance signal with a Butterworth fourth-order band-pass filter with a lower cut-off

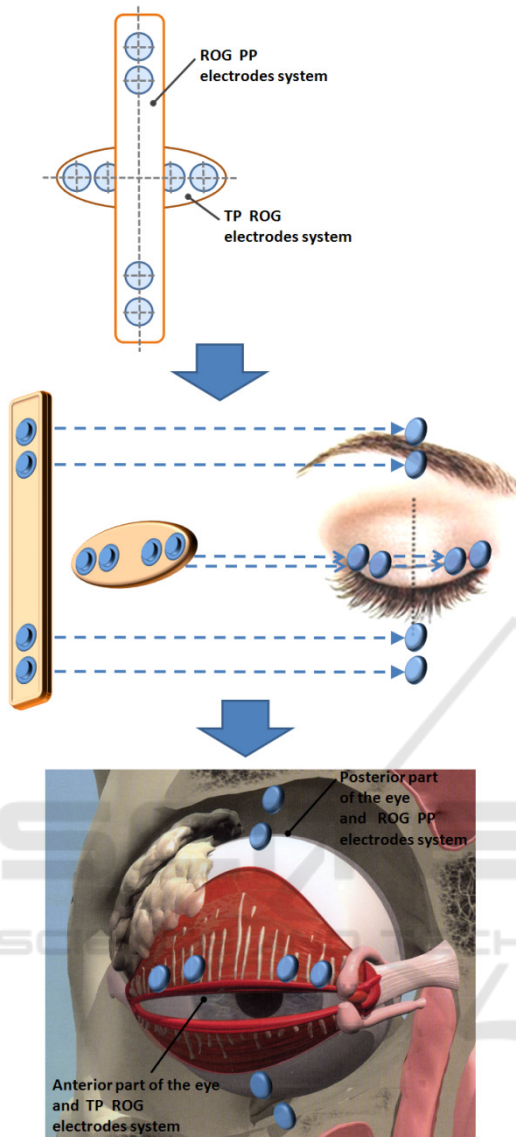


Figure 1: The location of two tetrapolar electrodes systems: transpalpebral for anterior part of the eye (TP ROG) and rotated for posterior part of the eye (ROG PP).

frequency of 0.15 Hz and an upper cut-off frequency of 100 Hz. The signal was recorded for 20 seconds. The amplitude of the ROG signal was determined as the arithmetic mean of the amplitudes of all pulse waves included in the 20-second recording period. A frequency band below 0.15 Hz determined the level of blood flow by the amplitude of the base impedance signal. To achieve this, the initial signal was filtered with a second-order Chebyshev filter. As a result, when analysing the ROG signals, two indicators were calculated: the amplitude of the pulse wave, or the rheographic index (RI), and the value of the base impedance (BI). An example of electrical impedance

signal registration for the posterior part of the eye (ROG PP) is shown in Fig.2.

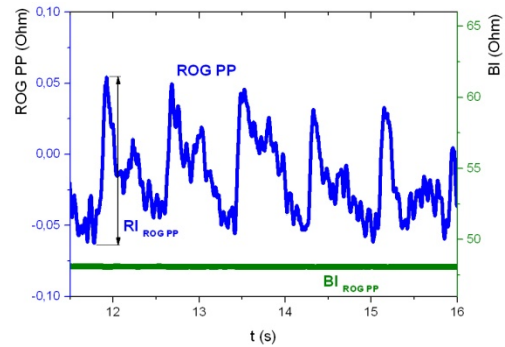


Figure 2: An example of ROG PP signal in a patient with stage I POAG.

The study was conducted in the glaucoma department of the Hemholtz National Medical Research Center of Eye Diseases. In total, ROG PP signals of 32 patients (42 eyes) averagely aged 67.7 years were analysed. Of these, 6 patients (10 eyes, average age 62.7 years) had stage I (early) POAG or suspected POAG; 13 patients (17 eyes, average age 69.4 years) had stage II (developed) POAG; 10 patients (12 eyes, average age 70.0 years) had stage III (advanced) POAG; 3 patients (3 eyes, average age 69.3 years) had stage IV (terminal) POAG.

This study was performed in accordance with the Declaration of Helsinki and was approved by the Local Committee of Biomedical Ethics of the Moscow Hemholtz National Medical Research Center of Eye Diseases. A written informed consent was obtained from all participants.

3 RESULTS

It was found that in the examined groups of patients, the average value of the RI indicator increases with the severity of the disease (from stage I to III, see Table 1). In stage IV, the average RI indicator fell slightly. An increase was also established in the average value of the BI indicator with POAG progression from stage I to stages II and III. The increase was even more significant at stage IV of the disease.

The increase of BI indicator reflects a drop in the total blood supply in eye tissues. Our study showed two characteristic changes of this indicator. The first was observed when POAG progressed from stage I to more advanced stages whilst the second change took place with the onset of stage IV POAG.

Table 1: RI and BI indicators in the examined groups (M±SD).

Stage of POAG	RI, Ohm	BI, Ohm
I	0.11±0.02	46.1±9.7
II	0.13±0.03	52.7±10.4
III	0.14±0.03	51.2±10.9
IV	0.10±0.04	57.3±10.3

In addition to averaging the diagnostic indices by study groups, they were also compared for patients with different stages of POAG in the right and the left eye. In total, ROG PP signals of five patients were analysed; five pairs of ROG records were examined. In this case, similar proportions were observed but the values were higher. For example, the RI of the eye after antiglaucoma surgery and the non-operated eye of the same patient was approximately 2.6 times different.

4 CONCLUSIONS

The results obtained in the study confirm the feasibility of the method of applying electrodes proposed in the work for ROG signals registration. The signals recorded in such a way are informative for hemodynamics assessment in POAG patients, which can be used for early diagnostics of POAG and differentiation between its stages. The difference in hemodynamic parameters observed between the fellow eyes with different POAG stages of the same patient confirms the efficiency of the new technique.

As a further development of this work, the authors consider a joint study of ROG signals recorded simultaneously using different leads, which will allow us to differentiate the changes in the level of blood flow depending on the depth of sounding, and, consequently, on the part of the eye.

When using a device in which the ROG signal is recorded transpalpebrally through one channel with a tetrapolar lead system installed on the eyelid, and through a second channel with a tetrapolar lead system installed symmetrically with respect to the anteroposterior axis of the eye on the face in the area of the eye socket, it becomes possible to expand the existing facilities of the electric impedance diagnostics of the ocular blood flow.

A simultaneous analysis of electrical impedance signals through two channels, TP ROG and ROG PP, makes it possible to estimate the level of blood flow in the anterior part of the eye by the signal of the first channel and in the posterior part of the eye by the signal received from the second channel.

A research into the relationship between blood flow in the anterior and posterior parts of the eye at different stages of glaucoma is also interesting for understanding the pathophysiological processes of the development of this disease.

CONFLICT OF INTEREST

The authors declare that they have no conflict of interest. The paper was supported by a grant from RFBR (No.18-08-01192).

REFERENCES

- Avetisov, E.S., Katsnel'son, L.A., Savitskaia, N.F., 1967. Rheocyclographic examinations in myopia. *Vestnik Oftalmologii* 80(3): 3–7.
- Bodo, M. (2010) Studies in Rheoencephalography. *Journal of Electrical Bioimpedance* 1, 18–40.
- Cherecheanu A.P., Garhofer G., Schmidl D., Werkmeister R., Schmetterer L., 2013. Ocular perfusion pressure and ocular blood flow in glaucoma. *Curr Opin Pharmacol* 13: 36–42. DOI:10.1016/j.coph.2012.09.003
- Iomdina, E.N., Luzhnov, P.V., Shamaev, D.M., et al., 2014. An evaluation of transpalpebral rheoophthalmography as a new method of studying the blood supply to the eye in myopia. *Russian ophthalmological journal* 7(4): 20–24. (in Russian)
- Kiseleva, A.A., Luzhnov, P.V., Shamaev, D.M., 2020. Verification of mathematical model for bioimpedance diagnostics of the blood flow in cerebral vessels. *Advances in Intelligent Systems and Computing* 902: 251–259. DOI: 10.1007/978-3-030-12082-5_23
- Kuryshva, N.I., Parshunina, O.A., Shatalova, E.O., et al., 2017. Value of structural and hemodynamic parameters for the early detection of primary open-angle glaucoma. *Curr. Eye Res.* 42(3): 411–417.
- Lazarenko, V.I., Komarovskikh, E.N., 2004. Results of the examination of hemodynamics of the eye and brain in patients with primary open-angle glaucoma. *Vestnik oftalmologii* 120(1): 32–36. DOI:10.21687/0233-528X-2017-51-3-22-30
- Lazarenko, V.I., Kornilovsky, I.M., Ilenkov, S.S. et al., 1999. Our method of functional rheography of eye. *Vestnik oftalmologii* 115(4): 33–37.
- Luzhnov, P.V., Shamaev, D.M., Iomdina, E.N. et al., 2015. Transpalpebral tetrapolar rheoophthalmography in the assessment of parameters of the eye blood circulatory system. *Vestn Ross Akad Med Nauk* 70(3): 372–377. DOI: 10.15690/vramn.v70i3.1336
- Luzhnov, P.V., Shamaev, D.M., Iomdina, E.N., et al., 2017. Using quantitative parameters of ocular blood filling with transpalpebral rheoophthalmography. *IFMBE Proceedings* 65: 37–40. DOI:10.1007/978-981-10-5122-7_10

- Luzhnov, P.V., Shamaev, D.M., Kiseleva, A.A., et al., 2018. Using nonlinear dynamics for signal analysis in transpalpebral rheophthalmography. *Sovremennye tehnologii v medicine* 10(3): 160–167. DOI: 10.17691/stm2018.10.3.20
- Patterson, R. (2005) Electrical Impedance Tomography: Methods, History, and Applications (Institute of Physics Medical Physics Series), *Physics in Medicine and Biology* 10: 2427–2428.
- Quigley, H.A., Broman, A.T., 2006. The number of people with glaucoma worldwide in 2010 and 2020. *Br J Ophthalmol* 90(3): 262–267.
- Roebuck, J., 2015. *Anatomy 360: The Ultimate Visual Guide to the Human Body*. Thunder Bay Press, San Diego.
- Schmetterer L., 2015. Ocular perfusion abnormalities in glaucoma. *Russian Ophthalmological Journal* 4: 100–109.
- Shamaev, D. M., Luzhnov, P. V., Iomdina, E. N., 2018. Mathematical modeling of ocular pulse blood filling in rheophthalmography. *IFMBE Proceedings* 68(1): 495–498. DOI: 10.1007/978-981-10-9035-6_91
- Shamaev, D.M., Luzhnov, P.V., Iomdina, E.N., 2017. Modeling of ocular and eyelid pulse blood filling in diagnosing using transpalpebral rheophthalmography. *IFMBE Proceedings* 65: 1000–1003. DOI:10.1007/978-981-10-5122-7_250

