

Urticaria Pigmentosa in Children: A Case Report

Syafria Zidni^{1*}, Elin Herlina¹, Retno Indar Widayati¹, Diah Adriani Malik¹,
Meira Dewi Kusuma Astuti²

¹Department of Dermatology and Venereology, Diponegoro University/Dr. Kariadi Hospital

²Departement of Pathology and Anatomical, Diponegoro University/Dr. Kariadi Hospital

*Corresponding author

Keywords: Urticaria pigmentosa, mast cell, ketotifen.

Abstract: Mastocytosis is a disorder of abnormal mast cell proliferation presented as an abnormal accumulation of mast cells in various tissues. Urticaria pigmentosa (UP) is the most common form of this disorder in children, particularly in the first year of life. Darier's sign is pathognomonic for UP. Management for UP consists of patient education, triggering factors exposure prevention and symptomatic treatment to reduce the release of mast cells mediator. A 5-year-old girl presented with brown spots and itch in various area of the body with dry skin. Physical examination found multiple hyperpigmented macules on her body, arms, legs and face. Darier's sign was positive. Histopathology examination demonstrated mast cell granules in the superficial layer of dermis with Giemsa staining, consistent with the diagnosis of UP. There is no systemic involvement. Patient was treated with ketotifen syrup, 10% urea cream, and betamethasone valerate 0,1% cream for the erythema lesions. Ketotifen is a mast cell stabilizer that was given to relieve the symptoms of UP. Urea was given to reduce dry skin and enhance the absorption of betamethasone. Betamethasone was given to reduce the lesions of UP. After 12 weeks, patient showed some improvement in her pruritus and skin dryness. The prognosis was *quo ad vitam, quo ad sanam and quo ad cosmeticam dubia ad bonam.*

1 INTRODUCTION

Mastocytosis is a disorder of abnormal mast cell proliferation presented as an abnormal accumulation of mast cells in various tissues, include the skin and/or bone marrow. There are two types of this disease, cutaneous mastocytosis and systemic mastocytosis (Wagner et al, 2017; Tharp, 2012). Urticaria pigmentosa is the most common form of cutaneous mastocytosis in children with onset in the first year of life, generally below two years of age (Tharp, 2012; Vasani et al, 2015).

Mastocytosis is rare. The incidence of 2 cases per 300.000 people per year is estimated and may be observed in all ethnic group. The disease is higher predominant in children and in adults between the third and fourth decade of life. Children are more affected before the age of six months in 50% of the cases. There is no gender predilection (Wagner et al, 2017; Pires et al, 2018).

In patients with urticaria pigmentosa, there is an abnormality in stem cell factor (SCF) metabolism

that affects in cell mast proliferation and differentiation. SCF which is bound with membrane was released, causing an increase of dissolved SCF, and when accumulated it will stimulates melanocyte to produces melanin (Tharp, 2012; James et al, 2011). In the other side, mast cells contain histamine to be released which can cause redness on the skin, swollen, and itchy (Tharp, 2012).

Urticaria pigmentosa lesions appear as multiple, fixed, reddish-brown, hyperpigmented macules, papules, and nodules that have a tendency to coalesce into plaques and often exhibit increased skin markings (Prose et al, 2008). In children, these lesions may be present at birth or arise during infancy. They frequently appear on the trunk and often spare the central face, scalp, palms, and sole. Rubbing or trauma of the affected skin results in a weal with flare (Darier sign) in more than 90% of patients. The diagnosis may be confirmed by skin biopsy and histopathology examination that shows mast cell infiltrates indicated with metachromatic granules in cytoplasm using special stains, such as

Toluidine or Giemsa (Tharp, 2012; Vasani et al, 2015; Gysel et al, 2011; Rapini, 2012).

The management of patients with urticaria pigmentosa consists of patient education, triggering factors exposure prevention and symptomatic treatment to reduce the release of mast cells mediator (Tharp, 2012; Gysel et al, 2011; Grattan et al, 2010). Pediatric-onset urticaria pigmentosa has a favorable prognosis because the lesions usually disappear within a few years, usually before puberty, although in a few cases the lesions may persist into adult life (Tharp, 2012; Vasani et al, 2015; Prose et al, 2008).

This case report was made with the aim of better understanding about diagnosis and management of urticaria pigmentosa in children which is relatively rare.

2 CASE

A girl who was taken to the Dr Kariadi General Hospital Medical Center by her parents presented with brown patches on some parts of her body. Based on her parent's recollection, the spots first manifested when the patient was 4 months old. The lesion started as red patches on the patient's back, which sometimes was accompanied by itching especially when she was sweating, causing her to habitually scratches her body. Eventually the patches expanded to her face, neck, arms, trunk, and legs. The color of the patches gradually became darker and brown, accompanied by dry skin. There was no family history a similar disease.

Physical examination showed that the patient was in an excellent health condition, has normal general health status, with a weight of 17 kg. The dermatologic examination found erythematous and hyperpigmented macular eruption, with fine scales on the face, neck, trunk, arms and legs. Positive Darier's sign.

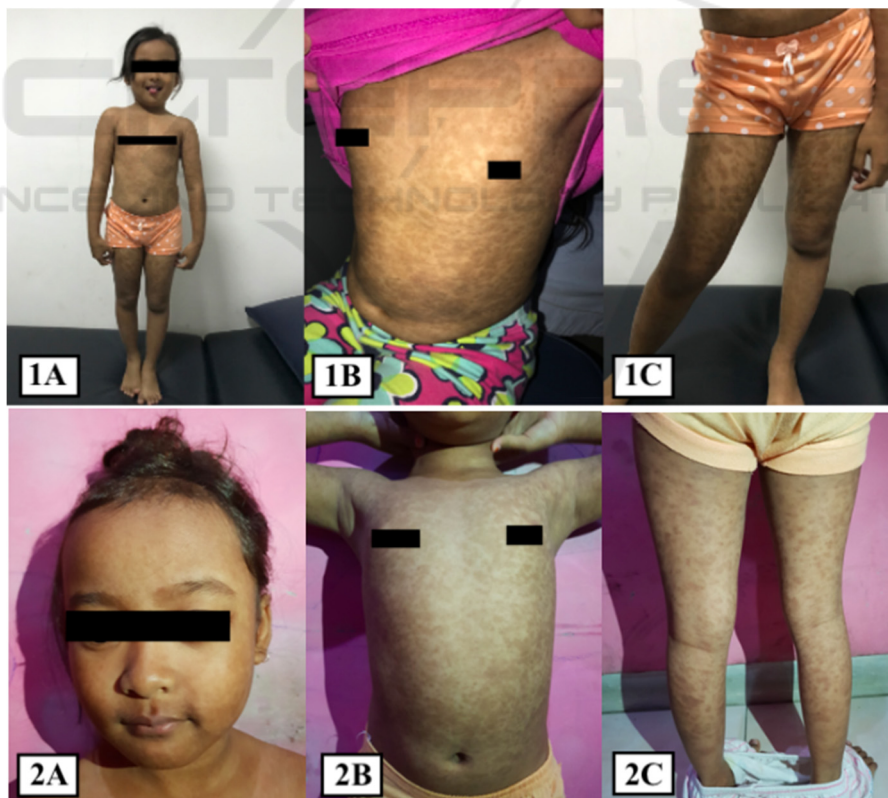

Figure 1: A,B,C. Generalized hyperpigmented macules before treatment. 2A,B,C. After 12 weeks treatment.

Laboratory tests found no abnormalities. Histopathological examination by the use of special Giemsa stain has found granulated mast cells in the superficial dermal layer, consistent with the diagnosis of mastocytosis. There were no systemic abnormalities.

The patient was treated with Ketotifen syrup 1 mg bid, Urea 10% cream and Betamethasone cream. The parents were also educated to avoid some known triggering factors. Itching and dry skin has showed some improvements after 12 weeks of treatment. The patient was expected to have spontaneous resolution at puberty.

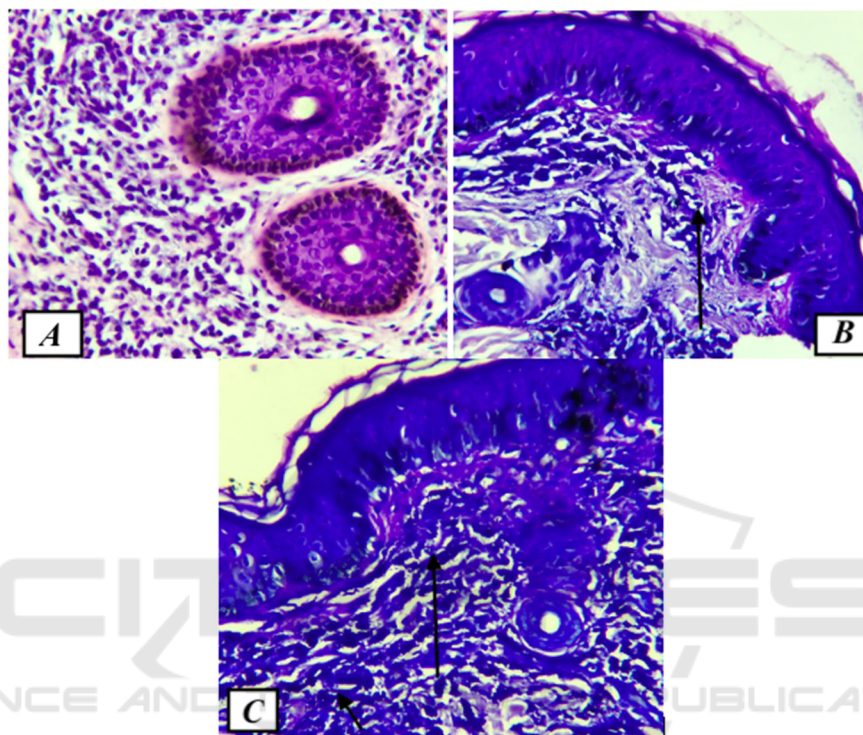


Figure 2. A. Lymphocyte infiltration, histiocyte, and mast cell around skin adnexa. B & C. Mast cell granule (Giemsa, 400x)

3 DISCUSSION

UP was diagnosed based on the medical history, clinical examination and histopathological examination.

Based on the medical history, a 5-year-old girl was taken to the Dr Kariadi General Hospital Medical Center by her parents with brown patches on some parts of her body. The spots first manifested when the patient was 4 months old. The lesion started as red patches on the patient's back, which sometimes was accompanied by itching especially when she was sweating, causing her to habitually scratches her body. Eventually the patches expanded to her face, neck, arms, trunk, and legs. The color of the patches gradually became darker and brown, accompanied by dry skin. There was no family history a similar disease. The literature

specified that UP is the most common variant of pediatric mastocytosis, with onset in the first year of life. The lesion usually manifested before the second year of life, and the disease is usually confined to the skin. There were no difference in prevalence between male and female, all race can be affected. (Tharp, 2012; Vasani et al, 2015; Pires et al, 2018)

The physical examination found erythematous macular lesion, hyperpigmented macular lesion, and fine scales on the face, neck, trunk, arms and legs. Positive Darier's sign. The literature mentioned that UP usually manifested as reddish-brown patches, papules, nodules, or plaques, with positive Darier's sign, where rubbing or scratching may cause the formation of urticarial lesions surrounded with areas of erythema. The lesion is usually distributed on the trunk, but it may manifested on other body parts, or even widespread (generalized). The lesion is usually accompanied by itching, but there are no signs and

symptoms of systemic mastocytosis, such as gastrointestinal problems, lymphedema, or skeletal abnormalities. Pediatric consult found no systemic involvements. This result corresponded with the literature that specified that pediatric UP is mostly confined to the skin, and rarely shows systemic involvements. (Tharp, 2012; James et al, 2011). Blood laboratory examination found no abnormalities. Histopathological examination by the use of special Giemsa stain has found purplish stained granulated mast cells in the superficial dermal layer. The literature mentioned that UP can be diagnosed based on the result of skin biopsy and histopathological examination by the use of special stain to clearly examine the mast cells, such as Giemsa or Toluidine Blue stain. (Tharp, 2012; Vasani et al, 2015; Gysel et al, 2011; Rapini, 2012).

Differential diagnosis of juvenile xanthogranuloma can be excluded because the lesions are mostly soft, well-defined papules or nodules. The lesions are red-orange or red-brown in color, and then it may change into yellowish color. The lesions are mostly found at the upper body, and in children, the lesion will spread quickly and then spontaneously regress in approximately a year. (Gelmetti, 2012; Burgdorf et al, 2010)

Differential diagnosis of Spitz nevus can be excluded because the lesions are mostly red to dark brown, flat, smooth, hairless, hard, well-defined papules or nodules, with the distribution in the head and neck region. (Grichnik et al, 2012; James et al, 2011)

The current case was treated with Ketotifen syrup 1 mg bid, Urea 10% cream and Betamethasone valerate 0,1% cream. The parents were also educated to avoid some known triggering factors, such as temperature change, physical activity, food, and nonsteroidal anti-inflammatory drugs, and to avoid scratching or trauma to the skin. The literature mentioned that the treatments are usually symptomatic. Ketotifen is a mast-cell stabilizer that has been shown to be effective in reducing urtica and pruritus in patients with UP. Urea 10% cream helps to moisturize the skin and prevent dryness, and to improve the absorption of Betamethasone valerate 0,1% cream. Very potent topical corticosteroid applied with occlusion for 8-12 weeks may reduce the number lesions in UP. The current case was treated with betamethasone valerate 0,1% cream, a medium potency topical corticosteroid, that was applied to the erythematous lesions only to alleviate the skin lesions. After 12 weeks of treatment, there were no new lesions, itching was reduced, and there was no skin dryness.

(Wagner et al, 2017; Tharp, 2012). The prognosis of the current patient was, *quo ad vitam* and *quo ad sanam dubia ad bonam* because there were no systemic involvement and the patient was expected to have spontaneous resolution before puberty, *quo ad cosmeticam dubia ad bonam* because of the remaining hyperpigmented macules. (Wagner et al, 2017; Tharp, 2012; Prose et al, 2008).

4 CONCLUSION

A case of Urticaria Pigmentosa treated with ketotifen, urea, and betamethasone has been reported that can reduce the complaint and lesions.

REFERENCES

- Burgdorf WH, Zelger B. 2010. *The Histiocytoses*. In: Elder DE, Elenitsas R, Johnson BL, Murphy GE, Xu X, editor. *Lever's histopathology of the skin*, 10th ed. Philadelphia: Lippincott Williams and Wilkins. p.1520-65.
- Gelmetti C. 2012. *Non-Langerhans Cell Histiocytosis*. Goldsmith LA, Katz SI, Gilchrist BA, Paller AS, Leffel DJ, Wolff K, editors. *Fitzpatrick's Dermatology in General Medicine*, 8th ed. New York: McGraw-Hill. p.1795-1808.
- Grattan CE, Black AK. 2010. *Urticaria and mastocytosis*. In: Burns T, Breathnach S, Cox N, Griffiths C, editors. *Rook's Textbook of Dermatology*, 8th ed. United Kingdom: Wiley-Blackwell. p.22.30-22.36.
- Grichnik JM, Rhodes AR, Sober AJ. 2012. *Benign neoplasias and hyperplasias of melanocytes*. In: Goldsmith LA, Katz SI, Gilchrist BA, Paller AS, Leffel DJ, Wolff K, editors. *Fitzpatrick's Dermatology in General Medicine*, 8th ed. New York: McGraw-Hill. p. 1377-410.
- Gysel DV, Schaik RH, Oranje AP. 2011. *Mastocytosis*. In: Irvine AD, Hoeger PH, Yan AC, editors. *Harper's Textbook of Pediatric Dermatology*, 3rd ed. United Kingdom: Wiley-Blackwell. p.832-46.
- James WD, Berger TG, Elston DM. 2011. *Mastocytosis*. In: James WD, Berger TG, Elston DM. *Andrews' Diseases of The Skin Clinical Dermatology*, 11th ed. China: Saunders Elsevier. p.605-9.
- James WD, Berger TG, Elston DM. 2011. *Melanocytic nevi and neoplasms*. In: James WD, Berger TG, Elston DM. *Andrews' Diseases of The Skin Clinical Dermatology*, 11th ed. China: Saunders Elsevier. p.675-9
- Pires CG, Filho JFS, Azzouz MA. 2018. *Cutaneous mastocytoma in childhood: case report*. *Journal of Dermatology and Cosmetology*. 2(1):9-10.
- Prose NS, Antaya RJ. 2008. *Neoplastic and infiltrative diseases*. In: Eichenfield LF, Frieden IJ, Esterly NB,

- editors. Neonatal Dermatology, 2nd ed. Philadelphia: Saunders Elsevier. p. 467-8.
- Rapini RP. 2012. *Practical dermatopathology*, 2nd ed. China: Saunders Elsevier. .p.347-9.
- Tharp MD. 2012. *Mastocytosis*. In: Goldsmith LA, Katz SI, Gilchrist BA, Paller AS, Leffel DJ, Wolff K, editors. *Fitzpatrick's Dermatology in General Medicine*, 8thed. New York: McGraw-Hill. p. 1809-18.
- Vasani RJ, Medhekar SV. 2015. *Urticariapigmentosa*. *Indian Dermatology Online Journal*. 6(6):464-5.
- Wagner N, Staubach P. 2017. *Mastocytosis – pathogenesis, clinical manifestation and treatment* .*Journal of the German Society of Dermatology*. 42-57.

