

Cutaneous Sarcoidosis with Nail Manifestations: A Rare Finding

Firman Parrol^{1*}, Karin Rachmani¹, Sri Linuwih Menaldi¹, Sondang P. Sirait¹, Eliza Miranda¹

¹Department of Dermatology and Venereology, Faculty of Medicine, University of Indonesia/Dr. Cipto Mangunkusumo National Central General Hospital, Indonesia

Keywords: Sarcoidosis, nail sarcoidosis, cutaneous sarcoidosis

Abstract: Sarcoidosis is a multisystem granulomatous disease, characterized by naked granuloma lesions with multiorgan involvement such as the lung, skin, eye, liver, peripheral lymph nodes and, nail. Cutaneous sarcoidosis is one of the most common findings, while nail sarcoidosis presents with a very low incidence. We report a 46-years-old male patient, referred to the Department of Dermatology and Venereology CiptoMangunkusumoHospital with enlarged erythematous plaque lesions on the ear and nose since three months ago. Our patient also showed dystrophy and onycholysis of toenails. Erythematous plaque lesions are a hallmark of chronic sarcoidosis, while nail involvement is closely linked with chronic and systemic sarcoidosis. Furthermore, skin and nail biopsies also showed naked granuloma lesions. These findings strengthen our evidence of sarcoidosis, specifically chronic sarcoidosis. Although nail sarcoidosis is found in our patients, there is internal organ involvement. Therefore, a stepwise approach needs to be done to diagnose nail sarcoidosis.

1 INTRODUCTION

Sarcoidosis is a systemic granulomatous disease with multiple organ involvement. Sarcoidosis may manifest in organs such as the lung, skin, eye, liver, cardiovascular, gastrointestinal, urogenital, kidney, peripheral lymph nodes, and nail. (Haimovic A 2012). On the skin, sarcoidosis can be classified into specific and non-specific lesions. If skin biopsy revealed naked granulomas, it is classified as specific lesion. Whereas, non-specific lesions usually seen in erythema nodosum. (Mana J et al., 2012). Cutaneous sarcoidosis is one of the most common form of sarcoidosis. Lesions most often are found on the head and neck, both symmetrically or asymmetrically on any part of the skin and mucosa. Although incidences are very low, sarcoidosis can also appear in other locations, one of them is nail. (Mana J et al., 2012). Despite its rarity, dermatologists must consider nail sarcoidosis as a serious problem because its chronic nature and related to systemic disease. (Momen SE et al., 2013). In this paper we report cutaneous sarcoidosis with nail manifestation which is a rare finding. However, systemic involvement is not yet discovered.

2 CASE

A 46-years-old man was referred with enlarged erythematous plaque lesions in the ear and nose since three months ago. The lesion first appeared two years ago on the right ear with nummular size. Since then, the lesion spread to the whole auricle of left ear. Three months later, erythematous plaque lesion also appeared on the anterior nares. The patient observed that the lesion size was progressing over time. There was no history of pain, itching, loss of sensation, or bleeding. The patient then came to dermatologist and he was given mupirocin cream and wet dressing of potassium permanganate for one year. However, the condition did not resolve after the treatment.

After one year of the initial lesion on the ear, patient complained a disfiguration on the nail. Initial changes were observed in both toes. Both of the nails were damaged accompanied by swollen toes. This was also observed on the fourth right toes and the fifth left toes. There were no history of pain, itch, bleeding or trauma before. The patient was referred to dermatologists who diagnosed him with fungal infection of the nail. He was given loprox® for six months but there was no improvement. The patient

then referred to another dermatologist who suspected him with Leprosy. The patient then transferred to CiptoMangunkusumoCentral General Hospital for slit skin smeaexamination. There was no history of chronic cough, dyspnea, heart disease, fever, arthralgia, or ocular disorder. There were no night sweats or significant weight reduction. There was no history of any similar disease in patient’s family. In 2013, patient was diagnosed with astrocytoma at the spinal cord. According to patient, the diagnosis was made based on MRI. The astrocytoma paralyzed patient from the waist to the feet. The sensory, motoric and autonom nerves were damaged.

Physical examinations showed multiple erythematous plaques with rough scales were seenin both ears. The lesions werevary in size from lenticular to nummular, arranged discreteand some of them was confluent with well demarcated borders. On the nosethere was a solitary nummular circumscribed erythematous plaque with soft consistency. (Figure 1) Dermoscopic examination revealedorange color on skin lesion. Onycodistrophy, onycholysis and digital clubbing were observed on the fourth and first finger of the right foot and the first and fifth finger of the left foot. (Figure 2) On dermoscopic evaluation, there were splinter hemorrhage on the nail bed. Multiple atypical vesselswere found on the fourth nail of the right foot. (Figure 3)

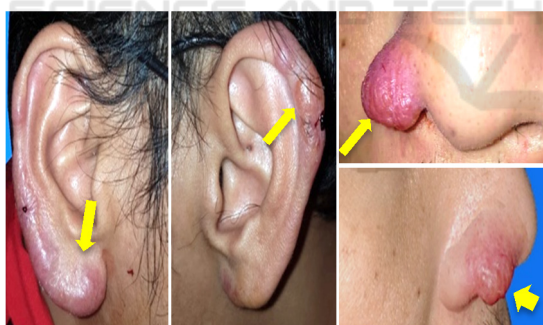

Figure 1. Multiple erythematous plaques were seen on both ear and nose. (Arrows)

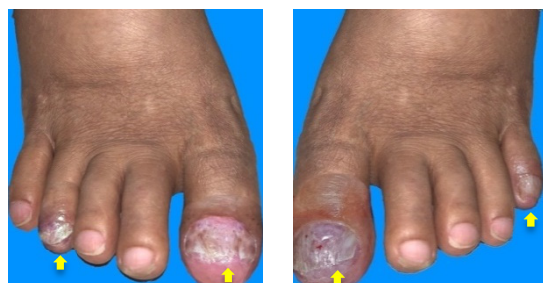

Figure 2. Nail dystrophy and onycholysis. (Arrows)

Based on history taking and physical examination, the differential diagnosis were lupus vulgaris, cutaneous sarcoidosis and cutaneous lymphoma. In order to confirm our diagnosis, the *Mycobacterium tuberculosis* (MTB), *Mycobacterium Other Than Tuberculosis* (MOTT) culture and polymerase chain reaction (PCR) obtained from skin tissue was done. The results of MTB and MOTT culture were negative, but PCR was positive for *Mycobacterium tuberculosis*. Histopathological examination of the nose revealed the epidermis of had flat rete ridges. Epithelioid granuloma was observed in the dermis with multiple giant cells surrounded by sparse lymphocytes infiltrates. Nearby tissue was dominated by inflammatory cells and areas of fibrosis. (Figure 4) On the other hand, histopathological examination of the nail bed revealed acanthotic and irregular elongation of the rete ridges. Epithelioid granuloma was also observed in the dermis of the nailbed and the proximal nail fold under the matrix. (Figure 4) ZiehlNielhsen staining showed no sign of acidfast bacilli on the nose and nail specimen. Chest x-ray examination revealed no sign of sarcoidosis or TB infection in the lung, while x-ray examination on patient's foot showed erosion on distal phalanx of both thumb with osteolytic process on metatarsal and phalanx of first finger, distal tibia and tarsal. No sign of destruction was found.

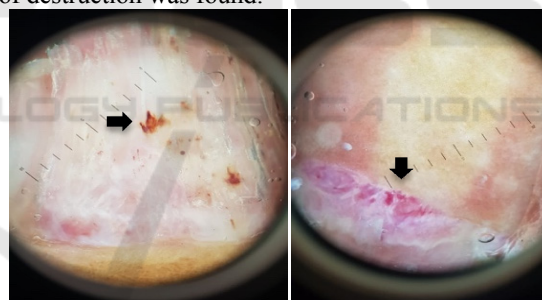


Figure 3. Splinter hemorrhage and multiple atypical vessels on the toes. (Arrows)

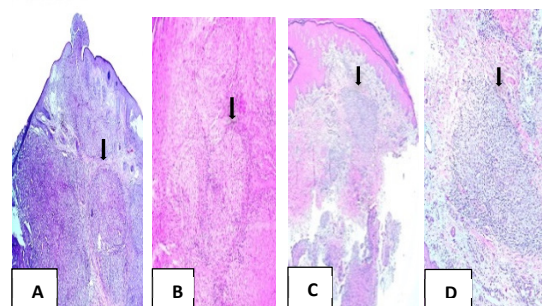


Figure 4. A, B. Epithelioid granuloma was observed in the dermison plaque of the nose with multiple giant cells surrounded by sparse lymphocytes infiltrates. (Arrows).C, D. Epithelioid granuloma was also observed in the dermis of the nailbed and the proximal nail fold under the matrix. (Arrows)

3 DISCUSSION

Cutaneous sarcoidosis are classified into specific lesions with histopathological findings of naked granulomas, and nonspecific lesion that appear from a process that does not form granulomas. (Haimovic A, 2012) Skin manifestation are present in one fifth of sarcoidosis. Differentiating these lesions is important because cutaneous lesions have a prognostic significance. (Mana J et al., 2012). Nonspecific lesion such as erythema nodosum typically associated with good prognosis and spontaneous resolution while maculopapular lesions and subcutaneous lesions are linked with remission of systemic disease in two years. (Mana J et al., 2012). Whole plaques and lupus pernio are closely associated with chronic disease. (Mana J et al., 2012). The last type of lesions are disfiguring and can have cosmetic, social, and psychological impact. (Mana J et al., 2012).

Cutaneous lesions are found on our patient's nose and both ears. These lesions are identified to be erythematous plaque lesions. It is known that plaque lesions are typically persistent and associated with chronic forms of sarcoidosis. (Mana J et al., 2012). It is consistent with the findings in our patients, whose lesions appeared since two years ago, therefore indicating a chronic form of sarcoidosis. Relatively symmetric plaques and nodules that occur on the nose, earlobes, cheeks, and digits, are consistent with lupus pernio, which has a tendency for systemic involvement. Nail changes are hardly found in sarcoidosis. (Momen SE et al., 2013). However, when present, it is closely associated with systemic sarcoidosis. The prevalence of nail sarcoidosis was reported (1.6%) of 188 patients with cutaneous sarcoidosis. (Velen NK et al., 1987) Despite its rarity, dermatologists must consider nail sarcoidosis as a sign of chronic systemic disease. (Momen SE et al., 2013). One paper reviewed 33 patients with nail sarcoidosis to describe the changes of nail.³ The most common findings included nail dystrophy, longitudinal ridges, subungual hyperkeratosis, onycholysis, nail hyperkeratosis and nail loss consecutively. Confirmation of sarcoidosis was made from histopathological findings from of the nail biopsies, which were the presence of naked granulomatous. Among 33 patients, seven patients are noted to have granulomatous infiltrates of the dermis. (Losada-Campa et al., 1995; Kalb RE et al 1985). In our patient, we also find onychodystrophy, onycholysis and digital clubbing. Histopathological examination revealed typical naked

granulomas. (Fernandez-Faith E et al., 2007). These findings point us towards nail sarcoidosis.

Wakelin and James stated that the findings of surrounding skin changes of erythematous plaques over the proximal nail folds might direct towards a diagnosis of sarcoidosis (Haimovic A et al 2012) These skin changes are caused by the formation of granulomas which have microcompressive effects in the dermal compartment between the nail plate and the phalanx. (Wakelin SH et al., 1995). Despite the nail changes and granuloma lesion in the biopsy of nail, one should have more evidence to confirm the diagnosis of sarcoidosis in this patient. Nail involvement in sarcoidosis is rare and is usually a marker of chronic disease. Although most of the cases reported are associated with digital bone cysts, sarcoid dactylitis, and lupus pernio, cases without these associations have also been described proposed that most nail changes are secondary to granulomatous compression of nail structures (Velen NK et al., 1987).

Sarcoidosis is known to be "the great imitator" because of its diverse manifestations and the ability to resemble other cutaneous disease. (Haimovic A, 2012). Therefore, a stepwise approach of diagnosis needs to be taken in every patient with granulomatous inflammation. (Chopra S et al., 1999). A stepwise approach to diagnose sarcoidosis in this patient is divided into two parts. First, excluding alternative cause of granuloma. Second, find at least one additional organ involvement. Alternative known cause of granuloma is very wide, including tuberculosis, atypical mycobacteriosis, fungal infections, reaction to foreign bodies, leishmaniasis, rheumatoid nodules, and Melkersson-Rosenthal syndrome. (Aranegui et al., 2010).

However, in this patient, another known cause of granuloma are unlikely. Granulomatous lesion is highly caused by sarcoidosis according to patient's history, negative culture of MTB, and MOTT, and normal chest x-ray examination. Although PCR showed positive for MTB, it will not affect the diagnosis because positive result can still be found in 80% of cutaneous sarcoidosis patient. Several studies have shown the presence of Mycobacterium DNA in sarcoid granuloma, suggesting previous exposure to Mycobacterium, which might have induced a granulomatous reaction. The common problem raised during PCR assays is the high risk of false positive results due to common laboratory contamination or presence of killed or dormant bacilli in the patient specimens. However, the key to the diagnosis of tuberculosis is a positive result on tissue culture which is the gold standard of

diagnosis. In our patient, tissue culture of MTB and MOTT showed negative result. Therefore, confirming cutaneous and nail sarcoidosis as our diagnosis. (Makeshkumar V et al, 2014; Brownell et al 2011).

Classic sarcoidal lesions in the small bones of the hands and feet are well characterized and diagnosed with conventional radiographs, on which they demonstrate the familiar “lacy” lytic appearance. (Moore SL et al., 2003). X-ray examination on patient's foot showed erosion on distal phalanx of both thumb with osteolytic process on metatarsal and phalanx of first finger. This x-ray finding is suggested as extracutaneous manifestation of sarcoidosis. Another suspected systemic manifestation in this patient was astrocytoma. This finding raised question whether it is an astrocytoma or granulomatous inflammation mimicking astrocytoma. Neurosarcoidosis itself has a predilection at the base of the brain or spinal cord with cranial neuropathies are the most common manifestation. Therefore, we plan to refer the patient to Neurology Department to establish the diagnosis. We also refer the patient to the Internal Medicine Department to perform more diagnostic evaluation to find involvement of other organs. We treat the patients using clobetasol propionate cream 0.05% twice a day for the lesion in the ear and nose. Lesion in the nail is treated using clobetasol propionate ointment 0.25%. Several literatures have reported the efficacy of topical steroid to improve the appearance of nail changes in 5 (15%) of the 33 patients. (Haimovic A et al., 2012; Aranegui et al., 2010).

4 CONCLUSION

Cutaneous sarcoidosis is one of the most common organs involved and appear in one third of sarcoidosis cases. Cutaneous sarcoidosis lesion has its prognostic significance. Different lesion could have a different prognostic implication. In the other hand, nail sarcoidosis is a rare manifestation of sarcoidosis. Although it is rare, one must consider the systemic involvement of sarcoidosis if the nail is affected because its chronic and systemic nature. A stepwise approach must be used to diagnose every patient with nail involvement in sarcoidosis. Documentation of additional organ involvement, such as the lung, lymph nodes, eye, heart, and nervous system is essential to diagnose nail sarcoidosis which commonly observed with multi organ involvement.

REFERENCES

- Haimovic A, Sanchez M, Judson MA, Prystowsky S. Sarcoidosis: a comprehensive review and update for dermatologist. Part 1. Cutaneous disease. *J Am Acad Dermatol.* 2012;66:699e1-18.
- Mana J, Marcoval J. Skin manifestations of sarcoidosis. *Presse Med.* 2012;41:e355-74.
- Momen SE, Al-Niaimi F. Sarcoid and the nail: review of the literature. *Clin and Exp Dermatol.* 2013; 38: 119-25.
- Veien NK, Stahl D, Brodthagen H. Cutaneous sarcoidosis in Caucasians. *J Am Acad Dermatol.* 1987; 16: 534-40.
- Losada-Campa A, De la Torre-Fraga C, de Gomez Lian˜o A, Cruces-Prado MJ. Histopathology of nail sarcoidosis. *Acta Derm Venereol.* 1995; 75: 404-5.
- Kalb RE, Grossman ME. Pterygium formation due to sarcoidosis. *Arch Dermatol* 1985; 121: 276-7.
- Wakelin SH, James MP. Sarcoidosis: nail dystrophy without underlying bone changes. *Cutis* 1995; 55: 344-6.
- Haimovic A, Sanchez M, Judson MA, Prystowsky S. Sarcoidosis: a comprehensive review and update for dermatologist. Part 2. Extracutaneous disease. *J Am Acad Dermatol.* 2012; 66: 719e1-10.
- Chopra S, Vega-López F. Skin granulomas in clinical practice. In: James DG, Zumla A, editors. *The granulomatous disorders.* Cambridge, UK: Cambridge University Press; 1999. p. 485-527.
- Aranegui B, Garcia-Cruz A, de la Torre C, González-Valladares MG. Trachyonychia and sarcoidosis. *J Am Acad Dermatol* 2010; 63: 59-60
- Makeshkumar V, Madhavan R, Narayanan S. 2014. Polymerase chain reaction targeting insertion sequence for the diagnosis of extrapulmonary tuberculosis. *Indian J Med Res*
- Brownell I, Ramírez-Valle F, Sanchez M, Prystowsky S. Evidence for Mycobacteria in Sarcoidosis. *Am J Respir Cell Mol Biol.* 2011 Nov;45(5):899-905.
- Moore SL, Terstein AE. Musculoskeletal sarcoidosis: spectrum of appearance at MRI imaging. *Radiographics* 2003; 23: 1389-99.
- Fernandez-Faith E, McDonnell J. Cutaneous sarcoidosis: differential diagnosis. *Clin Dermatol.* 2007;25(3):276-87.