

# A Rare Case of Unilateral Psoriasis with Verruca Vulgaris: Challenges in Diagnosis and Treatment

Marsha Bianti<sup>1\*</sup>, Shannaz Nadia Yusharyahya<sup>1</sup>, Sondang P. Sirait<sup>1</sup>,  
Eyleny Meisyah Fitri<sup>1</sup>, Endi Novianto<sup>1</sup>

<sup>1</sup>Department of Dermatology and Venereology, Faculty of Medicine Universitas Indonesia/  
Dr. Cipto Mangunkusumo National Central General Hospital, Indonesia

**Keywords:** HPV, Unilateral Psoriasis, Verruca Vulgaris

**Abstract:** Unilateral psoriasis is a rare clinical variant of plaque psoriasis with unclear pathogenesis. We report a 51-year old woman with a 5-year history of itchy, red, scaly patches on the unilateral right breast, arm, and leg. There were also some vegetating masses on top of the red patches on her lower right leg. Physical examination revealed multiple erythematous plaques with coarse-white scales overlying it, distributed along Blaschko lines on her right side of the body and multiple verrucous nodules on erythematous plaques on her lateral aspect of lower right leg. Histopathology examination showed epidermal psoriasiform hyperplasia and collections of neutrophils. Numerous koilocytes were also seen. Qualitative Human Papillomavirus (HPV) genotyping test was done on lesion on the leg and the result was positive. The diagnosis of unilateral psoriasis with verruca vulgaris was made based on clinico-histopathological findings. To date, there is no guideline available for unilateral psoriasis. She was treated with topical steroid and 5% LCD in vaseline album for psoriasis and 30% salicylic acid in vaseline album for verruca vulgaris and reported improvement. In this case, HPV infection occurs simultaneously. Theoretically, psoriasis lesions are resistant to infection. On the other hand, various microorganisms, including viruses, are known to be associated with exacerbations of psoriasis and HPV infection is considered an opportunistic infection. Unilateral psoriasis with verruca vulgaris is a very rare case. Recognition of this unusual clinical picture of psoriasis variant with overlapping verruca vulgaris is necessary to avoid delayed diagnosis and perform prompt treatment.

## 1 INTRODUCTION

Psoriasis is a chronic, immune-mediated disorder with a various predisposition combined with environmental triggers, for example trauma, infections, medications, and psychological stress. (Yan de Kerkhof et al., 2018) The lesion is characterized by sharply demarcated erythematous plaque with coarse-micaceous scale. The plaque may be localized or widespread in distribution with predilection in scalp, elbows, knees, hands, feet, trunk, and nails. Yan de Kerkhof et al., 2018; Gudjonsson et al., 2012)

The occurrence of psoriasis in a linear or unilateral or segmental along the lines of Blaschko is very rare. (Nasimi et al., 2016; Ghoneim et al. 2017). Considerable diagnostic confusion exists, since these lesions can clinically resemble very closely to other linear dermatoses such as inflammatory linear

verrucous epidermal nevus (ILVEN). The pathogenesis of unilateral psoriasis remains unclear, however genetic mosaicism is proposed to be the underlying mechanism. (Ghoneim et al. 2017).

To date, there is no treatment guideline specifically for unilateral psoriasis, so treatment was based on the algorithm for psoriasis vulgaris. However, the prognosis is not very good due to various inconsistent treatment results and recalcitrant cases. (Ghoneim et al. 2017).

Psoriasis can be provoked or exacerbated by a variety of different environmental factors, including viral infections, such as papillomaviruses and retroviruses. (Fry L et al., 2007). Nevertheless, the incidence of overlapping psoriasis and verruca vulgaris cases are extremely rare. During 2016-2018, there was only one case of unilateral psoriasis and verruca vulgaris in Department of Dermatology and Venereology, Faculty of Medicine Universitas

Indonesia/Dr. Cipto Mangun kusumo National Central General Hospital. (Data Kunjungan Pasien Poliklinik Kulit dan Kelamin RSUPN Cipto Mangun Kusumo Divisi Alergi - Imunologi, 2016-2018). We report a rare case of unilateral psoriasis with verruca vulgaris. The aim of this case report is recognition of this uncommon psoriasis variant with overlapping HPV infection to avoid delayed diagnosis and perform prompt treatment.

## 2 CASE

A 51-year-old woman with no past medical history presented with itchy, red, scaly patches on the unilateral right breast, arm, and leg. She came to our clinic on July 19<sup>th</sup> 2018 with chief complaints of red, scaly patches on her right side of the body, started on her right lower leg, accompanied by itch, which she felt very bothersome, since 5 years ago.

She had not seek medical treatment for this condition and self-treated with application of cajuput oil, engine lubricant oil, and several over-the-counter ointments for itch. She also soaked her leg with hot water and scratch the lesions to alleviate the itch. Sometimes she used tools, such as comb, back of the knife, or stones to scratch. These provide transient symptomatic relief but the skin lesions persist.

One year ago, the lesion spread to the right arm and right lower back. Still, she had not seek medical treatment and continue the application of previous oils. Two weeks prior to admission, the lesions spread to right breast. Patient also complained of a vegetating mass in her lower right leg. The vegetating mass was located on the previous patches. She forgot the time of the onset, but she noticed enlargement of the mass. There were no itch or pain reported.

Patient denied any joint pain. No history of atopic and allergy were recorded on patient, as well as on her family. There were no history of similar complaints in family. History of contact with plants or farming-related were denied. History of contact with irritants, other than mentioned above, were denied.

Physical examination revealed multiple, erythematous plaque, lenticular-plaques in size, circumscribed, discrete-confluent, with coarse-white scale overlying it on the right breast, lower right back, right arm, right leg-foot. The lesions are unilaterally distributed. There were onychodystrophy and onychodiscoloration on 1<sup>st</sup> to 5<sup>th</sup> digits of right foot. On her lateral aspect of lower

right leg, we found multiple verrucous nodules on the top of the erythematous scaly plaques. The Body Surface Area (BSA) was 8% and the Psoriasis Area Severity Index (PASI) score was 6.6. The itch was evaluated with Visual Analog Scale (VAS) and showed mild itch with score 3-4.

Biopsies from two locations were performed. The first was from erythematous plaque on patient's right breast. Histopathological examination revealed regular acanthosis, column of parakeratosis, orthokeratosis, and collections of neutrophils beneath the stratum corneum (Munro microabscesses). In the dermis, infiltration of lymphocytes was seen. These findings were according to psoriasis. The second location is from her right lower leg. The lesion was verrucous nodule with granulation tissue. In the epidermis, seen parakeratosis, crust, acanthosis with elongated rete ridges, some rete ridges were seen arborizing. Spongiform pustules and numerous koilocytes were seen. In the dermis, seen some chronic inflammatory cells. Qualitative HPV genotyping test was done on lesion on the leg and the result was positive, indicating the presence of HPV infection concomitantly with psoriasis.

The diagnosis of unilateral psoriasis with verruca vulgaris was made based on clinic-histopathological findings. She was treated with 0.25% desoximethasone ointment and 5% LCD in vaseline album for psoriasis and 30% salicylic acid in vaseline album for verruca vulgaris. She has not come for follow up yet but reported mild improvement in her skin lesions.

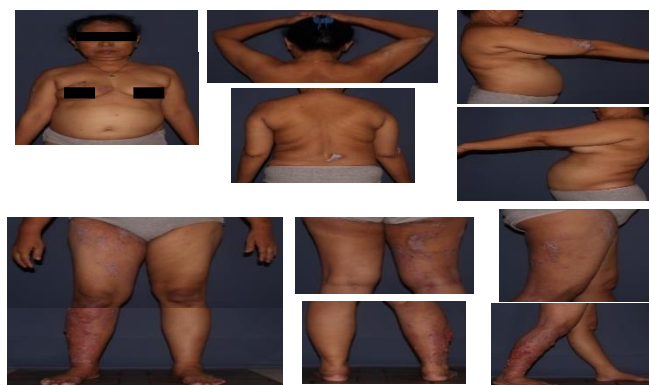

Figure 1. Clinical manifestation in patient




Figure 2. Histopathology findings from erythematous plaque on right breast. (Pointed by yellow arrow) A. regular acanthosis B. column of parakeratosis C. collections of neutrophils (Munro microabscesses)

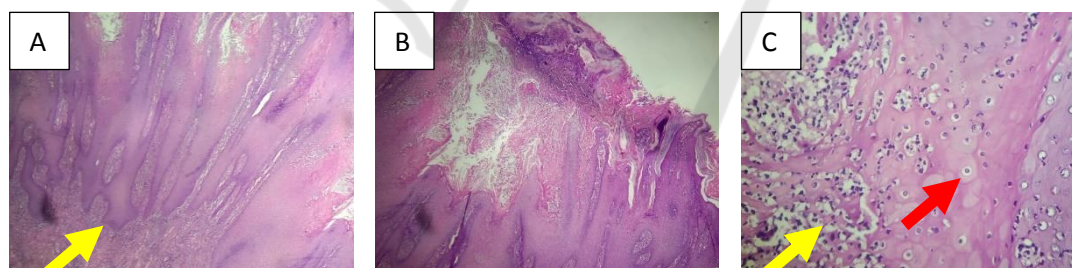


Figure 3. Histopathology findings from verrucous nodules on right lower leg. (Pointed by yellow arrow) A. acanthosis with arborizing elongated rete ridges B. acanthosis with arborizing elongated rete ridges C. collections of neutrophils (Pointed by yellow arrow) and leukocytoclasia (pointed by red arrow)

### 3 DISCUSSION

Unilateral psoriasis is a rare form of psoriasis which characterized by typical psoriasis lesion but only unilaterally distributed. Case reports of this variant of psoriasis are still scarce and the pathogenesis remains unclear although genetic mosaicism was suggested to be the cause. (Ghoneim

et al. 2017). Occurrence of psoriasis in a linear or unilateral distribution raised diagnostic confusion, since these lesions can clinically resemble other linear dermatoses.

The main differential diagnosis is ILVEN which shows similar distribution. (Altmant et al., 1971) described the diagnostic criteria of ILVEN: early onset, predominance in women, prevalence in the lower extremity, pruritus, and recalcitrance to

treatment. Histopathology examination in addition to the clinical characteristics to some degree could help to distinguish between these two entities. In some cases, if they share the same histology findings, a definite diagnosis can be made only with meticulous history taking, detailed clinical examination and follow-up to observe treatment result (Gudjonsson et al., 2012; Saraswat A. et al., 2004). Late onset of erythematous and scaly plaques with quite rapid progression and involvement of nails, and a response to antipsoriatic treatment indicate psoriasis in this case.

Patient was initially suspected with chromoblastomycosis because of the lesions on her lower right leg (verruccous nodules on erythematous was positive, indicating HPV infection concomitant with psoriasis lesions. Theoretically, psoriasis lesions are resistant to infection due to high production of antimicrobial peptides and interferon gamma. On the other hand, various microorganisms, including viruses, are known to be associated with exacerbations of psoriasis. HPV infection of keratinocytes is favored by epidermal proliferation, it could be argued that infection is secondary to the hyperproliferative process in psoriasis and represents a type of opportunistic infection. (Fry L et al., 2007). In addition, patient's habit to manipulate lesions by scratching due to the itch may cause trauma that became port d'entrée of HPV infection.

To date, there are no specific guideline for unilateral psoriasis. Treatment options were based on the algorithm for psoriasis vulgaris and some of the cases showed unresponsiveness. The patient was treated in accordance with treatment algorithm from Indonesian Psoriasis Study Group. Patient was classified as moderate psoriasis and received topical treatment with 0.25% desoximethasone ointment and 5% LCD in vaseline album. We didn't perform phototherapy because it may further worsen the verruca vulgaris. Segmental manifestations of psoriasis respond less favorably to systemic therapies. The chronicity and resistance to antipsoriatic agents were suggested to be in part due to the loss of heterozygosity in cells where the lesions occur.<sup>4</sup>As for the verruca vulgaris, 30% salicylic acid in vaseline album was prescribed. She has not come for follow up yet but reported mild improvement in her skin lesions, particularly lesions on her right leg.

#### 4 CONCLUSION

Unilateral psoriasis with verruca vulgaris is a very rare case. We report a 51-year old woman with a 5-

plaques) mimicked subcutaneous mycoses infection. There were no history of contact with plants or penetrating injury, such as a thorn prick, and the histopathology findings showed no muriform bodies. Therefore, chromoblastomycosis could be excluded from our differential diagnosis.

Histopathology examination was performed to confirm the diagnosis. Two specimens were taken, the first was from patient's right breast and the findings were according to psoriasis. The second specimen was taken from patient's right leg and interestingly, numerous koilocytes were seen. This finding was according to psoriasis with verruca vulgaris. To establish the diagnosis even further, qualitative HPV genotyping was done and the result year history of itchy, red, scaly patches on the unilateral right breast, arm, and leg. Over the following year there were also some vegetating masses on top of the red patches on her lower right leg. The diagnosis of unilateral psoriasis with verruca vulgaris was made based on clinico-histopathological findings. The patient was treated in accordance with treatment algorithm for psoriasis vulgaris from Indonesian Psoriasis Study Group. She was treated with topical steroid and 5% LCD in vaseline album for psoriasis and 30% salicylic acid in vaseline album for verruca vulgaris and reported improvement.

#### REFERENCES

- Altman J, Mehregan. 1971A. Inflammatory linear verrucose epidermal nevus. *Arch Dermatol.*;104:385-9.
- Data Kunjungan Pasien Poliklinik Kulit dan Kelamin RSUPN Ciptomangunkusumo Divisi Alergi-Imunologi Tahun. 2016-2018.
- Fry L, Baker BS. 2007. Triggering psoriasis: the role of infections and medications. *Clin Dermatol*; 25:606-15.
- Ghoneim S, Ramos-Rodriguez AJ, de Lara FV, Bonomo L. 2017. The successful treatment of a case of linear psoriasis with ixekizumab. *Case Rep Dermatol Med*; 3280215.
- Gudjonsson JE, Elder JT. Psoriasis. In: Goldsmith LA, Katz SI, Gilchrist BA, Paller AS, Leffell DJ, Wolff K, Eds. *Fitzpatrick's. 2012. Dermatology in General Medicine.* 8<sup>th</sup> Ed. New York: McGrawHill; p.197-231.
- Nasimi M, Abedini R, Azizpour A, Nikoo A. 2016. Isolated linear blaschkoid psoriasis. *Clin Exp Dermatol*; 41:775-8.
- Saraswat A, Sandhu K, Shukla R, Handa S. 2004. Unilateral linear psoriasis with palmoplantar, nail, and scalp involvement. *Pediatr Dermatol*; 21:70-3.
- van de Kerkhof PCM, Nestle FO. 2018. Psoriasis. In: Bologna JL, Schaffer JV, Cerroni L. Eds. *Dermatology.* 4<sup>th</sup> Ed. Philadelphia: Elsevier. p.138-59.