

Diagnostic Utility of Epithelial Membrane Antigen (EMA) and Calretinin (Cal) in Malignant Pleural Mesothelioma: A Case Report

Noni Novisari Soeroso^{1*}, Ade Indriya¹, Andika Pradana¹, Rahmat Hidayat¹

¹Department of Pulmonology and Respiratory Medicine, Faculty of Medicine, Universitas Sumatera Utara, Jl. Dr. Mansyur No. 5 Medan 20155, Sumatera Utara, Indonesia

Keywords: Calretinin, epithelial membrane antigen (EMA), malignant pleural mesothelioma, pleuroscopy

Abstract: Malignant pleural mesothelioma (MPM) is a rare disease, but the incidence of this disease has increased over time. The diagnosis of MPM can be established based on radiological and pleuroscopic findings. The immunohistochemistry of EMA and Calretinin may confirm the diagnosis of MPM. We reported a case of 70-years-old man, worked as a construction worker for 20 years came with severe left chest pain and shortness of breath for 1 month. Chest X-ray shows left moderate pleural effusion, and thoracic CT-scan result revealed mass in left pleura. Pleuroscopy had been performed and mass in the parietal pleura was found with the histopathology reports suggestive for mesothelioma. Immunohistochemistry staining with EMA and Calretinin were both positive, confirming the diagnosis of malignant pleural mesothelioma. He was then scheduled for chemotherapy. However, his condition worsened over time and finally passed away.

1 INTRODUCTION

Mesothelioma is cancer that originates from mesothelial cells lining the pleural cavity, peritoneum, pericardium and tunica vaginalis. Pleural mesothelioma is most commonly found in all cases of mesothelioma (80% of cases) and asbestos is believed to be one of the causes of pleural mesotheliomas.

Australia is one of the countries with the highest level of mesothelioma cases in the world. The predicted mortality rate in the UK is estimated at around 90.000 by 2050. In Japan, around 100.000 deaths over the next 40 years has been predicted. Men have a risk three times greater than women in cases of mesothelioma. However, no definite data of mesotheliome prevalence in Indonesia (American Cancer Society, 2018).

Malignant pleural mesothelioma is mostly caused by exposure to asbestos in the workplace. This is more common in older people, but sometimes may occur in younger people (Husain *et al.*, 2018).

When mesothelioma is diagnosed at an early stage before invading lymph nodes and other parts of the body, treatment is more effective and prognosis is more promising. However, the diagnosis of mesothelioma appears very challenging. In fact, it is

often misdiagnosed as less serious conditions like fibrous pleuritis. Thus, more diagnostic modalities will provide help to establish the diagnosis of mesothelioma accurately. We reported a patient diagnosed with malignant pleural mesothelioma based on positive immunohistochemistry findings of epithelial membrane antigen and calretinin.

2 CASE REPORT

A 70-year-old man, heavy smoker, came with shortness of breath for 1 month before being hospitalized, getting worse when coughing or deep-breathing. Non-productive cough has been experienced for 3 months. He also felt severe left chest pain in the last 1 month with VAS 5-6. He used to work as construction worker. He also experienced decreased appetite and loss of body weight about 5 kg in 1 month. He has never taken anti-tuberculosis drugs. While admission, his vital signs were within normal limits except for increased respiratory rate and SpO₂ 92% in room air. Complete blood count showed anemia (9.3 mg/dl). Arterial blood gas shows mild hypoxemia and respiratory alkalosis (pH: 7.48; pCO₂: 38.9 mmHg; pO₂: 70 mmHg; HCO₃: 26.9 mmol / L; BE: 2.7 mmol / L; SaO₂: 93%). Chest X-ray showed

moderate left pleural effusion. Thoracentesis was performed and about 1000ml fluid was drained, with pleural fluid cytology result was chronic inflammatory smear. Thoracic CT scan revealed a suspicion for left pleural tumors in the apex and medial to lower field along with massive left pleural effusion and left inferior lobe atelectasis (Figure 1A).

Pleuroscopy was then performed and multiple masses in the parietal pleura and visceral pleura were found, continued with biopsy (Figure 1B).

Histopathologic finding supported the diagnosis of mesothelioma (Figure 2A). Immunohistochemistry examination with Pancytokeratin, EMA (Figure 2B) and calretinin (Figure 2C) were conducted with positive result, confirming the diagnosis of stage IIIB malignant pleural mesothelioma. He was then scheduled for chemotherapy using Cisplatin 60mg BSA and Etoposid 100 mg BSA. However, his condition worsened over time and he eventually passed away.

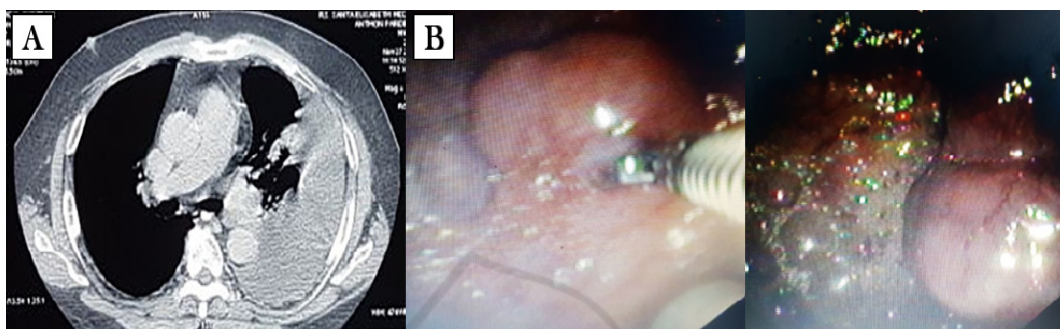


Figure 1: (A) Thoracic CT scan revealed a suspicion for left pleural tumors in the apex and medial to lower field along with massive left pleural effusion and left inferior lobe atelectasis. (B) Multiple masses in the parietal pleura and visceral pleura were found.

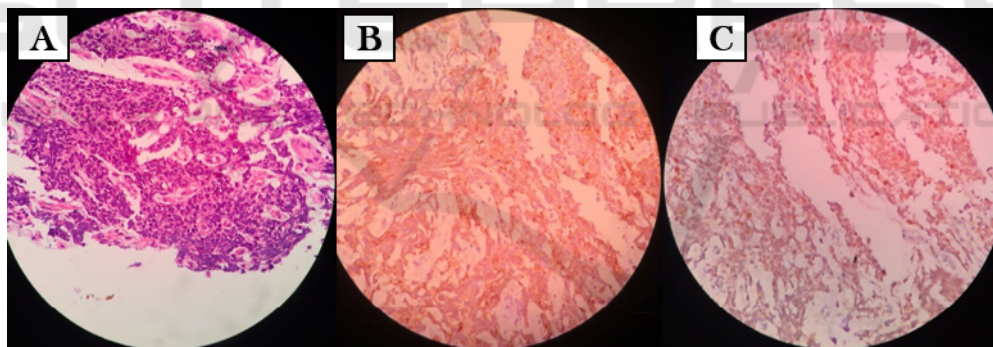


Figure 2: (A) Histopathologic finding supported the diagnosis of mesothelioma, Immunohistochemistry examination with Pancytokeratin, EMA. (B) and calretinin. (C) were conducted with positive result, confirming the diagnosis of malignant pleural mesothelioma.

3 DISCUSSION

Asbestos exposure is highly related to the incidence of malignant pleural mesothelioma (MPM). It may affect mesothelial, a thin membrane lining the organs in the body including the thoracic cavity (pleura), heart (pericardium) and abdominal cavity (peritoneum). (American Cancer Society, 2018).

MPM is mostly caused by exposure to asbestos in the workplace. Pleural mesothelioma is more

common in people over 70 years old, but sometimes it may affect younger people. Our patient reported in this case was 70 years old and had a prolonged exposure to asbestos in the workplace as a construction worker, thus raised a high suspicion for mesothelioma.

Asbestos can cause mesothelioma through four mechanisms. The first mechanism is pleural irritation. Thin and long fibers (width <math><0.25 \mu\text{m}</math> and length >math>0.8 \mu\text{m}</math>) penetrating the alveolar epithelium towards the pleural cavity will cause repeated

irritation of the mesothelial surface and local inflammation. The second mechanism is related to the disorder of the mitotic process. The third mechanism is the formation of oxygen radicals which are associated with high iron content in asbestos fibers. And the last mechanism is stimulation of macrophages by asbestos fibres to secrete various cytokines and growth factors that will induce inflammation and promotion of malignancy, including tumor necrosis factor- α (TNF α), interleukin-1 β (IL-1 β), transforming growth factor- β (TGF β) and platelets derived from growth factors (PDGF) (Mossman *et al.*, 2013).

Patients with MPM often feel shortness of breath and severe chest pain, just like what our patient reported. The pain is most oftenly localized accompanied with pleural effusion. Additional symptoms such as cough, malaise, and decreased appetite along with weight loss and fever without any sign of infection (American Cancer Society, 2018).

Diagnostic approaches include chest X-ray and thoracic CT scan to determine the location of tumor and metastasis. Cytology of pleural fluid, peritoneal or pericardial fluid along with tissue biopsy may help to confirm the diagnosis (American Cancer Society, 2018; Cancer Council, 2015).

Tumor markers for MPM can be detected by immunohistochemistry examination with Epithelial Membrane Antigen (EMA) and Calretinin. Both give high positive results for mesothelioma. Several studies stated that the sensitivity and specificity of EMA for MPM are 91.8% and 100% respectively (Nautiyal *et al.*, 2017). Calretinin is currently used as a marker for mesothelial cells both benign and malignant and more than 95% are positive for epitheloid-type mesothelioma. Calretinin is used primarily to differentiate mesothelioma from carcinoma or other malignant metastases, especially those with a similar histopathologic findings with mesothelioma from tissue biopsy or cytology. However, other studies have shown that calretinine is not only positive for mesothelial cells, but may also be positive in other malignancies such as metastatic adenocarcinoma or squamous cell carcinoma (Husain *et al.*, 2018). Barberis *et al.* stated that anticalretinin staining of pleural fluid yielded 100% positive in malignant mesothelioma and 23% positive in a metastasis adenocarcinoma (Nautiyal *et al.*, 2017; Husain *et al.*, 2018).

As a conclusion, we reported a case of malignant pleural mesothelioma diagnosed with the positive immunohistochemistry findings of EMA and Calretinin. The use of both modalities may yield a

better sensitivity and specificity level to confirm the diagnosis accurately.

FUNDING

No grant support or funding from public institutions or private enterprises was received for this case report.

ACKNOWLEDGEMENTS

The researcher would like to thank Universitas Sumatera Utara Hospital which have allowed the retrieval of medical history data.

REFERENCES

- American Cancer Society. 2018. Malignant Mesothelioma. [online]. [cited 2016 Mei 14]. Available from: www.cancer.org/cancer/malignantmesothelioma/detail/edguide/malignant-mesothelioma
- Cancer Council. 2015. Understanding Pleural Mesothelioma. A guide for people with cancer, their families and friends. [online]. [2016 Mei 14]. Available from: https://www.cancer.org.au/content/about_cancer/ebooks/CAN4798%20Understanding%20Pleural%20Mesothelioma%20web.pdf
- Husain, A. N. *et al.*, 2018. Guidelines for pathologic diagnosis of Malignant Mesothelioma: 2017 Update of the consensus statement from the International Mesothelioma Interest Group. *Archives of Pathology and Laboratory Medicine*. 142(1): 89-108. doi: 10.5858/arpa.2017-0124-RA.
- Mossman, B. T. *et al.*, 2013. New insights into understanding the mechanisms, pathogenesis, and management of malignant mesotheliomas. *American Journal of Pathology*. 182(4): 1065-77 doi: 10.1016/j.ajpath.2012.12.028.
- Nautiyal, N. *et al.*, 2017. Diagnostic utility of Epithelial Membrane Antigen (EMA) and Calretinin (CAL) in effusion cytology. *Journal of Clinical and Diagnostic Research*. 11(5): EC36-EC39. doi: 10.7860/JCDR/2017/24339.9888.