

Sumbawa Horse Milk as a Prevention of Inflammatory Bowel Disease (IBD) in Animal Model based on IL-6 Expression and Gastric Histopathology

Nurina Titisari^{1*}, Theresa Lidya Pramesti², Tiara Widyaputri³, Rahadi Swastomo⁴

¹Physiology Departement of Veterinary Medicine, University of Brawijaya, PuncakDiengEksklusif, Malang, Indonesia

²Student of Veterinary Medicine, University of Brawijaya, PuncakDiengEksklusif, Malang, Indonesia

³Clinic Departement of Veterinary Medicine, University of Brawijaya, PuncakDiengEksklusif, Malang, Indonesia

⁴Parasitology Departement of Veterinary Medicine, University of Brawijaya, PuncakDiengEksklusif, Malang, Indonesia

Keywords: Flowcytometri, Gastrointestinal, Inflammation, *Rattusnorvegicus*.

Abstract: Sumbawa horse milk contains bioactive components as exogenous antioxidants, anti-inflammatory and antimicrobial which can prevent Inflammatory Bowel Disease. IBD is characterized by ongoing inflammation of the digestive tract that could changed gastric histology and trigger pro-inflammatory cytokines. The purpose of this study was to observe the preventive effects of Sumbawa horse milk on gastric organs inflammation in IBD animal models. Twenty male rats, 8 weeks, 150-200 grams BW, divided into five treatment groups; K- group (negative control), indometacin induced group; i.e K+ (positive group without horse milk), P1(horse milk dose 0.5 mL/rat), P2 (horse milk dose 1.0 mL/rat), and P3(horse milk dose 1.5mL/rat). Flowcytometry method was conducted to observe IL-6 expression, and then analyzed with one way ANOVA followed by a tukey test (α 95%). While the gastric histopathological was analyzed descriptively. The results showed that IL-6 expression were significantly lower ($p < 0.05$) in P2 dan P3 compared with K+group. Whereas in the histological result, the p3 group was able to prevent histopathological damage of the gastric organs compared to other treatment groups. The conclusion of the study is Sumbawa horse milk able to prevent increased of IL-6 and gastric mucosal cell erosion, with the best dose is 1.5 mL/rat.

1 INTRODUCTION

Inflammatory Bowel Disease (IBD) is a disease characterized by inflammation of the digestive tract associated with histopathological changes in the digestive tract mucosa such as the stomach, intestine and colon in the form of infiltration of inflammatory cells in the lamina propria mucosa (Washabau, 2008). Common symptoms of IBD are diarrhea and bleeding in the digestive tract which is at high risk of causing damage to the digestive tract (McFarland, 2008). IBD is divided into two types, i.e ulcerative colitis (chronic inflammation of the large intestine) and chron's disease (chronic inflammation of the small intestine) (Xavier and Podolsky, 2007). According to Volkman's research (2017), there were 136 cases of IBD (Inflammatory Bowel Disease) reported at the Clinic Clinic for Small Animals, Faculty of

Veterinary Medicine, Freie Berlin, Germany throughout 2017.

The causative factor of IBD is not known for certain, but it is allegedly influenced by immune regulation failure, exogenous factors, and the role of intestinal flora (Thorenson et al. 2007). IBD also occurs due to the use of non-steroidal anti-inflammatory drugs (NSAIDs) such as indomethacin (Podolsky, 2002). Indomethacin is an indole-acetic acid derivate that is used as a treatment for arthritis. In addition to its curative effects, indomethacin has side effects which can inhibit COX-1 cyclooxygenase which functions against prostaglandin synthesis and mucous production to protect the small intestinal mucosa from bacterial and viral infections (Takeuchi, 2003). Another side effect of indomethacin, it can increase free radicals, which it can damage the digestive organs marked by microflora reduction (Strus et al., 2009).

In this study we examined the ability of Sumbawa horse milk to prevent IBD in animal model. According to Saputro (2016), Sumbawa horse milk has protein components namely lysozyme (BM 17 kDa) and lactoferrin (BM 75 kDa) which act as indigenous proteins that function for antimicrobial compounds and have bioactive compounds as antioxidants which play an important role to protect the body from conditions of oxidative stress due to inflammatory processes. Elias (2008) states that the bioactive compounds in Sumbawa horse milk have the primary structure of the amino acid histidine which has an imidazole group as a hydrogen giver, a lipid-peroxyl radical scavenger, and a hydriphobic potential as an exogenous antioxidant.

2 MATERIAL AND METHOD

2.1 Tools and Materials

Equipment include rats cages, masks, gloves, micropipets, dissecting sets, glass objects, glass cover, autoclaves, scales, sonde, filters, magnetic stirrer, measuring cup, digital scale, incubator, aluminum foil, blue tip, yellow tip, microtube, sample pot, cover slip, fixation board, centrifugator, waterbath.

Materials used in this study include 20 rats (*Rattusnovergicus*), Wistar strain, male, 120-150 gram of body weight, Sumbawa horse milk, corn oil, 10% formalin, HE staining (Hematoxyline Eosin), aquades, xylol, PBS, liquid paraffin, IL-6 antibodies, chromagen DAB (DiaminoBenzidine) dyes, Biotinylated Rabbit Anti-Rat IgG Antibody secondary antibodies.

2.2 Horse Milk Induction

Sumbawa horse milk was from horse farms located in Dompu Regency, Sumbawa Island, NTB (West Nusa Tenggara). Sumbawa horse milk was a fresh pure milk with milking date on 31 December 2018. Sumbawa horse milk is given as preventive once a day with a volume of 0.5 mL/rat, 1 mL/rat, and 1.5 mL/rat for 7 days and then induced indomethacin using gastric sonde on day 8 then continued giving Sumbawa horse milk on day 9-14 (Reni et al., 2010).

2.3 Indometacin Induction

The IBD animal model in this study used a single dose of NSAID induction in the form of indomethacin. The induction dose of IBD with

indomethacin was 15mg / kgBB (Aulanni'am et al., 2011). The administration of indomethacin in this study was carried out orally using a gastric sonde. Previously the indomethacin must be diluted with corn oil. The dilution of indomethacin as much as 45 mg requires 4 mL of corn oil as the solvent (Bures, 2011).

2.4 Histopathological Preparation

Gastric organs that have been fixed with 10% formalin then carried out the process of alcohol dehydration using alcohol concentration levels of 70%, 80%, 90%, absolute alcohol I, absolute alcohol II, then purified using xylol I and xylol II. The paraffin process was carried out using paraffin I and paraffin II. The preparation is put into a mold that contains half volume paraffin and the sample is placed vertically and horizontally so that the cross section is attached to the base of the paraffin. After starting to rigid, paraffin is added again until the mold was full and left until the paraffin hardens. The paraffin blocks are then cut thin 5 micrometers thick using a microtome. The results of the ribbon-shaped pieces are spread on warm water with a temperature of 46 ° C and immediately removed which is useful for stretching the pieces so they do not multiply or eliminate the folds caused by cutting. The preparation is then removed and placed on a glass object and dried overnight in an incubator at 60 ° C so that staining of Hematoxylin-Eosin (HE) (Febam, et al., 2010).

2.5 Interleukin 6 (IL 6) Expression

IL-6 expression measurements using the Flowcytometry method. The initial stage was taken the rat's gastric, washed and soaked in PBS then the organs were crushed with the base of a new syringe in 5 mL Phosphat Buffer Saline (PBS) Solution. Filtered with wire and put into propylene 15 mL to a certain volume. Homogenized by centrifuging with a 2500 rpm for 5 minutes at a temperature of 10°C and then discarded the supernatant. The pellet that remain then resuspended with PBS 1 mL. Suspense results are divided into several 1.5 mL microtubes according to the needs of the type of coloring combination that has been filled with PBS ± 0.5 mL, @ 50 µL. The suspension is centrifuged at 2500 rpm for 5 minutes at 10°C then the supernatant is discharged from the centrifugation until there is a pellet which is then carried out intracellular staining to determine the expression of IL-6 by adding a fixative solution of 50 µL, then incubated for 20 minutes at 4 ° C in a dark room. The 500 µL permeability solution (1X) was

then homogenized with a centrifuge speed of 2500 rpm for 5 minutes at 10°C then the supernatant was removed. The pellet which was then added 50 µL specific antibody solution, after that incubated it for 20 minutes at a 4°C in a dark room. After incubation is complete, ± 400 µL PBS was added and transferred to the flow cytometry cuvette for analysis.

2.6 Data Analysis

Flow cytometry test results were analyzed quantitatively using BD Cellquest Pro™ Software, Microsoft Excel applications and statistical package software for the social science (SPSS) for Windows 16 with One Way analysis of variance (ANOVA) Test. The Tukey test was performed if there were significant differences (α 95%). As for histopathological features, descriptive analysis was performed.

3 RESULT AND DISCUSSION

The test results showed that IL-6 expression of gastric organ in negative control group (K-) was significantly different with the positive control group (K+), group P1 and group P2 but not with group P3 (Table 1). This is due to the normal state of proinflammatory cytokines was produced by the body to maintain homeostatic conditions in the immune system. According to Erica et al. (2000), IL-6 is a proinflammatory cytokine that is produced by macrophages and is present in almost all tissues in the body even in small amounts.

The positive control group (K+) showed significantly different results from the negative control group (K-), P2 group, and P3 group, but not significantly different from P1 group. The results in this study are in accordance with research conducted by Riyansyah et al (2015), administration of indomethacin at a dose of 15 mg/kgBW orally in rats can cause irritation and damaged gastric mucosa, which can trigger IL-6 expression as a pro cytokine inflammation. Indomethacin inhibits COX-1 formation which destroys the performance of mitochondria in the cell so it will interrupted the oxidative postforilation cycle. The disruption of electron transfer on oxygen molecules can trigger inflammation (Takeuchi et al., 2003). This can triggers the formation of excess Reactive Oxygen Species (ROS) that will stimulate the activation of NF-kB which is a transcription factor in regulating the expression of pro-inflammatory cytokine cells such as IL-6 (Aulanni'am et al., 2012).

Table 1: Table of the average expression of interleukin 6 (IL-6) gastric organs of white rats.

Treatment	Average IL-6 expression (% gated) ± SD
K-	19,4925±4,33 ^a
K+	36,0475±1,535 ^c
P1	31,57±1,489 ^{bc}
P2	28,3525±2,464 ^b

Note: notations a, b, c show significant differences between groups.

3.1 Histopathology of the Rat Gastric Organ (*Rattus Novergicus*)

Gastric histology with hematoxylin eosin (HE) staining (Figure 1). Based on on observation on the gastric preparations of the negativ control group (healthy mice) (Figure 1.A) showed that the mucosal layer of tunica mucosa epithelial simplex with gastric pit formation and gastric gland still arranged and neatly lined with cylindrical simplex form. Puspitasari (2008) state mucosal layers contain many mitochondria and granules to produce pepsinogen enzymes, while parietal cells are acidophilic because these cells produce HCL of stomach acid. It also appears a small number of neutrophill cells, which is normal because to its role agains pathogenic agents.

Contrast result occur in the positive control group (Figure 1.B), which showed a severe cell damage in the tunica lamina propria layer of the gastric mucosa. The epithelium erosion accompanied by infiltration of inflammatory cells (neutrophils) when we compared it with negative controls. Erosion that occurs in the gastric mucosa suspected as a result of free radicals from indomethacin induction, that can stimulate leucocyte toward gastric mucosa cells. Leucocyte wull produce H₂O₂ to kill several types of bacteria and fungi and for cell growth, but neither attack specific targets. So it will also attack polyunsaturated fatty acis from cell membranes, cell organeles, or DNA, which can cause damage to structure and function cell (Puspitasari, 2008).

The histopathological result showed no significant difference between group P1 (Figure 1.C) and K⁺ (Figure 1.B). There were erosion in gastric mucosal epithelial cells and inflammatory cell infiltration still visible although its not as much as K⁺ group. In group P2 (Figure 1.D) showed less erosion of the epithelial cell and lower number of inflammation cells when we compared with P1 group

(Figure 1.C). In the last horse milk treatment, P3 (Figure 1.E) showed a better result compared to the other treatment group. Epithelial cells erosion in lamina propria tunica gastric mucosa was decreasing and inflammation cells number was much lower when we compared with P1 and P2 group.

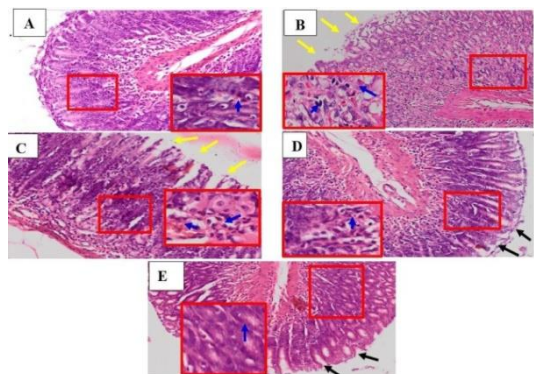


Figure 1: Histopathology of rat gastric mucosa (*Rattus norvegicus*) (gastric preparations; cross sections; HE staining. 100x enlargement).

Note: (a) Negative control rats (K-); (B) Positive control rats (K+); (C) Group P1; (D) Group P2; (E) Group P3;

□ (400x magnification)

↑ (epithelial erosion of the gastric mucosa)

↑ (neutrophil cell infiltration)

↑ (repair of epithelial cells)

4 CONCLUSIONS

Preventive administration of Sumbawa horse milk in animal model of IBD induced by indomethacin were able to prevent IL-6 expression and histopathological changes in gastric organs with the best dose was 1.5 mL/rat. Further research needs to be done to prevent Inflammatory Bowel Disease (IBD) using Sumbawa horse milk on the entire digestive tract.

ACKNOWLEDGEMENTS

This research was funded by Veterinary Medicine Faculty, University of Brawijaya through the DPPSPP scheme 2019.

REFERENCES

- Aulannia'am, Roosdiana A. & Rahmah, N.L. (2012). The Potency of Sargassum duplicatum Bory Extract on Inflammatory Bowel Disease (IBD) in Rattus Norvegicus. *Journal of Life Sciences* 6: 144-154.
- Aulanni'am, Roosdiana, A., Rahmah, N.L., Tjaniadi P., Lesmana, M. & Subekti, D. (2003). Antimicrobial Resistance of Bacterial Pathogens Associated with Diarrheal Patients in Indonesia. *Am J Trop Med Hyg.* 68(6): 666-10. Bures, J, J. Pejchal, J. Kvetina, A. Tichy, S. Rejchrt, M.
- Kunes & Kopacova, M. (2011). Morphometric analysis of the porcine gastrointestinal tract in a 10-day high-dose indomethacin administration with or without probiotic bacteria *Escherichia coli* Nissle 1917. *Human and Experimental Toxicology.* 30(12) 1955-1962.
- Elias, R, J. & Decker E.A. (2008). Antioxidant Activity of Proteins and Peptides. *Food Sci Nutr.* 48:430-441.
- Erica, E. S., Henn, A., Gurtoo, H.L., Wollman, R.M., Alderfer, J.L., Mihich, E., Ehrke M. J. (2001). A Novel Tumor Necrosis Factor- α Inhibitory Protein, TIP-B1. *International Journal of Immunopharmacology* 22(12):1137-42
- Febrom, B., Wientarsih, I & Pontjo, B. (2010). Activity Of Ambon Banana (*Musa Paradisiaca* Var. *Sapientum*) Stem Extract In Ointment Formulation On The Wound. Healing Process Of Mice Skin (*Mus Musculus Albimus*). *Majalah Obat Tradisional* 15(3):121-137.
- McFarland, L.V. (2008). State-of-the Art of Irritable Bowel Syndrome and Inflammatory Bowel Disease Research in 2008. *World Journal of Gastroenterology.* 14 (17): 2625-2629.
- Puspitasari, D. A. (2008). *Gambaran Histopatologi Lambung Tikus Putih (Rattus norvegicus) Akibat Pemberian Asam Asetil Salisilat.* Institut Pertanian Bogor.
- Podolsky, D. K. (2002). Inflammatory Bowel Disease. *N Engl J Med.* 347 (6): 417- 429.
- Reni, S., Sumarno. & Widjanto, E. (2011). Susu Kuda Sumbawa Meningkatkan Respon Imun Seluler Makrofag Peritoneal Mencit terhadap Salmonella Typhimurium Jurusan Gizi Politeknik Kesehatan Mataram. *Jurnal Kedokteran Brawijaya*, Vol. XXVI, No. 1.
- Riyansyah, Y., Lanny, M. & Ratu C. (2015). Uji aktifitas Antiinflamasi Ekstrak Ethanol Daun Ubi Jalar Ungu Terhadap Tikus Wistar Jantan. *Prosiding Penelitian SPESIA Unisba.* Hal:630-636.
- Saputro, M. (2016). *Profil Protein, Aktivitas Antioksidan dan Inhibitor ACE dari Susu Kuda dan Hidrolisisnya.* IPB: Bogor.
- Strus, M., Gosiewski., Fyderek, K K. & Adamski, P. (2009). A Role of Hydrogen Peroxide Producing Commensal Bacteria Present in Colon Of Adolescents with Inflammatory Bowel Disease in Prepetuation of the Inflammatory Process. *Journal of Physiology and Pharmacology* 60 (6):49-54.
- Takeuchi, K., Tanaka, A., Ohno, R. & Yokota, A. (2003). Role of COX Inhibition in Patogenesis of NSAID-

- Induced Small Intestinal Damage. *Research article*. Kyoto Pharmaceutical University. Kyoto. Healing: A Review. *Wound Repair and Regeneration*. 6(12): 591-599.
- Tonnesen, M. G., Feng X. & Clark R. A. F. Angiogenesis in Wound Healing. *JID Symposium Proceedings*. 2007; 5(1): 40-46.
- Uniacke-Lowe, T. & Fox, P.F. (2010). Equine Milk Proteins: Chemistry, Structure, and Nutritional Signification. *IntDairy J*: 20:609-629
- Volkman M., Steiner, J.M., Fosgate, G.T., Zentek, J., Hartmann, S. & Kohn, B. (2017). Chronic Diarrhea in Dogs- Rostropective Study in 136 Cases. *JVet Intern Med*. Vol 3 (2): 121-126.
- Washabau R.J. (2008). *Summary of Findings and Reports of the WSAVA Gastrointestinal Standardization Group. The 33rd WSAVA Congress*. Dublin. 20-24. 08.2008, pp. 60-62.
- Xavier, R.J. & Podolsky, D.K. (2007). Unravelling The Patogenesis of *Inflammatory Bowel Disease*. *Nature*. 448 (7152): 427-434.

