

Expression of Estrogen Beta (Ers B) Receptor and Ovarian Histopathology Changes in Rats (*Rattus Norvegicus*) Ovarian Hypofunction Model

Aulia Firmawati¹, Mitra Artha Kurnia Hutabarat² and Herlina Pratiwi^{3*}

¹Reproduction Laboratory, Faculty of Veterinary Medicine, Brawijaya University, Indonesia

²Undergraduate Students of the Faculty of Veterinary Medicine, Brawijaya University, Indonesia

³Embryology Laboratory Faculty of Veterinary Medicine, Brawijaya University, Indonesia

Keywords: ERs β , Folliculogenesis, GnRH antagonists, Ovarian hypofunction, Rats

Abstract: One of the reproductive disorders that are often found in breeders in Indonesia is ovarian hypofunction. Ovarian hypofunction is a pathological condition in the ovary that is characterized by a decrease in ovarian function that causes inhibition of folliculogenesis and failure of ovulation. The purpose of this study was to develop ovarian hypofunction animal models through cetrorelix acetate induction and observe their effects on the expression of estrogen beta receptors (Ers β) and histopathological changes in the ovaries. This study used three groups of female Wistar strains (*Rattus norvegicus*), with ages 8-10 weeks, and body weight 150-180 grams. The treatments in this study included a control group (KN) without cetrorelix acetate, the first group (P1) was treatment group with an injection of cetrorelix acetate 0.009 mg/kg BW, and the second group (P2) was treatment group with an injection of cetrorelix acetate exposure 0.0135 mg/kg BW. Expression of beta estrogen receptors (Ers β) in the ovaries was analyzed by immunohistochemical methods, and the data were analyzed using the BNJ test ($p < 0.05$). The ovarian histopathological changes were analyzed by the hematoxylin-eosin (HE) staining method, then analyzed qualitatively. The results of this study indicate that the treatment groups P1 and P2 with GnRH antagonists differ significantly compared to the negative control group. The P2 treatment group had the highest reduction in estrogen receptor expression with Ers β by 92.2%. The result of histopathological in P1 and P2 treatment groups were able to inhibit the development of antral follicles. The conclusion of this study is that cetrorelix acetate as GnRH antagonists can reduce estrogen receptor expression and inhibit folliculogenesis in ovarian histopathology.

1 INTRODUCTION

The highest incidence of reproductive disorders in community farms in Indonesia is ovarian hypofunction. The incidence rate of ovarian hypofunction in East Java in 2010-2017 was 9.28% (Hermadi, 2015), while ovarian hypofunction in Rembang Regency, Central Java, was 6.25% (Sutiyono *et al.*, (2017) and in the Regency Enrekang, South Sulawesi Province at 71% (Yahya, 2017) and in Jambi province it was reported that the incidence of ovarian hypofunction had the second- highest percentage of events at 19.32% (Rosadi *et al.*, 2018).

Ovarian hypofunction is a pathological condition characterized by a decrease in ovarian activity is showing signs of lust and producing ovum. Ovum produced under conditions of ovarian hypofunction

generally has low fertility, making it difficult and even cannot be fertilized despite good quality spermatozoa. Ovarian hypofunction is the most frequent reproductive disorder due to mismanagement of feed and reproductive hormone mechanisms (Pradhan and Nakagoshi, 2008). According to Gitonga, (2010) Cows that experience ovarian hypofunction are often found with the occurrence of silent heat, sub estrus (lust without ovulation), irregular lust cycle and the onset of postpartum lust. Ovarian hypofunction that is not treated immediately can cause ovarian atrophy that is irreversible.

In conditions of ovarian hypofunction Ovarian histopathological features can show ongoing folliculogenesis in the ovary. Ovarian follicles based on their development are divided into several levels including primordial follicles, primary follicles,

growing follicles, and de Graaf follicles. Disrupted folliculogenesis can eliminate follicles in various stages and then develop into follicular atresia. Ovarian hypofunction will show a delay in the development of primary follicles, secondary follicles, and the presence of atresia follicles in quite high numbers. Folliculogenesis that occurs is difficult to reach the ovulation stage so that no tertiary follicles, de Graaf follicles or corpus luteum are found (Hestianah *et al.*, 2014).

The production of the hormone estrogen continues to increase when de Graaf follicles will ovulate. The effect of the hormone estrogen in tissue is closely related to the activation of the estrogen receptor that the tissue has. Obstructed ovulation will certainly affect the production of the hormone estrogen followed by activation of its receptors. The production of the hormone estrogen can decrease because follicles do not develop thereby reducing estrogen receptor activation in some target tissues. Estrogen can diffuse into ovarian, uterine, and mammary glands systemically (Caldon, 2014).

Ovarian hypofunction can be caused by the disruption of hormonal regulatory mechanisms by suppressing reproductive hormone synthesis. One of the causes of disruption of the reproductive hormone mechanism is the use of GnRH antagonists namely Cetrorelix acetate in humans which aims to suppress ovum production so that it can cause a decrease in ovarian function or ovarian hypofunction. GnRH antagonists are indicated to suppress the luteinizing hormone surge (LH) that is too early in women. LH suppression occurs due to a decrease in the number of activated GnRH receptors on gonadotropin cells (Beckers and Reila, 1997).

2 MATERIALS AND METHODS

2.1 Tools and Materials

The tools used in this study include terumo® 1 cc syringes, terumo® 3 cc syringes, blades, surgical scissors, anatomical tweezers, serological tweezers, surgical boards, petri dishes, and pins, microtomes, incubators, and optilab microscopes.

Materials used in this study include feed in the form of rabbit pellets (SP®), husks, and sufficient water, Phosphate Buffer Saline (PBS), formalin, alcohol, xylol, 0.9% physiological NaCl, paraffin, Hematoxylin-Eosin dye, and entellan, PBS, primary antibody ERS β brand abcam® (ab288), secondary antibody labeled peroxidase, normal Horse serum 2.5% brand abcam® (ab7484), hydrogen peroxide,

methanol and chromogen diaminobenzidine tetrahydrochloride (DAB) brand abcam® (ab64238).

2.2 Preparation of Animal Ovarian Hypofunction Models

Rats were acclimatized for 7 days to be able to adapt to the new environment. Rats are given feed in the form of rabbit pellets (SP®) and the provision of drinking water by ad libitum. Rats were divided into 3 treatment groups including: control group (KN), the untreated group was only given a placebo NaCl for 17 days. The treatment group was a cetrorelix acetate dose of 0.009 mg/kg BW given for 17 days (P1). The third group was the treatment group with a dose of cetrorelix acetate of 0.0135 mg/kg BW.

2.3 Vaginal Swab Preparations

The method of making vaginal swab preparations carried out in this study by immersing cotton bud in physiological NaCl then the mice to be swab vagina will be placed in a dorsal lying position, after which a vaginal swab is carried out by inserting a cotton bud soaked physiologically NaCl in the vagina by rotating 360°. Then, the cotton bud is removed on the slide and allowed to dry and then fixed using alcohol. The preparations that have been fixed with alcohol and which have dried then are stained with Eosin Negrosin for 15 minutes, then rinsed with running water with a small flow of water and rinsed slowly. After that, the results of vaginal swabs are observed under a microscope with a magnification of 100x and 400x to see vaginal cells. In this study, a vaginal swab was carried out before interfering with the GnRH antagonist to equalize the estrous cycle of rats before starting treatment in this study.

2.4 Collect of Ovary Organs

The rats were euthanized by cervical dislocation. Dislocation is a condition where the joints completely change position without contact with each other (Manuabada and Putu, 2017). Neck dislocation is a physical euthanasia technique by separating the joints between the skull and brain from the spinal cord in the vertebrae. This technique is done by placing the mouse in a ventral fall position, the nape is held with tweezers, then pulled at the base of the tail and the whole body until the mouse dies (Isbagio, 1992).

The rats that have died are dissected vertically from the posterior abdomen to the anterior region and then opening the abdominal and chest cavity. The ovaries were taken together with the uterus, then

separate the ovaries from the mesovarium. The ovaries are prepared from the surrounding fat and washed with physiological NaCl.

2.5 Preparation of Ovarian Histopathology

The histological preparations consist of fixation, dehydration, clarification, paraffin infiltration, embedding, sectioning, sticking to glass objects and coloring. Histopathological changes that will be observed in the description of ovarian histopathology are folliculogenesis, histopathological changes include necrosis, inflammation or other cell damage.

2.6 Observation of Ovarian Estrogen Receptor Beta (ERs β) Expression

Observation of the expression of estrogen beta receptors (ERs β) was observed using the immunohistochemical method. Ovarian histopathological preparations without coloring are incubated for > 24 hours to facilitate deparaffinization. The preparations are soaked in xylol 3 times for deparaffinization, removing paraffin from the tissue as much as possible. The preparations are then soaked in stratified alcohol in sequence (95%, 90%, 80%, 70%) for rehydration, ie re-entering the liquid into the tissue making it easier to stain, then stored in the refrigerator 30⁰ C for > 24 hours. The preparations are washed in distilled water 3 times each for 3 minutes. The preparations are immersed in 3% hydrogen peroxide mixed with methanol in a room temperature humidity chamber for 40 minutes, then washed in PBS for over 3 x 3 minutes. The preparations were incubated with 50% normal serum horse as much as 50 μ L for one night in a humidity chamber at 30C and rinsed again with PBS for 3 x 3 minutes.

Preparations added 40 μ L (primary antibody) anti-ERs β brand abcam® (ab288), for one night at 30C, then rinsed again with PBS for 3 x 5 minutes. The preparations are added with abcam® brand anti-receptor secondary antibodies (ab7484), 40 μ L for 60 minutes at room temperature, then washed with PBS for 3 x 3 minutes. The preparation is dripped with one drop peroxidase, left for 40 minutes, then washed with PBS for 3 x 3 minutes.

The preparation is rinsed again with distilled water. Preparations were added chromogen DAB (3,3-diaminobenzidine tetrahydrochloride) abcam® (ab64238) as much as 40 μ L for 20 minutes at room temperature then washed in distilled water 3 x 5 minutes and counterstained with hematoxylin for 1 minute

at room temperature. The preparation was washed again in the water at pH 8, 3 x 1 minute and let it dry, mounting using an entelan, then the preparation was observed with an optical microscope.

ERs β in the ovary are observed by calculating the average number of cells expressing β ERs. Observation of β ERs in the ovary can be observed in theca cells and granulosa cells. ERs β calculation is done at 400x magnification with 5 visual fields per slide and then analyzed with the help of Immunoratio software (Ridwan et al., 2015).

3 RESULTS AND DISCUSSION

Effect of GnRH Antagonists on Estrogen Beta Receptor Expression (ERs β) in the Ovary Expression of beta estrogen receptors (ERs β) in the ovary can be observed by immunohistochemical (CPI) methods. Ovarian cells that express β ERs will be colored easily brown to dark brown with a certain area. Expression of beta estrogen receptors (ERs β) in the ovary will be expressed in the cells of granulosa cells and germinal epithelium. Physiologically, ERs β show more expression than α ERs in the ovary (Wang *et al.*, 2000).

In this study, the expression of estrogen receptors is expressed in the theca cells of ovarian follicles. The estrogen receptor's expression is colored light brown to dark brown, this indicates that the theca cells express the presence of estrogen that binds to the estrogen receptor in the theca cell. According to Cui *et al.*, (2013) theca cells are cells that synthesize the formation of estrogen in cooperation with granulosa cells during the process of folliculogenesis and ovarian follicle maturation. Estrogen produced will stimulate proliferation and differentiation of theca cells and granulosa cells in ovarian follicles in the process of ovarian follicle maturation. Theca cell differentiation is influenced by several factors, one of which is the Bone Morphogenic Proteins (BMP) and Growth Differentiation Factor-9 (GDF-9) expressed by estrogen-estrogen receptor binding in the transcription process (Young *et al.*, 2010).

The average calculation result of ERs β expression obtained in the control group was 62.58 ± 1.4 , the P1 group was 33.80 ± 1.6 , and the P2 group was 4.87 ± 1.6 . ERs expression of β in the P1 and P2 groups decreased compared to the control group.

Data obtained from the expression of ERs β showed a greater control group (62.58 ± 1.4) when compared to the P1 group (33.80 ± 1.6) and P2 group (4.87 ± 1.6). The ERs β expression values can be seen in table 1.

Table 1. Effects of GnRH antagonists on the expression of ERsβ in rats ovarian hypofunction

Group	Average Expression of ERs β ± standard of deviation
KN (placebo)	62,58 ± 1.4 ^c
P1 (cetorelix acetat 0.009 mg/Kg BW)	33,80 ± 1.6 ^b
P2 (cetorelix acetat 0.0135 mg/Kg BW)	4,87 ± 1.6 ^a

Information :

The notation a, b, c shows that there is a significant difference between one treatment and another

Based on the table above shows that the higher the dose of GnRH antagonists, the lower the expression of ERs β in rat ovaries, the decrease in estrogen receptor beta receptor is due to the response of GnRH antagonists, which gives inhibition of anterior pituitary secretion to secrete primer reproductive hormones. Cetorelix acetate as one of the GnRH antagonists competes with GnRH in the body to bind to membrane receptors on pituitary cells and inhibits the release of Follicle Stimulating Hormone (FSH) and Luteinizing Hormone (LH), thereby delaying LH surge, and it will result in inhibition of ovulatory processes (Rodney, FSH) and Luteinizing Hormone (LH).

The existence of obstacles in these pituitary cells causes obstacles in the process of folliculogenesis. Hampered the process of eating folliculogenesis will result in a decrease in estrogen production which will then cause a decrease in the binding of estrogen hormones to estrogen receptors, one of which is ERs Beta. With this decreased hormone-receptor binding, the expression of beta ERs becomes inactive and unexpressed, this is in accordance with the results in this study that decreased expression of beta receptors in rat ovaries treated with GnRH antagonists. In this case, the administration of cetorelix acetate affects the decrease in expression of beta estrogen receptors in the ovary. The β ERs expression in ovaries can be seen in (Figure 1.)

In this study, it was shown that the decrease in the ERs expression of the control group was greater than the P1 and P2 groups. Decreased expression of ERs β in the treatment groups P1 and P2 are caused by GnRH antagonistic intervention. Exogenous GnRH antagonists that are competitive with endogenous GnRH in binding to estrogen receptors will inhibit endogenous GnRH to inhibit FSH and LH secretion in the anterior pituitary. This inhibition of FSH and LH causes a decrease in the level of FSH and LH in

the blood. The effect of FSH secretion inhibition inhibits the process of folliculogenesis and inhibits ovulation due to low levels of LH in the blood. So that this causes estrogen which is synthesized during the formation, development, maturation of follicles until ovulation occurs. It will experience a disruption in secreting the hormone estrogen in the blood circulation so that it experiences inhibition of folliculogenesis and inhibition of ovulation.

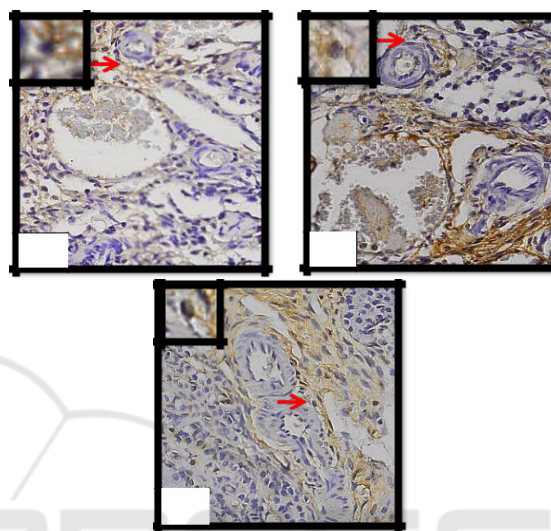


Figure 1. Expression of β ERs by the Immunohistochemical method in the ovary (400x) Information:

- 1: Control (placebo)
- 2: Group P1 (Cetorelix acetate 0.009 mg / kg BW)
- 3: Group P2 (Cetorelix acetate 0.0135 mg / Kg BW)
- : Estrogen Receptor β

In addition, a decrease in estrogen production will cause the lack of estrogen hormone binding with estrogen receptors both ERs β and ERs that is formed so that gene expression also decreases and can cause no emergence of estrous performance. ERs β work is known to affect gamete transport, development, cell growth in the reproductions channel with the presence of GnRH inhibition, which can cause gamete transport disorders, one of which is the disruption of the process of folliculogenesis, LH surge disruption which causes obstruction of ovulation, cell growth and the growth of the female reproductive tract.

3.1 Effects of GnRH Antagonists on Changes in Ovarian Histopathology

In this study, we did a vaginal swab first to determine the last reproduction phase before the euthanized. And based on the results of a vaginal swab conducted before euthanasia showed experimental animals in

the control group (KN), group P1, and group P2 was in the metestrus phase. Physiologically in the metestrus phase is characterized by the development of de Graaf follicles that have ovulated to the corpus luteum. The process of maturation of the corpus luteum produces progesterone whose concentration will peak on the 6th day after ovulation. Progesterone plays a role in influencing the reproductive tract to maintain pregnancy in the event of fertilization (Akbar, 2010).

The control group showed a follicle that had just ovulated which was called the corpus haemorrhagicum which would develop into the corpus luteum (Figure 2A). Follicles that successfully reach ovulation are dominant follicles that have gone through 2 to 3 follicular waves during the estrous cycle period. Dominant follicles produce estrogen which can suppress the growth of other small follicles (Jainudeen and Hafez, 2000). Besides corpus haemorrhagicum, corpus luteum and primary, secondary and atresia follicles are also found. This shows that the control group that was only given a placebo still showed normal ovarian activity.

A follicular wave is defined as a process of follicular growth that is synchronous with several small follicles. One of these small follicles is selected to grow into a dominant follicle, while the other small follicles will stall their growth into follicular atresia. Atresia follicles that are formed will cause a new follicular wave that is the second follicular wave. The dominant follicle in the second follicular wave will become anovulatory, while the dominant follicle in the third wave will ovulate (Siregar, 2010). Other follicles such as primary follicles and secondary follicles encountered in the negative control group indicate a new wave of follicles in the ovaries.

P1 group by giving Cetrorelix acetate dose 0.009 mg/kg BW showed that there was a small number of tertiary follicles observed and the formation of atresia follicles was like the control group. This can be caused when the animal is given induction of GnRH antagonist ovarian status in the mouse model of ovarian hypofunction cell death occurs in the development of follicles de graaf into corpus luteum. Physiologically, de graaf follicles that have failed in ovulation then the de graaf follicles will be eliminated and turn into follicular atresia. Whereas in the P2 group that was given a Cetrorelix acetate dose of 0.0135 mg/kg BW the primary and secondary follicles were observed in large amounts compared to follicular development. The growth of primary and secondary follicles classified as quite a lot in the P2 group compared to the P1 and K groups can be assumed that in the group given the GnRH antagonist

intervention experienced inhibition of folliculogenesis so that the primary and secondary follicles do not experience follicular development into the antral follicle. In addition, the P3 group also found a lot of follicles that experience necrosis.

Necrosis is the first step of ovarian cell damage that can result in apoptosis (cell death) so that it will decrease the secretion of the hormone estrogen and decrease the expression of ERs. An image of the changes in ovarian histopathology in mice with ovarian hypofunction models can be seen in Figure 2.

GnRH antagonists induced in the treatment group gave a difference between the treatment group and the negative control group. The increasing number of primary and secondary follicles in the negative control group, the P1 treatment group, and the P2 treatment group occurs because the growth of primary and secondary follicles does not depend on GnRH so that the induction of GnRH antagonists has no effect on the preantral follicle (Puspitasari, 2011). The development of primordial follicles into primary follicles and primary follicles into secondary follicles depends on the nutrition provided (Ramadhani et al., 2017). The decrease in the number of tertiary follicles in groups P1 and P2 shows that GnRH antagonists are able to inhibit the development of antral follicles that depend on GnRH. The increase in the number of atresia follicles in the antral follicle along with the increasing dose of GnRH antagonist shows that the induction of GnRH antagonist is able to increase the number of atresia follicles.

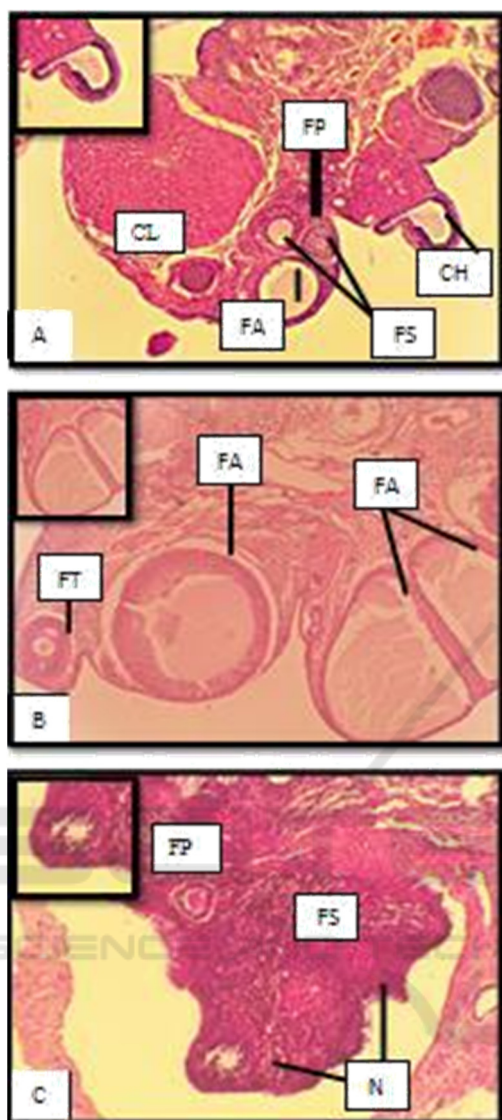

Figure 2. Histological features of folliculogenesis in the ovaries of Rats (HE, 40x); FA (Atretic follicular); FP (Primary follicles); FS (Secondary follicles); FT (Tertiary Follicles); FD (De Graaf Follicular); CH (Corpus Haemorrhagicum); N (Necrosis)

Description :

- (A) K : Control (placebo)
- (B) P1: Cetrorelix acetate (0.009 mg / Kg BW)
- (C) P2 : Cetrorelix acetate(0.0135 mg / Kg BW)

Follicles that undergo a degenerative process before reaching the ovulation stage are called follicular atresia. This degenerative process occurs normally to select follicles, so only follicles that contain healthy oocytes are ovulated. According to Hsueh et al., (1994) there are 3 theories that explain the causes of atresia in a follicle. The first theory

explains that follicles experience atresia due to deficiencies in the genetic component, oocyte cytoplasm, somatic cells, and follicular environment. The second theory explains that the follicle is exposed to teratogenic factors that carry the follicle into the degenerative pathway. The third theory explains that atresia is the fate of all follicles when going through a critical stage in the follicle unless the critical stage coincides with FSH stimulation, the follicle will continue to develop and become a dominant follicle. An increase in the number of follicular atresia with increasing dose of GnRH antagonist shows decreased FSH stimulation due to induction of GnRH antagonist and does not coincide with the critical stage of the follicle. Durlinger et al., (2000) research on atresia follicles in pre-ovulatory follicles due to GnRH antagonist states that evaluation of atresia follicles is done by observing the thickness of the granulosa cell layer which is getting thinner. Cumulus oophorus in de Graaf follicles also experiences thinning. Atresia follicles in the growing follicles and de Graaf follicles will cause the following changes: (1) The oocyte becomes the first degenerated structure then disappears; (2) The zona pellucida swells and disappears most recently; (3) The granulosa cells degenerate so that the granulosa membrane boundaries become irregular because the cells are scattered and disappear as well; (4) Internal theca cells in the follicle will become theca lutein cells, eventually the atresia follicles will become the corpus albican (Hestianah et al., 2014).

Further research on the use of GnRH antagonists in ovarian stimulation for IVF programs is ongoing. According to Macklon and Fauser, (2000) the initial step of the IVF program, namely the administration of GnRH antagonists, aims to utilize dominant follicles that develop from primordial follicles to secondary (preantral) follicles. Dominant follicles are follicles with granulosa cells which are more sensitive to FSH stimulation. This causes the less FSH to be stimulated, the greater the potential for FSH to only affect the dominant follicle. Non-dominant follicles will lack FSH then become follicular atresia. A decreased FSH concentration will leave a dominant follicle ready for maturation. GnRH antagonists were given at a dose of 0.0135 mg/kg BW in the P2 group causing damage in the form of necrosis of the antral follicle in the ovary. This is in accordance with research Safitri et al., (2012) regarding the condition of ovarian hypofunction caused by malnutrition showing histopathological conditions in the form of necrosis, congestion, and edema in ovarian follicles. Degeneration and necrosis of ovarian follicles indicate that there is no development in ovarian follicles. This

is in accordance with the case study of Kesler and Gaverick, (1982) which states the condition of ovarian hypofunction is caused by hormonal deficiency and imbalance resulting in anestrus and estrus which is not accompanied by ovulation. This hormonal imbalance affects the function of the anterior pituitary so that the production of FSH and LH is low which causes the ovaries to not develop.

According to Griesinger *et al.*, (2005) GnRH antagonists were able to reduce FSH levels by 75%, LH levels by 84%, and estrogen until undetectable within 36 hours. The activity of the hormone estrogen requires binding to receptors to stimulate stromal and epithelium cell proliferation. and β receptors work homologously with each other and have a high affinity for estrogen. Decreased estrogen levels due to the administration of GnRH antagonists in the treatment groups P1 and P2 will reduce estrogen binding estrogen receptors thereby reducing the expression of estrogen receptors in both ERs β and α . This causes the transcription process that occurs because estrogen bonds and estrogen receptors decrease and cause gene expression to also decrease so that it interferes with cell proliferation in the target cell. The proliferation of disturbing cells will cause inhibition of folliculogenesis in the ovary (Cooke *et al.*, 1998). This inhibition of folliculogenesis will result in decreased estrogen levels. A decrease in estrogen levels and estrogen bind with ERs causes no positive feedback to the hypothalamus so that GnRH does not stimulate the anterior pituitary to produce LH, and LH surge does not occur so ovulation will never occur (Hafizuddin *et al.*, 2012).

4 CONCLUSIONS

GnRH antagonists were able to reduce ERs β expression in white rats in the P2 treatment group at a dose of 0.0135 mg / Kg BW and GnRH antagonists were able to inhibit the development of ovarian follicles namely tertiary follicles and de Graaf follicles in the ovarian histopathology picture in the P1 and P2 treatment groups and cause the occurrence of necrosis in the ovarian histopathology picture of the P2 treatment group approaching the condition of ovarian hypofunction.

ACKNOWLEDGMENTS

We would like to thank to LPPM Universitas Brawijaya and the Faculty of Veterinary Medicine,

Universitas Brawijaya for providing research assistance and support funds until the completion of the Ovarian Hypofunction Rats Model with the antagonist GnRH Induction.

REFERENCES

- Beckers, T., Reilaänder, H. & Hilgard P. (1997). Characterization of Gonadotropin-releasing Hormone Analogs Based on a Sensitive Cellular Luciferase Reporter Gene Assay. *Anal Biochem*; 251:17–23.
- Caldon, C. E. (2014). Estrogen Signaling and The DNA Damage Responses in Hormone Dependent Breast Cancers. *Frontiers in Oncology*, 4 (106), 1-6.
- Cooke, P. S., Buchanan, D. L., Lubahn, D. B. & Cruncha, G. R. (1998). Mechanism of Oestrogen Action: Lesson from the Oestrogen Receptor-*Biol. Reprod* 59: 470-475.
- Cui, J., Yong S., Rena L. 2013. Estrogen Synthesis and Signaling Pathways During Ageing: From Periphery to Brain. *Trends Mol Med* 19(3):197-209.
- Durlinger, A. L. L., Piet K., Bas K., Anton J. G., Jan T. J. U., & Axel P. N. T. (2000). Apoptotic and Proliferative Changes During Induced Atresia of Pre-ovulatory Follicles in Rat. *Human Reproduction* Vol. 15(12): 2504-2511.
- Edson, M. A., Ankur K. N., & Martin M. M. (2009). The Mammalian Ovary from Genesis to Revelation. *Endocrine Reviews* Vol. 30(6): 624-712.
- Gitonga, P. N. (2010). *Postpartum Reproductive Performance of Dairy Cows in Medium and Large Scale Farms in Kiambu and Nakuru Districts of Kenya*. University of Nairobi Faculty of Veterinary Medicine.
- Griesinger, G., Ricardo F., & Klaus D. (2005). GnRH Antagonist in Reproductive Medicine. *Arch Gynecol Obstet* Vol. 273: 71-78.
- Hafizuddin, Tongku, N. S., & Muslim A. (2012). Hormon dan Perannya dalam Folikuler pada Hewan Domestik. *JESBIO* Vol. 1(1): 21-24.
- Hermadi, H. A. (2015). *Pidato. Pemberantasan Kasus Kemajiran pada Ternak Menuju Kemandirian di Bidang Kesehatan Reproduksi Hewan dan Ketahanan Pangan di Indonesia*. Surabaya: Universitas Airlangga.
- Hestianah, E. P., Chairul, A., Suryo, K., & Lita, R. Y. (2014). *Buku Ajar Histologi Veteriner Jilid 2*. Surabaya: Universitas Airlangga Press.
- Hsueh, A. J. W., Hakan, B., & Alex, T. (1994). Ovarian Follicle Atresia: A Hormonally Controlled Apoptotic Process. *Endocrine Reviews* Vol. 15(6): 707-724.
- Isbagio, D. W. (1992). Euthanasia pada Hewan Percobaan. *Media Litbangkes* Vol. 2 (1): 18-24.
- Jainudeen, M.R. & Hafez, E.S.E. (2000). Cattle and Buffalo. In B. Hafez, and E.S.E. Hafez (Eds.). *Reproduction in Farm Animals*. Lippincott Williams and Wilkins, Philadelphia. Halaman: 159-171.

- Kesler, D.J. & Garverick, H.A. (1982). Ovarian Cysts in Dairy Cattle : A review. *Journal of Animal Science* 55: 1147-1159.
- Lestari, C.M.S., Purbowati, E., Dartosukarno, S., Rianto, E. (2014). Sistem Produksi dan Produktivitas Sapi Jawa-Brebes dengan Pemeliharaan Tradisional. (Studi Kasus diKelompok Tani Ternak Cikoneng Sejahtera dan Lembu Lestari Kecamatan Bandarharjo Kabupaten Brebes). *J. Peternakan Indonesia* 16(1): 8- 14.
- Li, H. & Ri-Cheng, C. (2017). *Follicular Development and Oocyte Growth*. Shanghai: Springer International Publishing.
- Manuaba, I. B. T. W dan Putu A. 2017. *Buku Panduan Belajar Koas: Ilmu Bedah*. Denpasar: Rumah Sakit Umum Pusat Sanglah.
- Pradhan, R. & Nakagoshi, N. (2008). Reproductive Disorders in Cattle Doe to Nutritional Status. *J of Inter Dev and Coop* 14: 45-66.
- Puspitadewi, S. & Sunarno. Potensi Agensi Anti Fertilitas Biji Tanaman Jarak (*Jatropha curcas*) dalam Mempengaruhi Profil Uterus Mencit (*Mus musculus*) Swiss Webster. *Artikel Penelitian* Vol.5(2): 55-60.
- Puspitasari, Y. (2011). Efek Ekstrak Etanol Biji Pepaya (*Carica papaya Linn*) terhadap Kadar 17-B Estradiol dan Folikulogenesis pada Mencit Betina (*Mus musculus*) [THESIS]. Fakultas Kedokteran. Universitas Airlangga.
- Ramadhani, S. A., Iman, S., Ni, W. K. K., & Adi W. (2017). Pengendalian Folikulogenesis Ovarium dengan Pemberian Ekstrak Biji Kapas. *Jurnal Sain Veteriner* Vol. 35(1): 71- 80.
- Ridwan, A. J., Sri, S., & Abdul, H. H., & Bethy S. H. (2015). Analysis of Immunoeexpression of Estrogen Receptor Beta and Extracellular Matrix Metalloproteinase Inducer (EMMPRIN) on Testicular Seminomas Nonrecurrence and Recurrence. *Journal of Medicine and Health* Vol. 1(2): 113-125.
- Ridwan, E. 2013. Etika Pemanfaatan Hewan Percobaan dalam Penelitian Kesehatan. *J Indon Med Assoc* Vol. 63 (3).
- Rosadi, B., Teguh, S., & Fachroerrozi, H. (2018). Identifikasi Gangguan Reproduksi pada Ovarium Sapi Potong yang Mengalami Anestrus Postpartum Panjang. *Jurnal Veteriner* Vol.19 (3): 385-389.
- Safitri, E., Tatik, H., Suzanita, U., Sri, M., Djoko, L. (2012). Penurunan Estrus dan Gambaran Histopatologis Ovarium Mencit (*Mus musculus*) Betina Kondisi Malnutrisi. *Veterinaria Medika* Vol. 5(3): 207-214.
- Siregar, T.N. (2010). Fisiologi Reproduksi Hewan Betina. Syiah Kuala University Press, Banda Aceh. Halaman: 25-39.
- Sutiyono, Daud S., Alam S. 2017. Identifikasi Gangguan Reproduksi Sapi Betina di Peternakan Rakyat. *Jurnal Veteriner* Vol.18 No.4: 580-588.
- Wang, H., Hakan E., Lena S. 2000. Estrogen Receptors a and b in the Female Reproductive Tract of the Rat During the Estrous Cycle. *Biology for Reproduction* 63: 1331-1340.
- Yahya, M. I. 2017. Tingkat Kejadian Gangguan Reproduksi Ternak Sapi Perah di Kabupaten Enrekang [Skripsi]. Fakultas Peternakan. Universitas Hasanuddin.
- Young, J. M., McNeilly, A. S. 2010. Theca : The Forgotten Cell of the Ovarian Follicle. *Society for Reproduction and Fertility* 140: 489-504.