

# Evaluation of Anti-ulcer Effect of Papaya Juice in Combination with Cumin Seed in Ethanol Induced Peptic ulcers in Experimental Rats

Kiran Chanabasappa Nilugal<sup>1\*</sup>, Santosh Fattepur<sup>1</sup>, Visallani Veerapandian<sup>1</sup> Fadli Asmani<sup>1</sup>, May Florence Dela Cruz Bacayo<sup>1</sup>, Ibrahim Abdulah<sup>1</sup>, Eddy Yusuf<sup>2</sup>

<sup>1</sup>*School of Pharmacy, Management and Science University Shah Alam Selangor, Malaysia,*

<sup>2</sup>*School of Graduate studies, Management and Science University Shah Alam Selangor*

**Keywords:** Anti-ulcer effect, cumin seed, papaya, ulcer index.

**Abstract:** A disease which impairs the quality of life and associated with increased morbidity and mortality and a worldwide problem is known as peptic ulcer. Ulceration is resulting with the elevated acid secretion, and diminished mucosal resistance due to Helicobacter pylori infection, NSAID's, alcohol intake and tobacco smoking. This study was carried out to find out the anti-ulcer activity of papaya juice mixed with cumin seed extract in ethanol induced peptic ulcer in rats. Healthy adult female albino rats were used for this study. The rats were divided into five groups with six rats each. Omeprazole 20mg/kg were used as a standard drug. Group 1: Control group, Group 2: Positive group, Group 3: Standard group which received Omeprazole, Group 4: Extract test group which received papaya juice (20ml/kg) mixed with cumin seed with strength of (2.5ml/kg), Group 5: Extract test group which receives papaya juice (20ml/kg) mixed with cumin seed with the strength of (5ml/kg). Ethanol will be given in dose of 1ml per rat orally to Group 2, 3, 4 and 5 animal groups on the 8<sup>th</sup> day of experiment. The rats were sacrificed and stomachs were opened. Ulcer index and histological changes were studied. The results of the study exhibit that papaya juice in combination with cumin seed extract has significant anti-ulcer activity with p value <0.05 through statistical analysis and there is decrease in ulcer score comparable to omeprazole. The extract group has better ulcer protective compared to control indicating the plants possess significant anti-ulcer property in a dose dependent manner.

## 1 INTRODUCTION

The occurrence of peptic ulcer is as a result from an imbalance between mucosal defensive mechanism, which includes prostaglandin, mucus production, bicarbonate and also the maintenance of the mucosal blood flow, presence of acid and pepsin in the luminal surface of the gastric mucosa is also a damaging factor in peptic ulcer. There are also many aggregating factors which can cause gastric damages including Helicobacter pylori infection, ethanol consumption, NSAID usage, dietary habits and stress (Laine et al., 2008). Although there are many conventional treatments such as proton pump inhibitors, H2 receptors blocker and antibiotics for the eradications of H.Pylori or NSAID withdrawal to help in peptic ulcer recovery. However, these treatments are observed to be insufficient for a complete ulcer healing and also frequently with ulcer recurrence (Quan and Talley, 2002).

Papaya is believed to prevent and cure a variety of medical conditions including gastric reflux, stomach ulcers and arthritis. Papaya enzyme commonly known as papain and are sold as a dietary supplement. However, here's no scientific evidence to support these claims (K.K, 2011). It also has anti-oxidant properties in stabilizing lipids contributing to its gastroprotective effects. Besides, papaya also has a rich source of Vitamin C. Vitamin C has well established anti-oxidant property. (Gayosso-García Sancho, Yahia, & González-Aguilar, 2010).

It is well known that free radicals are involved in the progression of ulcer. Studies showed that triterpenoids isolated from various species of cumin seeds has been reported to have anti-inflammatory activities. Literature has also revealed cumin seeds anti-oxidant property and their free radical scavenging activity contributing to its anti-ulcer property (Gill, N. S et al., 2009).

This study is to examine the protective effect of papaya juice with cumin seed against ethanol-induced gastric damage in rats. Omeprazole, a proton pump inhibitor commonly prescribed drug for increased gastric acid secretion and gastric ulcer will be used as a reference drug for comparison.

## 2 METHODS

### 2.1 Collection of Plant Materials and Preparation of Plant Juice and Plant Extract

The required amount of papaya fruit was brought from a local market. The fruit and plants were analyzed and confirmed after acquisition. The papaya fruit was cleaned using sanitized water and cut into small pieces. The fruit was thoroughly washed. The fruits were grounded in a mechanical mixer to get the juices and filtered through muslin cloth. The juice was stored in an airtight container and kept under 4°C until further use (S. Gopinathan, D. Naveenraj, 2013). Required amount of cumin seed (*Cuminum cyminum* L.) was brought from local market. The seeds were dried and were crushed and grounded using a grinder. The powdered cumin seed was soaked using 80% ethanol for 72 hours. After 3 days, the mixture was filtered using muslin cloth. The mixture was then distilled under reduced pressure in rotary evaporator until thick mucilage was obtained and stored at 4°C until further use (Safoura Derakhshan *et al.*, 2008). The mucilage then was dissolved in sterile distilled water and administered orally to the rats with the concentration of 2.5ml/kg and 5ml/kg.

### 2.2 Experimental Animals

Healthy Wistar Albino female rats weighing between 160-220gm were used for the study. The study was performed in the experimental laboratory in the Department of Pharmacology after getting approval from the Institutional Animal Ethical Committee. The rats were obtained from the local vendor and domiciliated in polypropylene cages at 25±2°C in the university animal house and maintained on pellet feed and clean water for two weeks before the experimentation.

### 2.3 Ethanol Induced Ulcers

Healthy Wistar Albino female rats were divided into 5 groups of six animals each.

Group 1: Control group. Received only normal saline water.

Group 2: Positive group. Rats will be administered with ethanol (1ml per rat) orally as positive control group on the 8th day. (Subramanian S *et al.*, 2007)

Group 3: Standard drug group. Rats will be pre-treated with Omeprazole (20 mg/kg/day) orally for 8 consecutive days. Then administer ethanol (1ml) orally on the 8th day. (Sai Krishna Borra, *et al.*, 2011)

Group 4: Extract test group. Rats will be pre-treated with papaya juice (20ml/kg) combine with cumin seed extract (2.5ml/kg) orally for 8 consecutive days. Then, administer ethanol (1ml) orally on the 8th day.

Group 5: Extract test group. Rats will be pretreated with papaya juice (20ml/kg) combine with cumin seed extract (5ml/kg) orally for 8 consecutive days. Then administer ethanol (1ml) orally on the 8th day.

### 2.4 Induction of Ulcer

Animals in group 2, 3, 4 and 5 were taken as peptic ulcer induced groups. The animals were kept for fasting for 24 hours but were given access to water ad libitum prior to drug administration. The 24 hours fasted animals were administered with ethanol 95% in a dose of 1ml per rat orally. Six hours after administration of the drug, the animals were then sacrificed under anesthesia, stomachs were opened and washed with normal saline and fixed in 5% formalin solution.

### 2.5 Statistical Analysis

The data in this research were analyzed statistically by using one-way analysis of variance (ANOVA) using SPSS 21.0 software followed by Dunnett's test for control, standard and test group comparisons were used for statistical evaluation. The results were expressed as "mean total severity score ± SD". P values <0.05 were considered as significant and P < 0.05 as significant.

## 3 RESULT

By an overdose of anesthesia, the animals were sacrificed by decapitation and the stomachs were open along the curvature, rinsed with normal saline

and the gastric contents were collected. The total numbers of ulcers in each stomach were noted along with the petechial hemorrhage congestion, etc. It was then examined by a magnifier lens (10x) to assess the size of ulcer formation. The ulcers were first graded and ulcer index was determined according to grades of ulcer severity where 0 = No ulcer, 1 = Superficial ulcer, 2 = Deep ulcer, 3 = Perforation. Ulcer index were calculated as  $[UI] = UN + US + UP \times 10^{-1}$  where, UN – Average number of ulcers per animal, US – Average severity scores, UP – Percentage of animals with ulcers. A comparison of ulcer index was made between the treatment groups and control group. The results are showed in table 1, figure 1 and figure 2

### 3.1 Macroscopic Evaluation of Gastric Mucosa in Rats

Macroscopic evaluations were performed to determine the therapeutic effects of the different doses of extract (group 4 and 5), positive control (group 2), negative control (group 1) and standard (group 3) on ethanol-induced gastric damage shown in (figure 3). Results revealed that pretreatment of wistar rats with combination of papaya juice and cumin seed extract significantly diminished the UA compared to the ulcerated group. The inhibition percentage of the UA in rats pre-fed with combination of papaya juice and cumin seed extract was increased in a dose-dependent manner.

### 3.2 Histopathology

A portion of the ulcer region in the stomach was stored in 5% buffered neutral formalin solution for histological observation. Then, the tissue was embedded in paraffin. A solid section of the ulcer region was cut out to a size of 5µm and stained with hematoxylin and eosin. This solid section was examined with the help of a light microscope and photomicrographs were taken. The microscopic examination of the gastric mucosal surface cells in the ethanol-induced groups showed some extent of necrosis, identified by highlighted cytoplasm and compressed and dingy nuclei. Some parts of the mucosal cells were separated and the glandular epithelium cells were necrotic up to the middle. The depth of the ulcers was less in the treatment groups than in the extract groups. Microscopic examination showed no pathological changes in the mucosa of the control group. Most cases showed columnar mucosal cells with clear

cytoplasm and, in some cases, capillary hyperemia (figures 4).

Table 1 Ulcer Index and Percentage Inhibition comparison between each animal groups

Group	Treatment	Ulcer Index	Percentage Inhibition
2	Positive Control	59.967 ± 0.2160	0%
3	Omeprazole	13.750 ± 0.1378*	77.00%
4	Test group (papaya 20ml/kg + Cumin seed 2.5ml/kg)	36.983 ± 0.1472*	38.33%
5	Test group (papaya 20ml/kg + Cumin seed 5ml/kg)	32.017 ± 0.3189*	46.52%

The ulcer index values are expressed as means ± S.E. of 6 rats in each group, \*p<0.05 when compared with control group. (Statistically analyzed by one-way analysis variance (ANOVA) followed by Dunnet's t-test.)

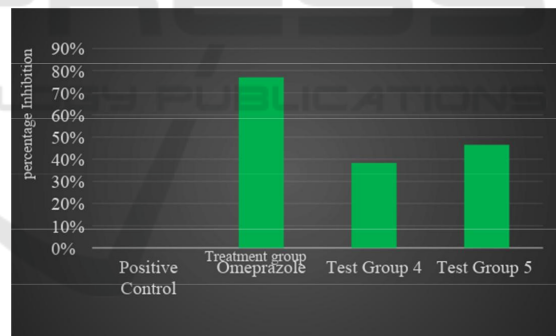


Figure 1 Graph of percentage inhibition graph according to each groups

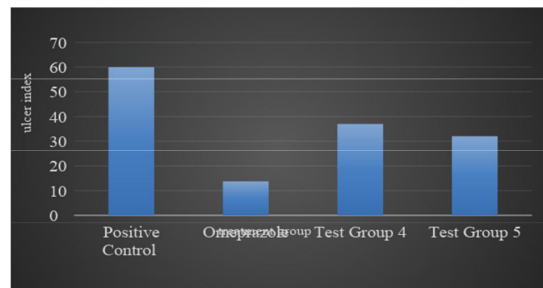
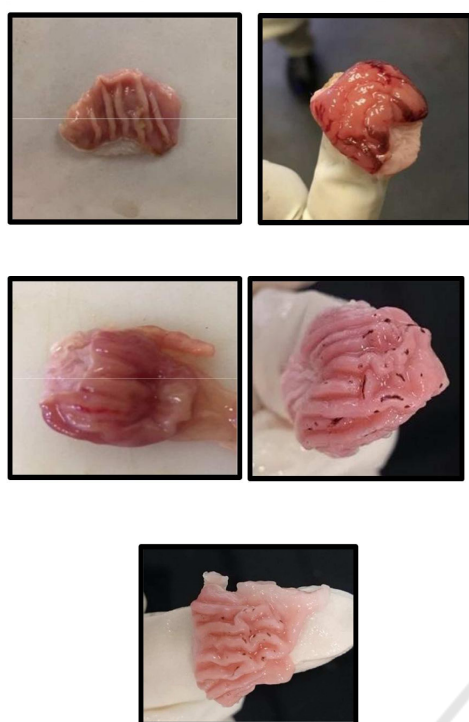
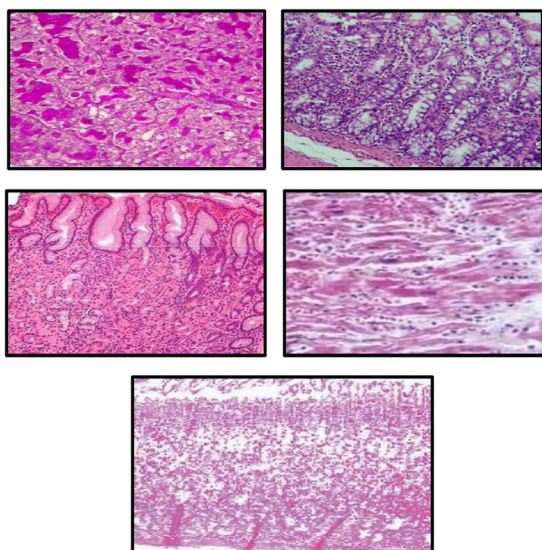


Figure 2 The ulcer index graph according to each group



**Figure 3:** The effect of papaya juice and cumin seed extracts on the the macroscopic appearance of the gastric mucosa in ethanol-induced gastric mucosal lesions in male SD rats.

**Notes:** GROUP 1 (normal control group) shows gastric mucosa is healthy, GROUP 2 (ulcerated control group) shows gastric leisons, GROUP 3 (omeprazole) shows mild disruption of gastric mucosa, GROUP 4 shows mild to moderate disruption of epithelium and GROUP 5 shows moderate disruption of epithelium.



**Figure 4:** The effect of papaya juice and cumin seed

extracts on the histology (hematoxylin and eosin staining) of ethanol-induced gastric mucosa damage in female wistar rats.

**Notes:** GROUP 1 (normal control group) shows parietal cells has normal cell arrangement. Parietal cells appeared to have huge pale stained nuclei and the cells appeared healthy GROUP 2 (ulcerated control group shows gastric ulceration with de-epithelization. The parietal cells distorted and the arrangements of cells are abnormal. The cells appeared dark. There is also visible edema with leucocyte infiltration observed. GROUP 3 (omeprazole) shows the arrangement of parietal cells are in orderly manner with pale stained nuclear. GROUP 4 (shows the arrangement of few cells are abnormal, some cells appeared darker. GROUP 5 shows most of the parietal cell arrangement are orderly and most of it are with pale stained nuclear.

#### 4 DISCUSSION

Peptic ulcer happens due to imbalance between aggressive factor and the maintenance of mucosal integrity through the endogenous defense mechanism. Different conventional medicine traditional medicine plant extract and fruits can be used to regain this balance. The actual cause of gastric ulcer is *Helicobacter pylori* (*H. pylori*) and the use of non-steroid anti-inflammatory drugs (O'Malley, 2003). In addition to these well identified causes, excessive ingestion of ethanol can be a major cause of gastric ulcer (Guslandi,1987), by increasing the mucosal permeability and releasing vasoactive products, leading to vascular damage and cell necrosis. Many studies have shown that reactive oxygen species (ROS) are involved in the pathogenesis of a wide variety of clinical disorders and specially ethanol induced ulcers. Cells have developed enzymatic e.g. catalase (CAT), superoxide dismutase (SOD), glutathione peroxidase (GPx) and non-enzymatic endogenous glutathione (GSH) antioxidant protective mechanisms to prevent oxidative damages (Dinagharan S. et al., 2015).

The study is to investigate the anti-ulcer effect of papaya juice combine with cumin seed extract with specified dose. The result shows that this combination does produce significant reduction and inhibition in ulcer induced by ethanol 95%. Test group 4 which has been given with papaya juice 20ml/kg combine with cumin seed extract

2.5ml/kg has revealed the severity score of  $36.983 \pm 0.1472$  with the 38.55 % of percentage



inhibition comparable to standard group omeprazole which has the severity score of  $13.750 \pm 0.1378$  with 77% of percentage inhibition. Statistical analysis shown that the p value of test group 4 in compare to positive control group is less than 0.05 indicating that this plant combination does have significant reduction of ulcer score and do have ulcer protection. There is reduction of average ulcer number in test group 4 which is 18 comparing to positive control group having average ulcer number of 28.

Test group 5 which has been given with papaya juice 20ml/kg combine with cumin seed extract 5ml/kg has revealed the severity score of  $32.017 \pm 0.3189$  with the 46.52% of percentage inhibition comparable to standard group omeprazole which has the severity score of  $13.750 \pm 0.1378$  with 77% of percentage inhibition. Statistical analysis shown that the p value of test group 5 in compare to positive control group is also less than 0.05 indicating that this plant combination does have significant effect in reduction of ulcer score and do have ulcer protection. There is reduction of average ulcer number in test group 5 which is 15 comparing to positive control group having average ulcer number of 28. Test group 5 has slightly better ulcer protection than test group 4 due to increased treatment dose of cumin seed extract combine with fresh papaya juice. Papaya juice exert its gastroprotective effect by free radical scavenging action while cumin seed has higher composition of fatty acids. Fatty acids contribute to human as an important nutrient. It has various health benefits. Saturated and unsaturated fatty acids from various seed oil sources showed good antioxidant activities. Higher dose of cumin seed in test group 5 has contributed better ulcer protective characteristic in compare to test group 4.

## 5 CONCLUSION

To conclude, the studies have conducted revealed that papaya juice in combination with cumin seed extract are advantageous in healing peptic ulcers arising from 95% ethanol (reactive oxygen species) administration compared to standard drug Omeprazole. The main properties of these plants that believed to be contributing to ulcer healing are their anti-oxidant characteristics. The experimental evidence achieved in the present studies shows that these combinations of plants contributes to the anti-ulcer effect and gastro protective properties in dose dependent manner where the higher the dose of the

plants combination, the better the healing percentage.

As a recommendation for further analysis of the plants' anti-oxidant properties, biochemical analysis such as myeloperoxidase (MPO) activity, malondialdehyde (MDA) level and superoxide dismutase activity can be studied. Besides, these combinations of plant juice and seed extract shows its anti-ulcer activities in dose dependent manner. Therefore, in further studies, can increase the dose to observe if these plants possess anti-ulcer activity more nearly or as equal to Omeprazole as well as observe if there is any possible side effects related to the dose.

## REFERENCES

- Abisola, O. T., & Wahab, O. A. (2012). Gastro-protective activity of aqueous *Carica papaya* seed extract on ethanol induced gastric ulcer in male rats. *Afr. J. Biotechnol. African Journal of Biotechnology*, 11(34). Retrieved April 4, 2016, from <http://www.academicjournals.org/AJB>
- Ani, V., & Naidu, K. A. (2007). Antihyperglycemic activity of polyphenolic components of black/bitter cumin *Centratherum anthelminticum* (L.) Kuntze seeds. *Eur Food Res Technol European Food Research and Technology*, 226(4), 897-903. doi:10.1007/s00217-007-0612-1
- Batt, S. P., Rizvi, W., & Kumar, A. (2014). Effect of *Cuminum cyminum* L. Seed Extracts on Pain and Inflammation. Effect of *Cuminum Cyminum* L. Seed Extracts on Pain and Inflammation, 14. Retrieved April 24, 2016, from <http://www.jnronline.com>
- Bhattacharyya, A., Chattopadhyay, R., Mitra, S., & Crowe, S. E. (2014). Oxidative Stress: An Essential Factor in the Pathogenesis of Gastrointestinal Mucosal Diseases. *Physiological Reviews*, 94(2), 329-354. doi:10.1152/physrev.00040.2012
- Biswas, K., Bandyopadhyay, U., Chattopadhyay, I., Varadaraj, A., Ali, E., & Banerjee, R. K. (2003). A Novel Antioxidant and Antiapoptotic Role of Omeprazole to Block Gastric Ulcer through Scavenging of Hydroxyl Radical. *Journal of Biological Chemistry*, 278(13), 10993-11001. doi:10.1074/jbc.m210328200
- Borra, S. K., Lagisetty, R. K., & Mallela, G. R. (2011). Anti-ulcer effect of *Aloe vera* in non-steroidal anti-inflammatory drug induced peptic ulcers in rats. *Afr. J. Pharm. Pharmacol. African Journal of Pharmacy and Pharmacology*, 5(16). Retrieved April 4, 2016, from [http://www.academicjournals.org/article/article1380814032\\_Borra et al.pdf](http://www.academicjournals.org/article/article1380814032_Borra%20et%20al.pdf)
- Derakhshan, S., Sattari, M., & Bigdeli, M. (2008). Effect of subinhibitory concentrations of cumin (*Cuminum cyminum* L.) seed essential oil and alcoholic extract

- on the morphology, capsule expression and urease activity of *Klebsiella pneumoniae*. *International Journal of Antimicrobial Agents*, 32(5), 432-436. Retrieved April 4, 2016, from <https://elibrary.ptpl.edu.my:3840/#!/content/journal/1-s2.0-S0924857908002355>
- Dinakaran, S., Sridhar, S., & Eganathan, P. (2015). CHEMICAL COMPOSITION AND ANTIOXIDANT ACTIVITIES OF BLACK SEED OIL (*NIGELLA SATIVA* L.) . *International Journal Of Pharmaceutical Sciences And Research*. Retrieved April 20, 2017, from <http://ijpsr.com/bft-article/chemical-composition-and-antioxidant-activities-of-black-seed-oil-nigella-sativa-1/?view=fulltext>
- Fahmy, S. R., Amer, M. A., & Al-Killidar, M. H. (2015). Ameliorative effect of the sea cucumber *Holothuria arenicola* extract against gastric ulcer in rats. *The Journal of Basic & Applied Zoology*, 72, 16-25. doi:10.1016/j.jobaz.2015.03.001
- Gill, N. S., Grag, B. R., Sood, S., Muthuraman, A., Bali, M., & Sharma, P. D. (2009). Evaluation of antioxidant and antiulcer potential of cucumins sativum L. Seed Extract in rats. *Asian Journal of Clinical Nutrition*, 131-138. Retrieved April 23, 2017, from file:///D:/sem6/RESEARCH/research%20references/anti-inflammation%20and%20anti-ulcer%20of%20cumin%20seed.pdf.
- Gopinathan, S., & Naveenraj, D. (2013). Gastroprotective and Anti-ulcer activity of Aloe vera juice, Papaya fruit juice and Aloe vera and Papaya fruit combined juice in Ethanol induced Ulcerated Rats. Gastroprotective and Anti-ulcer Activity of Aloe Vera Juice, Papaya Fruit Juice and Aloe Vera and Papaya Fruit Combined Juice in Ethanol Induced Ulcerated Rats. Retrieved April 24, 2016, from <http://www.ijddr.in>
- Hassan, Z., Yam, M. F., Ahmad, M., & Yusof, A. P. (2010). Antidiabetic Properties and Mechanism of Action of *Gynura procumbens* Water Extract in Streptozotocin-Induced Diabetic Rats. *Molecules*, 15(12), 9008-9023. doi:10.3390/molecules15129008
- Junior, I. F., Balogun, S. O., Oliveira, R. G., Damazo, A. S., & Martins, D. T. (2016). *Piper umbellatum* L.: A medicinal plant with gastric-ulcer protective and ulcer healing effects in experimental rodent models. *Journal of Ethnopharmacology*, 192, 123-131. doi:10.1016/j.jep.2016.07.011
- Laurence LB (1996). Agents for control gastric acidity and treatment of peptic ulcer. *Goodman and Gilman's The pharmacological basis of Therapeutics*; 9th edn: (Joel G Hardman, Alfred Goodman Gilman; Lee E Limbird.eds) The Mcraw-Hill Companies, New York. pp. 901-914.
- Lutterodt, H., Luther, M., Slavin, M., Yin, J., Parry, J., Gao, J., & Yu, L. (. (2010). Fatty acid profile, thymoquinone content, oxidative stability, and antioxidant properties of cold-pressed black cumin seed oils. *LWT - Food Science and Technology*, 43(9), 1409-1413. doi:10.1016/j.lwt.2010.04.009
- Mofleh, I. A., Alhaider, A., Mossa, J., Al-Sohaibani, M., Al-Yahya, M., Rafatullah, S., & Shaik, S. (2008). Gastroprotective effect of an aqueous suspension of black cumin *Nigella sativa* on necrotizing agents-induced gastric injury in experimental animals. *Saudi Journal of Gastroenterology Saudi J Gastroenterol*, 14(3), 128. doi:10.4103/1319-3767.41731
- Pawar, R., Patil, U., Gadekar, R., Singour, P., & Chaurasiya, P. (2010). A potential of some medicinal plants as antiulcer agents. *Pharmacognosy Reviews Phcog Rev*, 4(8), 136. doi:10.4103/0973-7847.70906
- Srinivas T.L, Lakshmi S.M, Shama N, Reddy, G.K, Prasanna K.R. (2013). Medicinal Plants as Anti-Ulcer Agents. *Journal of Pharmacognosy and Phytochemistry*. 2 (4): 91-97
- Subramanian S, Satishkumar D, Aruselvan, Senthil kumar GP, Mahadevarao US (2007). Evaluation of Anti-ulcerogenic potential of Aloe vera leaf gel extract studied in experimental rats. *J. Pharmacol. Toxicol.*, 2(1): 85-97.
- Vimala, G., & Shoba, F. G. (2014). A Review on Antiulcer Activity of Few Indian Medicinal Plants. *International Journal of Microbiology*, 2014, 1-14. doi:10.1155/2014/519590