

The Reliability of Videomicroscopic Compared with Skin Scraping Microscopic Examination in Detection of *Sarcoptes Scabiei*

Merlina Juhendy^{1*}, Yulia Farida Yahya¹, Inda Astri Aryani¹, Legiran²

¹Department of Dermatology and Venereology Faculty of Medicine Sriwijaya University/Dr. Moh. Hoesin General Hospital Palembang, Jendral Sudirman Street Km 3.5, Palembang, South of Sumatera, Indonesia

²Department of Anatomy, Faculty of Medicine Sriwijaya University, Dr. Mohammad Ali Street, Palembang, South of Sumatera, Indonesia

Keyword: scabies, *Sarcoptes scabiei*, microscopic, videomicroscope, reliability

Abstract: Scabies is a contagious skin disease due to infestation of *Sarcoptes scabiei* var. *hominis* (*S. scabiei*). Skin scraping microscopic examination is a standard diagnostic procedure, which is still considered as a “gold standard” to confirm the diagnosis. This method is invasive, time consuming with risks associated procedure. Videomicroscope, a non medical digital microscope that can be used to visualize burrow, mites and eggs of *S. scabiei*. The reliability of videomicroscope to detect mites has not been studied. This study is to determine reliability of videomicroscope and skin scraping microscopic examination in detection of *S. scabiei* in presumptive scabies patients. This is a diagnostic test study which was conducted from August to October 2017 at the Orphanage Subulussalam, Orphanage Al-Wiam, *Lembaga Wanita Peduli Sriwijaya, Lembaga Pendidikan dan Sosial Pemuda Bersatu* and *Lembaga Perlindungan Anak Kota Palembang*. A total of 139 presumptive scabies patients who met the inclusion and exclusion criteria were recruited by consecutive sampling. All subjects were examined with blinded method using videomicroscope and skin scraping microscopic examination by researcher and other examiner. *S. scabiei* mites that was detected by skin scraping examination was 49,6% of all subject study. Sensitivity and specificity of videomicroscope examination compared to skin scraping microscopic examination were 89,8% and 82,9%. (PPV 83,8%; NPV 89,2%; positive likelihood ratio 4,57; negative likelihood ratio 0,16; accuracy 86,3%, AUC 0,864). Videomicroscope showed high sensitivity and specificity, which was useful as a rapid alternative diagnostic method to detect *S. scabiei* in high risk population.

1 INTRODUCTION

Scabies is a skin disease due to infestation of *Sarcoptes scabiei* var. *hominis* (*S. scabiei*) as an obligate parasite on the epidermis (Burkhart and Burkhart, 2012). Clinical manifestation of scabies are skin lesions accompanied by pruritus due to allergic reaction or inflammation to the mites and their products, it can resemble to other diseases (Chosidow, 2006). This can cause a misdiagnosis, an inadequate therapy, also can increase the risk of bacterial infection and morbidity, so further examination is needed to confirm the diagnosis (Heukelbach et al., 2013; Micali et al., 2016).

Standard diagnostic procedures to confirm the diagnosis is microscopic examination of skin scraping (SS). This examination method is invasive and some literatures considered it as a “gold

standard” for definite diagnosis by the visualization of the mites, eggs or scybala (Leung and Miller, 2011; PERDOSKI, 2017). Few disadvantages of microscopic examination by skin scraping are a pain that cause discomfort especially in younger patients, a risk of bleeding, a secondary bacterial infection, a necessary to be repeated on a few locations and a time consuming (Micali et al., 2016; Anderson and Strowd, 2017).

Recently there is a new non invasive technique such as a videomicroscope (VM), a digital microscope with magnification until 1000x allowing direct visualization burrow, mites and eggs of *S. scabiei* for a definite diagnosis of scabies, faster and more practical in its use, with affordable price (Lacarrubba et al., 2015; Micali et al., 2015).

The objective of this study is to determine the reliability of VM compared with SS microscopic

examination to detect *S. scabiei* in presumptive scabies patients.

2 METHODS

This is a diagnostic test study with cross sectional design from August to October 2017 at the Orphanage Subulussalam, Orphanage Al-Wiam, *Lembaga Wanita Peduli Sriwijaya*, *Lembaga Pendidikan dan Sosial Pemuda Bersatu* and *Lembaga Perlindungan Anak Kota Palembang* in Palembang. The study was approved by the ethics committee. A total of 139 patients with skin disease who met the inclusion and exclusion criteria were recruited by consecutive sampling. The inclusion criteria was presumptive scabies patients, who agreed to participate in the study. Exclusion criteria

was patient who had been treated with scabies therapy within 4 weeks prior to study. Demographic data were collected and all subjects were blinded examined using VM and SS microscopic examination by researcher and other examiner.

3 RESULTS

In this study majority of the subjects were male with ratio of male is 52,5% and female is 47,5%. The subjects of this study were divided into few groups based on age which they were infants (3,6%), children (31,7%), adolescents (61,2%) and adults (3,6%). The education level of the subjects was divided into 4 groups: non-school (12,2%), primary school (28,8%), junior high (37,2%) and senior high school (21,6%).

Table 1. Demographic and characteristic of the lesions

Characteristic	Total (n)	Percentage (%)
Gender		
Male	73	52,5
Female	66	47,5
Age		
Infants	5	3,6
Children	44	31,7
Adolescents	85	61,2
Adult	5	3,6
Education		
Non school	17	12,2
Primary school	40	28,8
Junior high school	52	37,4
Senior high school	30	21,6
Sharing clothes/towels together	74	53,2
Sharing bed with others	101	72,7
Number of people in a bedroom		
1 person	11	7,9
2-3 persons	50	36
4-5 persons	35	25,2
>5 persons	43	30,9
Location of the lesions		
<i>Interdigitalis manus</i>	125	89,9
<i>Radiocarpalisjoint</i>	102	73,4
<i>Dorsum manus</i>	106	76,3
<i>Antecubiti</i>	9	6,5
<i>Flexor extremitas superior</i>	44	31,7
<i>Abdominalis(umbilicus/periumbilicus)</i>	28	20,1
<i>Inguinalis/genitalia</i>	44	31,7
<i>Glutealis</i>	29	20,9
Location where <i>S. scabiei</i> mites detected		
<i>Dorsum manus</i>	5	7,2
<i>Flexor extremitas superior</i>	5	7,2
<i>Glutealis</i>	2	2,9
<i>Inguinalis/genitalia</i>	5	7,2
<i>Interdigitalis manus</i>	35	50,7
<i>Abdominalis</i>	4	5,7
<i>Radiocarpalis joint</i>	13	18,8

Study subjects 53,2% were sharing clothes/towels together with friends. A total of 36% of the study subjects had 2-3 friends in one room and 72,7% of the study subjects occupied the bed with others. The most common lesions were erythematous papules (99,3%) and most lesions were found on the interdigital region (89,9%).

The total of *S. scabiei* detected using microscopic skin scraping examination in this study was 49,6% of all study subjects, with the most commonly location found is on interdigital manus (28,8%). Kappa value of VM examination between two examiners was 0,82. The analysis of VM examination results compared to SS microscopic examination as a "gold standard" was obtained by Sn, Sp VM value were 89,8% and 82,8% (PPV 83,8%, NPV 89,2%, PLR 5,25, NLR 0,12, 86,3% of accuracy and AUC 0,864).

4 DISCUSSION

Scabies is a parasitic infestation of the skin caused by *S. scabiei*, highly contagious through both direct and indirect contact and affect all ages, races and socioeconomic levels (Burkhart and Burkhart, 2012). Scabies is a global public health problem, which is often overlooked, according to the WHO including one "neglected tropical diseases". In poor communities scabies potentially causing outbreaks associated with its transmission method, overcrowding, poor sanitation and low knowledge (Heukelbach and Feldmeier, 2006). Non-specific clinical features may lead to misdiagnosis and may be a source of active transmission (Hewitt et al.,

2015). Late treatment and inadequate therapy, increasing the risk of bacterial infections and morbidity, so a diagnostic tool with high sensitivity is needed (Micali et al., 2016). According to the Japanese dermatological guidelines for diagnosis and treatment 2017 the sensitivity of SS microscopic examination varies between 10-70% (Ishii et al., 2017). Dupuy et al. found that diagnosis of scabies only on clinical grounds, because of the difficulty of detecting *S. scabiei* mites, causing 27% of untreated scabies patients, thus increasing the risk for an outbreak of scabies. Videomicroscope is a non medical digital microscope, commonly used for botanical, entomology and microelectronics, that can be used to make a definite diagnosis of scabies (Micali et al., 2016; Anderson and Strowd, 2017). The analysis of VM diagnostic test result compared to SS microscopic examination as 'gold standard' obtained by Sn and Sp VM were 89.9% and 82.9% (PPV 83,8%; NPV 89,2%; PLR 4,57; NLR 0.16 and 86.3% accuracy, AUC 0.864). In this study of 139 patients (49.6%) presumptive scabies detected mites, *S. scabiei* eggs in 69 patients. According to Micalli, et al study 20 presumptive scabies patients were examined using VM, VD was confirmed by SS microscopic examination, *S. scabiei* mites were detected in 15 patients, during follow-up 5 patients remained negative. In the study, the VM diagnostic test was not performed, and sample size population were small (Lacarrubba et al., 2015; Micali et al., 2015). Burrow is scabies pathognomonic lesion, that often can be difficult to find, especially in the tropical climates, but VM can help to visualize it (Walton and Currie, 2007; Burkhart and Burkhart, 2012).

Table 2. Diagnostic value results of VM compared with SS microscopic examination

No.	Diagnostic test	Value	CI (95%)
1.	Sensitivity	89,9%	87,5-90,5
2.	Specificity	82,9%	81,5-84,3
3.	Accuracy	86,3%	84,9-87,7
4.	Positive likelihood ratio	5,25	5,1-5,3
5.	Negative likelihood ratio	0,13	0,11-0,15
6.	Positive predictive value	83,8%	82,4-85,2
7.	Negative predictive value	89,2%	87,7-90,7
8.	Area under curve	0,864	0,797-0,930

A good accuracy rate of VM (86.3%) also reduces the risk of misdiagnosis so as to prevent outbreaks of scabies especially in densely populated and socioeconomic areas. VM examination is a non invasive method, it can be well tolerated and efficient in terms of time because it only takes ≤10 minutes to direct visualization of *S. scabiei* mites,

eggs. and burrows and may be used for the follow up evaluation after therapy (Lacarrubba et al., 2010). Further study is needed in multicenter with larger sample size and more heterogeneous populations to determine the reliability VM in the detection of *S. scabiei*.

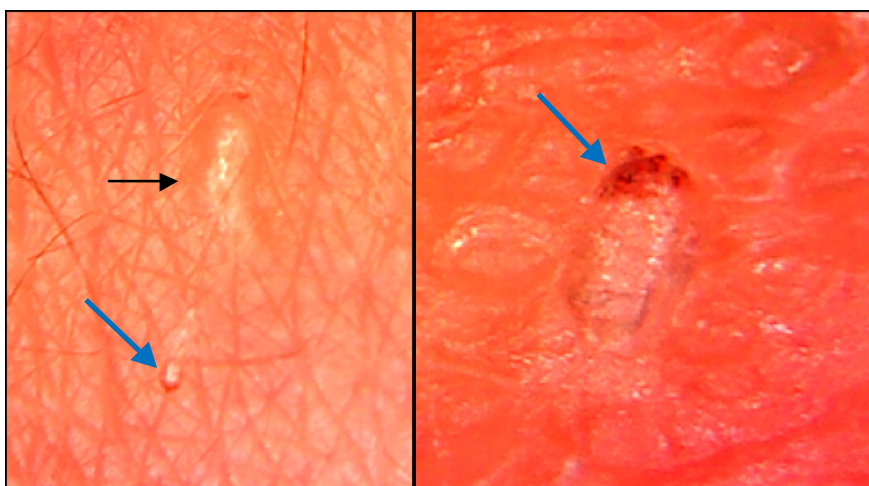


Figure 1. Videomicroscopic examination clearly evident the burrow (black arrow) and *S. scabiei* mite (blue arrow).

5 CONCLUSION

Videomicroscope has diagnostic value with high accuracy and high level of accordance between the examiners. The value of VM examination were: sensitivity 89.9%, specificity 82.9%, PPV 83.8%, 89.2% NPV and 86.3% accuracy, AUC 0.864. Based on this, VM diagnostic values are as good as SS microscopic examination. Videomicroscope can be used as a means of prevention of scabies in areas with inaccessible and densely populated communities.

ACKNOWLEDGEMENT

The authors would like to thank the Department of Dermatology and Venereology, and Faculty of Medicine of Sriwijaya University and all those who assist in the effort of this research.

REFERENCES

- Anderson, K.L., Strowd, L.C., 2017. Epidemiology, Diagnosis, and Treatment of Scabies in a Dermatology Office. *The Journal of the American Board of Family Medicine* 30, 78–84. doi:10.3122/jabfm.2017.01.160190
- Burkhart, C.N., Burkhart, C.G. 2012. Scabies, other mites and pediculosis. In: Goldsmith LA, Katz SI, Gilchrist BA, Paller AS, Leffel DJ, Wolff K. eds. *Fitzpatrick's Dermatology in General Medicine* 8th ed. Mc Graw-Hill, New York Chicago pp. 2569-72
- Chosidow, O., 2006. Scabies. *New England Journal of Medicine* 354, 1718–1727. doi:10.1056/NEJMcp052784
- Dupuy, A., Dehen, L., Bourrat, E., Lacroix, C., Benderdouche, M., Dubertret, L., Morel, P., Feuilhade de Chauvin, M., Petit, A., 2007. Accuracy of standard dermoscopy for diagnosing scabies. *Journal of the American Academy of Dermatology* 56, 53–62. doi:10.1016/j.jaad.2006.07.025
- Heukelbach, J., Feldmeier, H., 2006. Scabies. *Lancet*. doi:10.1016/S0140-6736(06)68772-2
- Heukelbach, J., Mazigo, H.D., Ugbomoiko, U.S., 2013. Impact of scabies in resource-poor communities. *Current Opinion in Infectious Diseases*. doi:10.1097/QCO.0b013e32835e847b
- Hewitt, K.A., Nalabanda, A., Cassell, J.A., 2015. Scabies outbreaks in residential care homes: Factors associated with late recognition, burden and impact. A mixed methods study in England. *Epidemiology and Infection* 143, 1542–1551. doi:10.1017/S0950268814002143
- Ishii, N., Asai, T., Asahina, A., Ishiko, A., Imamura, H., Kato, T., ... Wada, Y., 2017. Guideline for the diagnosis and treatment of scabies in Japan (third edition): Executive Committee of Guideline for the Diagnosis and Treatment of Scabies. *Journal of Dermatology*,44(9), 991–1014. https://doi.org/10.1111/1346-8138.13896
- Lacarrubba F, Verzi AE, Micali G. 2015. A controlled, dermatologist independently assessed, noninferiority clinical trial of high resolution medically marketed videodermatoscopy versus low cost nonmedical videomicroscopy for the diagnosis of scabies. *Journal of the American Academy of Dermatology*. doi:10.1016/j.jaad.2015.02.510
- Lacarrubba, F., D'Amico, V., Nasca, M.R., Dinotta, F., Micali, G., 2010. Use of dermatoscopy and videodermatoscopy in therapeutic follow-up: A review. *International Journal of Dermatology*. doi:10.1111/j.1365-4632.2010.04581.x

- Leung, V., Miller, M., 2011. Detection of scabies: A systematic review of diagnostic methods. *The Canadian journal of infectious diseases & medical microbiology* 22, 143–146.
- Micali, G., Lacarrubba, F., Verzi, A.E., Chosidow, O., Schwartz, R.A., 2016. Scabies: Advances in Noninvasive Diagnosis. *PLoS Neglected Tropical Diseases*. doi:10.1371/journal.pntd.0004691
- Micali, G., Lacarrubba, F., Verzi, A.E., Nasca, M.R., 2015. Low-cost equipment for diagnosis and management of endemic scabies outbreaks in underserved populations. *Clinical Infectious Diseases*. doi:10.1093/cid/ciu826
- PERDOSKI. 2017. Panduan Layanan Klinis Dokter Spesialis Dermatologi dan Venereologi. Jakarta. pp 80-83
- Walton, S.F., Currie, B.J., 2007. Problems in diagnosing scabies, a global disease in human and animal populations. *Clinical Microbiology Reviews*. doi:10.1128/CMR.00042-06

