

The Comparison of Dentist Drill with Chemical Reconstruction of Skin Scars (CROSS) Trichloroacetic Acid (TCA) on Icepick Acne Scars

Moerbono Mochtar¹, Leonardo Trisnarizki¹, and Indah Julianto¹

¹Department of Dermato - Venereology

Medical faculty of Sebelas Maret University. Dr.Moewardi general Hospital - Surakarta

Keywords: Acne scars, Dentist drill CROSS TCA.

Abstract: Acne scar is the most common complication of acne with high incidence rate. There are 3 types of acne scars i.e. boxscar, icepick and rolling. Icepick scar is the most frequent in upto 60-70% cases. Dentist drill is small high speed drill used to remove decayed teeth in dental caries treatments. The drill can also be used to treat icepick acne scars. Chemical reconstructions of skin scars (CROSS) using Trichloroacetic Acid (TCA) is also an effective treatment for icepick scars. Objective: To compare the effectiveness of dental drill with CROSS TCA for treating icepick scars. The total of 10 patients aged 20-40 year old, Fitzpatrick skin type III-IV, with moderate to severe acne scars more than 3 months were included. Dentist drill was performed on the right cheek, while CROSS TCA was performed on the left cheek. Comparison of the effectiveness were based on clinical improvement by photograph, wound healing time, and patients comfort. The patients were evaluated on days 3, 7, 14 and 30. At the end of the study 6 patients showed excellent clinical improvement, while 4 others showed moderate improvement. Both method were effective for icepick scars treatment. Dentist drill provided faster wound recovery (3 days) than CROSS did (7 days). However CROSS TCA is more practical because no special tools requirement, no anesthesia, and more comfortable for the patients.

1 INTRODUCTION

Acne scars are the most common complication of acne. This scar can be found in 95% of acne patients resulting in psychological effects such as low self-esteem, impaired social interactions, and may influence the successful in searching a job (Hession and Graber, 2015). Acne scars classified into three i.e atrophic, hypertrophic and keloid (Gozali et al., 2015). Atrophic scar is the most frequently found acne scars in about 80-90% case (Fabbrocini et al., 2010). By morphology atrophic scars are divided into boxscar, icepick and rolling (Hession and Graber, 2015). The icepick scars found in 60-70% of cases (Fabbrocini et al., 2010).

Chemical reconstructions of skin scars (CROSS) using high concentrations of Trichloroacetic Acid (TCA) 70-100% is an effective therapy for the management of icepick scars (Agarwal et al., 2015; Khunger et al., 2011). This method is effective and safe on dark skin or Fitzpatrick IV- V skin type (Khunger et al., 2011). The principle of this procedure is to make a new wound with chemical liquid which will increase the volume of the dermis due to the formation of new collagen, glycosaminoglycans and elastin so that the scars flatten (Weber et al., 2011; Ramadan et al., 2011).

Dentist drill, is a small high-speed drill, used by dentists to remove decayed teeth in caries dentist

treatment (Bor gigi, 2017). This tool can also be used in dermatology the treatment of acne icepick scars with the same principle mechanism as CROSS TCA by making a new wound on the scar that will stimulate wound healing with the formation of the new tissue. The purpose of this study is to compare the effectiveness of CROSS TCA with dental drill in clinical improvement of acne icepick scars.

2 CASES

The total of 10 patients aged between 20-40 years with acne scars were recruited in this study. The inclusions criteria were patients with Fitzpatrick 3-4 skin types and acne scars more than 3 months willing to follow the study. Exclusion criteria were patients with active inflammatory acne, history of keloids, history of herpes simplex or herpes zoster in the facial region. All study subjects had normal vital signs. Acne scars in the facial region were visible from 50cm distance and when it was stretched the scar did not disappear. Photograph were taken before and after the procedure to evaluate clinical improvement.

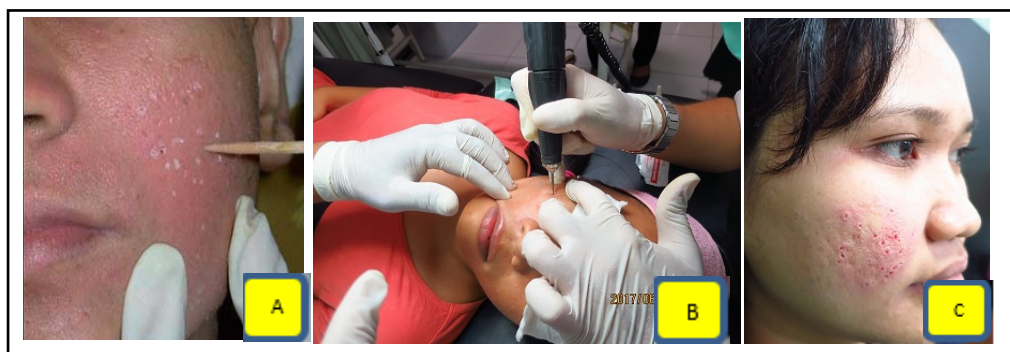


Figure 1. A. Frosting appearance after application of CROSS TCA with wooden tip applicator B. Dentist drill application with perpendicular angle. C. Post dentist drill procedure.

Based on Goodman and Baron criteria, this acne scar belongs to a moderate to severe acne scar (Goodman and Baron, 2006).

First we cleaned the facial region with milk cleanser and cleansing solution, then the *icepick* acne scars were marked with permanent marker. The CROSS TCA were performed without anesthesia on the left cheek by applying TCA 80-100% to the base of the scars by stretching the skin. The TCA applied with wooden applicator (toothpicks) until whitish or “frosting” appeared. The tip of wooden applicator was adjusted to the size of the scars. Dentist drill applied to the right cheek by 1 mm round tip brace drill with 90° angle or perpendicularly until superficial dermis using. This procedure were performed under local lidocain anesthetic (Figure 1).

Topical antibiotic was applied to the skin and the patients were advised not to wash the face for three days after the procedure, avoid direct sunlight during the treatment, and not to manipulate the crust because it healed within 7 days. The patients were evaluated and photographed on days 3, 7, 14 and 30 after the procedure (Table 1).

3 RESULT

The clinical improvement by photograph, the wound healing time, and the patient comfort were compared between the two procedures. Clinical evaluation of scars improvement was based on Goodman and Baron acne scars criteria (Goodman and Baron, 2006). The scars improvement was considered poor if there was no progress on the degree of acne (0-24%), moderate if there was 1 point increase (25-49%), good if there was 2 points increase (50-74%), and excellent if there was 3 points increase (75-100%) (Bhadwaj and Khunger, 2010).

Both procedures gave moderate to excellent clinical improvement in all subject after 30 days (Figure 2). Based on the wound healing time, dentist drill procedure healed faster within 3 days, whereas the CROSS TCA the wound in the form of blackish crusts still appeared more than 7 days (Figure 2). However all of patients felt that the CROSS TCA was more convenient than dentist drill. There was no serious side effect during the treatment in both procedures except mild side effect such as erythema, crust and edema. Post inflammatory hyperpigmentation (HPI) was also not present in all patients.

4 DISCUSSION

The icepick scar is the most common acne scar in 60-70% of cases. This scar has wider surface than the base. It is like V shape. The rolling acne scars are usually larger than 4mm in size with wavy surfaces forming the letter "M". While the boxscar has a round to oval shape and has a firm vertical boundary to form the letter "U" (Fabbrocini et al., 2010).

The pathogenesis of acne scarring is not fully understood. The risk of acne scarring is associated with the severity of acne and the time to start the treatment. Acne scar is thought to be derived from the non inflammatory process into inflammatory acne that results in follicular wall rupture. The rupture will lead to the release of irritating materials such as hair, fat, keratin, bacteria to the dermis so that there is an inflammation in the dermis that will activate the complement with classical and alternative pathways (Maharani and Kusumawardhani, 2016).

There are various modalities of acne scar treatment such as dermabrasion, subcision, chemical peels, punch excision, microneedling, soft tissue augmentation, and laser (Hession and Graber, 2015;




Figure 2. **A.E.** Before dentist drill procedure **B.F** excellent clinical improvement 30 days after dentis drill procedure. **C.G** before CROSS TCA **D.H** Excellent clinical improvement 30 days after CROSS TCA. **I.** 3 days after dentist drill the wound healed faster **J.** Wound 3 days after CROSS TCA.

Table 1. Comparison of CROSS TCA and dentist drill.

	Clinical improvement 30 days after procedure		Wound Healing Time								Patient Comfortness	
	CROSS	Dentist drill	3 DAYS		7 Days		14 Days		30 Days		CROSS	Dentist drill
			CROSS	Dentist drill	CROSS	Dentist Drill	CROSS	Dentist Drill	CROSS	Dentist Drill		
Patient 1	Moderate	Moderate	-	+	+	+	+	+	+	+	+	-
Patient 2	Very good	Very good	-	+	-	+	+	+	+	+	+	-
Patient 3	Moderate	Moderate	-	+	+	+	+	+	+	+	+	-
Patient 4	Very good	Very good	-	+	-	+	+	+	+	+	+	-
Patient 5	Moderate	Moderate	-	+	-	+	+	+	+	+	+	-
Patient 6	Excellent	Excellent	-	+	+	+	+	+	+	+	+	-
Patient 7	Very good	Very good	-	+	-	+	+	+	+	+	+	-
Patient 8	Moderate	Moderate	-	+	+	+	+	+	+	+	+	-
Patient 9	Excellent	Excellent	-	+	-	+	+	+	+	+	+	-
Patient 10	Excellent	Excellent	-	+	+	+	+	+	+	+	+	-

Zaleski-Larsen et al., 2016; Simmons et al., 2014) The other treatment option is chemical reconstructions of skin scars (CROSS) using Trichloroacetic Acid (TCA) high concentration 70-100% which effective on icepick scars and it is safe for skin colour (Khunger et al., 2011; Bhardwaj and Khunger, 2010). This procedure can also be used in rolling scars and varicella scars (Ramadan et al., 2011; Sardana et al., 2014). Kim et al reported the use of 100% CROSS TCA on icepick scars with similar results to the erbium laser therapy (Agarwal et al., 2013).

Dentist drill in dermatology can also be used for the management of acne icepick scar. The mechanism of this drill is almost similar to CROSS TCA by making a new wound around the scars so that it will stimulate wound healing with the formation of a new collagen tissue. Even various therapeutic modalities are available with varying effectiveness, but some of the outcome is still less than optimal (Sardana et al., 2014). No single therapy is universally effective in all types of scars (Gozali et al., 2015). Therefore some clinician use combination therapy to improve the effectiveness (Agarwal., 2013).

In the 10 patients we studied, the acne scars was clearly visible in 50 centimeters and when they were stretched several acne scars flattened but some did not. Such conditions were categorized in moderate-severe acne scars (Goodman and Baron, 2006). Six study subject who had more predominant icepick acne scars showed significant clinical improvement. Four patients experienced less significant clinical improvement. The possible causes of this condition was mixed type of the acne scars, while only the acne scars being treated was icepick scars, and not others (rolling and box scar). Therefore the clinical improvement by photopgraph appeared less significant. However if we looked closer, the icepick scars looked flattened by both procedure. The other reason is the the size of icepick scars is less than 2mm, smaller than box scars and rolling scars, so that despite there were flattened scars, the clinical improvements is not significant. Another possible cause is that the procedures for acre scars should be performed in multiple replications depending on the patient's clinical response, while in all the above patients we only treat the patient once.

The dental drill provided faster recovery than CROSS TCA. On the 3rd day the wound has already closed. Whereas in CROSS TCA group multiple blackish crusts (Table 1) still persisted. In the 7th day the entire crust disappeared in dentis drill group but in CROSS TCA some were still observed.

The patients complained of burning sensation for 5 minutes with CROSS TCA. This occurred because CROSS TCA was performed without anesthesia, whereas a dental drill was given a local anesthetic injection. However, injection of pehacaine also

caused pain at the time of injection, especially if the location of the scars scattered. It was done several times in some areas caused greater pain. Another complaint of patients was the sound of drill which made the patient feel uncomfot. Based on patient comfort, CROSS TCA is preferred compared to the dentist drill.

5 CONCLUSION

The CROSS TCA and dental drill were effective in treating icepick scars acne. Each of these procedure has its own advantages and disadvantages. The use of a dental drill has a faster wound healing time. However CROSS TCA is more practical because no special tools requirement, no anesthesia, and it gives more comfortable feeling.

REFERENCES

- Agarwal, N., Mittal, A., Kuldeep, C., Gupta, LK., Khare, AK., Mehta, S., 2013. Chemical Reconstruction of Skin Scars Therapy Using 100% Trichloroacetic Acid in the Treatment of Atrophic Facial Post Varicella Scars: A Pilot Study. *Journal of Cutaneous and Aesthetic Surgery - Jul-Sep*, 6(3), 144-147.
- Agarwal, N., Gupta, LK., Kuldeep, CM., Mittal, A., 2015. Therapeutic Response of 70% Trichloroacetic Acid CROSS in Atrophic Acne Scars. *Dermatologic surgery*, 41, 587-604.
- Bhardwaj, D., Khunger, N., 2010. An Assessment of the Efficacy and Safety of CROSS Technique with 100% TCA in the Management of Ice Pick Acne Scars. *Journal of cutaneous and aesthetic surgery*, 3(2), 93-96.
- Bor gigi, 2017 [8 juli 2017]. Available from: https://id.wikipedia.org/wiki/Bor_gigi.
- Fabbrocini, G., Annunziata, MC., V.D'Arco, DeVita V, G. Lodi, C.Mauriello M, et al. Acne Scars: Pathogenesis, Classification and Treatment. *Dermatology Research and Practice*, 1-13.
- Goodman, GJ., Baron, JA., 2006. Postacne Scarring: A Qualitative Global Scarring Grading System. *Dermatologic surgery*, 32(12), 1458-1466.
- Gozali, MV., Zhou B, Luo, D., 2015. Effective Treatments of Atrophic Acne Scars. *The Journal of clinical and aesthetic dermatology*, 8(5), 33-40.
- Hession, MT., Graber, EM., 2015. Atrophic Acne Scarring A Review of Treatment Options. *The Journal of clinical and aesthetic dermatology*, 8(1), 50-58.
- Khunger, N., Bhardwaj, D., Khunger, M., 2011. Evaluation Of Cross Technique With 100% Tea In The Management Of Ice Pick Acne Scars In Darker Skin Types. *Journal of cosmetic dermatology*, 10, 51-57.

- Maharani, SC., Kusumawardani, A., 2016. Kombinasi Microneedling dan Subsisi Dengan Pemberian Platelet Rich Plasma Secara Split Face Pada Skar Akne.
- Ramadan, SAE-R., El-Komy, MHM., Bassiouny, DA., El-Tobshy, SA., 2011. Subcision Versus 100% Trichloroacetic Acid in the Treatment of Rolling Acne Scars. *Dermatol surgery*. 32:626-633.
- Sardana, K., Manjhi, M., Garg, VK., Sagar, V., 2014. Which Type of Atrophic Acne Scar (Ice-pick, Boxcar, or Rolling) Responds to Nonablative Fractional Laser Therapy? *Dermatologic surgery*, 40, 288-300.
- Simmons, BJ., Griffith, RD., Falto-Aizpurua, LA., Nouri, K., 2014. Use Of Radiofrequency In Cosmetic Dermatology: Focus On Nonablative Treatment Of Acne Scars. *Clinical, cosmetic and investigational dermatology*, 7:335-339.
- Weber, MB., Machado, RB., Hoefel, IR., Manzoni, APD., Geler, ADSB., 2011. Complication of Cross-Technique on Boxcar Acne Scars: Atrophy. *Dermatologic surgery*, 37(95-96).
- Zaleski-Larsen, LA., Fabi, SG., McGraw, T., Taylor, M. , 2016. Acne Scar Treatment: A Multimodality Approach Tailored to Scar Type. *Dermatology surgery*, 42:S139-S49.



SCITEPRESS
SCIENCE AND TECHNOLOGY PUBLICATIONS